

PostScript

CORRECTIONS

doi: 10.1136/emj.2003.13607corr1

In the Emergency casebook titled, Delayed presentation of internal mammary artery rupture after blunt chest trauma: characteristic CT and plain x ray findings (*Emerg Med J* 2005;**22**:664-5), the author affiliations were incorrect. The correct affiliations are as follows:

S P Chung, I S Yoo, S W Kim Department of Emergency Medicine, Chungnam National University Hospital, Daejeon, Republic of Korea

O Y Kwon Department of Anatomy, College of Medicine, Chungnam National University, Daejeon, Republic of Korea

C J Song Department of Radiology, Chungnam University Hospital, Daejeon, Republic of Korea

I B Kim Department of Emergency Medicine, Kwandong University College of Medicine, Myongji Hospital, Kyunggi-do, Republic of Korea

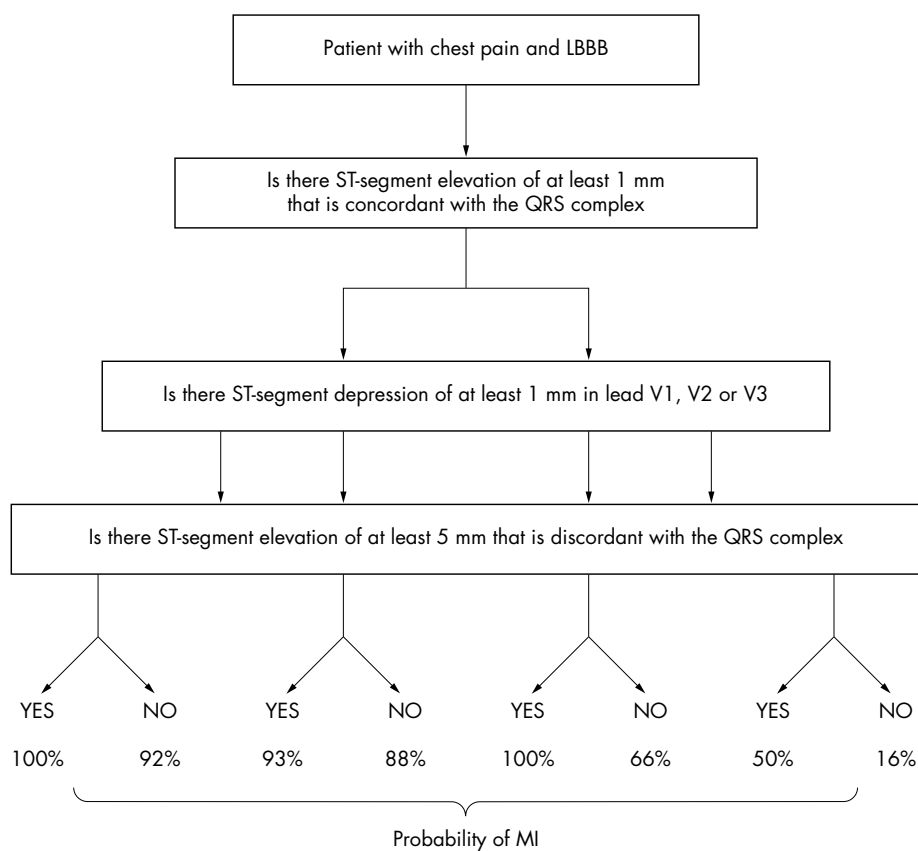
doi: 10.1136/emj.2003.12914corr1

In the letter titled, Difficult adherent nail bed dressings: An escape route (*Emerg Med J* 2005;**22**:312), the lead authors name is

incorrectly cited as M S Ul Hassan. The correct citation is M S U Hassan. The journal apologises for this error.

doi: 10.1136/emj.2003.13987corr1

An error has occurred in figure 3 of the paper titled, Simplifying thrombolysis decisions in patients with left bundle branch block (*Emerg Med J* 2005;**22**:617-20). The third box from the left should read ST depression > 1mm instead of ST elevation > 1mm. Please see correct figure 3 below.



CORRECTIONS

doi: 10.1136/emj.2005.25346corr1

The author affiliations and correspondence details are incorrect for the paper titled, Use of a forensic technique to identify blood contamination of emergency department and ambulance trauma equipment (*Emerg Med J* 2006;**23**:73-5). The correct author affiliations are:

JB Lee, M Levy, Yorkshire Deanery UK

A Walker, Mid-Yorkshire Hospital Trust, UK

Correspondence should be sent to: Miss A Walker, Mid-Yorkshire Hospitals Trust, UK; alison.walker1@midyorks.nhs.uk.

doi: 10.1136/emj.2003.13987corr2

An error occurred in figure 3 of the paper titled, Simplifying thrombolysis decisions in patients with left bundle branch block (*Emerg Med J* 2005;**22**:617-20). The corrections printed in the November issue (*Emerg Med J* 2005;**22**:836) was also incorrect. Please find below the correct figure. The journal apologises for this error.

