



Prospective comparison of ultrasound and CXR for confirmation of central vascular catheter placement

Anthony J Weekes,¹ Stephen M Keller,¹ Bradley Efune,² Sama Ghali,³ Michael Runyon¹

¹Department of Emergency Medicine, Carolinas Medical Center, Charlotte, North Carolina, USA

²Department of Emergency Medicine, Good Shepherd Medical Center, Longview, Texas, USA

³Department of Emergency Medicine, Chandler Medical Center, Lexington, Kentucky, USA

Correspondence to

Dr Anthony J Weekes, Department of Emergency Medicine, Carolinas Medical Center, 1000 Blythe Boulevard, Charlotte, NC 28230, USA; anthony.weekes1@gmail.com

Received 4 May 2015

Revised 23 July 2015

Accepted 17 September 2015

Published Online First

7 October 2015

ABSTRACT

Objective To prospectively compare ultrasound (US) versus CXR for confirmation of central vascular catheter (CVC) placement. Secondary objective was to determine the incidence of pneumothorax (PTX) and compare US with CXR completion times.

Methods Investigators performed the US saline flush echo test, and evaluated each anterior hemithorax for pleural sliding with US after subclavian or internal jugular CVC placement.

Measurements and main results 151 total (135 in the emergency department, 16 in the intensive care unit) patients after CVC placement, mean age 62.1 \pm 15.6 years and 83 (55%) female patients. The rapid atrial swirl sign (RASS) was ultrasound finding of an immediate appearance of turbulence entering the right atrium via superior vena cava after a rapid saline flush of the distal CVC port. RASS was considered 'negative' for CVC malposition. US identified all correct CVC placements. Four suboptimal CVC tip placements were detected by CXR. US identified three of these misplacements (McNemar exact p value >0.99). There were no cases of PTX or abnormal pleural sliding by either CXR or US. Median times for US and CXR completion were 1.1 (IQR 0.7) minutes and 20 (IQR: 30) minutes, respectively, median difference 23.8 (95% CI 19.6 to 29.3) minutes, $p < 0.0001$.

Conclusions PTX and CVC tip malposition were rare after US-guided CVC placement. There was no significant difference between saline flush echo and CXR for the identification of catheter tip malposition. Benefits of US assessment for complications include reduced radiation exposure and time delays associated with CXR.

INTRODUCTION

Central vascular catheters (CVCs) are widely used in the management and resuscitation of critically ill patients in emergency departments (EDs) and intensive care units (ICUs). Common indications for CVC placement include the need for vasopressor agents or multiple simultaneous medications, central venous monitoring or inadequate peripheral venous access. Mechanical complications of CVC insertions are well known, and can be minimised with ultrasound (US) guidance. However, successful venous catheterisation does not guarantee optimal positioning of the distal CVC tip, and even with US guidance, there may be concerns for an iatrogenic pneumothorax (PTX). Physicians and nurses may be reluctant to use the CVC until correct CVC placement has been confirmed, thus, introducing delays in the care of critically ill patients. A post-CVC placement CXR is routinely obtained to

Key messages

What is already known on this subject?

Numerous studies have shown that the safety and success of central vascular catheter (CVC) placement are improved with ultrasound (US) guidance. CXRs are routinely performed after CVC placement to look for pneumothorax and positioning of the CVC tip. Few studies have compared US with CXR for the confirmation of CVC placement and identification of complications.

What might this study add?

Our study suggests that catheter malposition and pneumothorax are uncommon. US can rapidly confirm CVC position, thereby reducing delays in using CVC and CXR radiation exposure.

evaluate for PTX and determine if the distal CVC catheter tip is positioned proximal to the right atrium of the heart as intended.

CXR use involves exposure to ionising radiation, and requires an available X-ray technician for image acquisition and image processing. This may result in a delay in care while the clinician waits to verify CVC positioning by CXR before the catheter can be used. Furthermore, the bedside CXR is usually performed on supine patients, an approach that can lower its accuracy in detecting PTX.^{1–11} US involves no radiation exposure, and is immediately available to the treating physician for interpretation. US has been shown to be more accurate than CXR for PTX detection in supine patients.^{1 2 8}

Several research studies have used varied US approaches to detect CVC positioning after subclavian (SC) and internal jugular (IJ) CVC placement and PTX. Some studies focused on the direct US identification of the distal CVC tip near to or within the right atrium or the aberrant placement within an IJ or SC vein.^{12–14} Others indirectly identified venous insertion and distal CVC tip location near the right atrium by the rapid entry of turbulent flow into the right atrium after agitated saline or rapid saline flush of the distal CVC port. Delayed and weak turbulence suggests aberrant venous placement whereas complete lack of turbulence is concerning for arterial CVC placement.^{15–21} Based on previous research experience, our study group noted no cases of intracardiac CVC tip positioning, and CVC tips were routinely within the superior vena cava or left innominate vein regions on CXR.



CrossMark

To cite: Weekes AJ, Keller SM, Efune B, et al. *Emerg Med J* 2016;**33**: 176–180.



These locations do not allow for direct visualisation of the CVC tip with basic cardiac US views. We, therefore, used a surrogate marker of CVC tip position (rapid entry of turbulence into the right atrium after CVC flush).¹⁹ The inter-rater agreement for interpreting the saline flush echo was good.¹⁹

The primary aim of the study was to compare US with bedside CXR (reference standard) for the confirmation of CVC placement. The secondary aims were to compare PTX detection by both modalities and US and CXR completion times.

METHODS

This was a prospective observational diagnostic cohort study. The hospital institutional review board approved the study protocol and granted waivers of informed consent and authorisation.

Study design and setting

We enrolled patients between November 2013 and March 2015 in an academic ED.

Selection of participants

Inclusion criteria: age ≥ 18 years and CVC was inserted via the IJ or SC approach. We excluded patients with an indwelling intravascular device, known superior vena cava syndrome, inadequate US windows, high acuity traumatic conditions and investigator awareness of post-CVC CXR findings prior to US. We enrolled a convenience sample of patients subject to study investigator availability.

Methods and measurements

All SC and IJ CVC procedures were performed with the Seldinger technique, and were followed by CXR evaluation according to standard medical practice at our institution. The CVCs were either the triple-lumen 16 cm CVC (ARROWgard Blue; Teleflex, Research Triangle Park, North Carolina, USA) or a 20 cm catheter (PreSep; Edwards Lifesciences, Irvine, California, USA). We used a 3–5 MHz phased array transducer for cardiac imaging and a 5–10 MHz linear transducer for pleural imaging on a Philips Sparq US machine (Philips Healthcare, Andover, Massachusetts, USA).

CVC placements received saline flush echo and pleural sliding US assessments directly by, or under direct supervision of, a study investigator. The US did not interfere with the ongoing medical management of any patient. Treating physicians continued the routine practice of ordering a CXR after CVC placement. If an X-ray technician was present and ready to perform the CXR during the US, the study investigator yielded and allowed CXR to proceed before completing the US examination. Treating physicians were informed of any concerning US findings noted by the investigators.

US intervention

Saline flush echo protocol

After CVC placement, investigators obtained an echocardiographic four-chamber apical or subcostal window. An assistant (physician or nurse) flushed the distal CVC port with 10 mL of 0.9% saline. The rapid atrial swirl (RAS) was defined as the US appearance of turbulence entering the right atrium from the superior vena cava immediately (subjectively estimated within 2 s) after the saline flush of the CVC distal port and migrating towards the right ventricle. The rapid saline flush and the start of echo video acquisition were simultaneous. This technique was used in previous studies.^{18 19} Intracardiac CVC tip positioning

was considered if the turbulence first appeared in the right ventricle or migrated into the right atrium via the tricuspid valve.

Pleural sliding protocol

We used a linear transducer to evaluate the right and left hemithorax for pleural sliding after the CVC placement. All patients remained in the supine position for the placement of CVC and US. The presence of pleural sliding along the mid clavicular line of the right hemithorax and along the anterior axillary line of left hemithorax was considered index test negative for PTX. The absence of definite pleural sliding on the side of CVC placement was considered positive for PTX.

Outcomes

The CXR was the reference standard. Board-certified radiologists reviewed each CXR, and provided a standard report on the CVC tip location and presence or absence of PTX. Radiologists were unaware of US findings, and at the time of US performance, investigators were blind to any CXR images and report. We used previously published guidelines to designate the target zone for optimal CVC tip positioning on CXR.^{22–24} The optimal distal CVC tip position for left-sided insertions was either the left innominate vein or distal SVC, and the distal superior vena cava (SVC) for right-sided CVC insertions. Intracardiac CVC tip positioning was considered incorrect or misplacement.

Physicians inserting CVC reported on any difficulty with placement, including multiple needle insertion attempts, difficulty passing the guide wire and difficulty flushing any of the CVC ports. The timing of the post-CVC placement CXR was done according to routine practice and influenced by the availability of the radiology technicians and clinical urgency. Study investigators performing US contemporaneously interpreted the findings.

US performance was timed. Time to CXR completion was defined as the image acquisition time documented in our hospital's picture archiving and communication system (Stentor; Philips Healthcare, Andover, Massachusetts, USA).

ANALYSIS

The sample size was calculated by the method described by Buderer.²⁵ Assuming a 98% sensitivity of US to detect catheter tip malposition, a CI of 10% and a 5% prevalence of catheter tip malposition,²⁶ we calculated a sample size of 151 patients. The data are summarised as counts and percentages, means and SDs, or medians and IQRs, depending on the data type and distribution. Ninety-five per cent CIs are presented when appropriate. The classification of catheter tip malposition by CXR and US were compared using the McNemar exact test. Time to US and CXR completion were compared with the Wilcoxon signed-rank test as these data were not normally distributed. Two-sided *p* values < 0.05 were considered statistically significant. All analyses were conducted with the StatsDirect software V3.0.133 (StatsDirect, Cheshire, UK).

RESULTS

Study characteristics

We enrolled 156 patients, mean age 62.1 ± 15.6 years and 83 (55%) female patients. Four patients were excluded because of poor cardiac US images, and one was emergently taken to ICU before US could be performed, and we did not record further data on these patients. Forty-two (27.8%) patients were mechanically ventilated during CVC placement. Emergency physicians performed CVC placements. Physicians at a 3-year emergency medicine training programme did the majority of

CVC placements. Emergency medicine board-certified physicians placed 29 CVCs. The majority of CVC placements, 135 out of 151 (89.4%), occurred in the ED and 16 out of 151 (10.5%) in the ICU. Clinical characteristics of patients and details of the CVC procedures are shown in [table 1](#).

Main results

Four suboptimal CVC tip placements were detected by CXR. US identified three of these misplacements. The corresponding McNemar exact *p* value was >0.99 , signifying no difference between US and CXR for identifying CVC malposition (see [table 2](#)).

Of the four malpositioned CVC tips detected by CXR, three were US-guided right IJ CVC insertions, and one was inserted into the right SC vein without US guidance. None of the CVC malpositions were arterial insertions. Saline flush echo test indirectly detected three of the four CVC malpositions. There was one false negative: one right IJ CVC placement had its distal tip in the right IJ (by CXR), but there was turbulence that quickly entered the right atrium during the saline flush echo test. There were no CVC-related clinical complications in this patient, and the CVC was later changed in the ICU. There were no PTX cases by CXR or US.

The median time between CVC placement and CXR completion was 20 (IQR 30) minutes.

The median time for performance and interpretation of both US assessments was 1.1 (IQR 0.7) minutes. The median difference for CXR versus US completion by the Wilcoxon signed-rank test was 23.8 (95% CI 19.6 to 29.3) minutes, $p<0.0001$ ([figure 1](#)).

Clinician-reported challenges with CVC placement occurred in 5 out of 151 (3.3%) CVC placements. All challenges involved 3–5 needle insertion attempts, but none involved difficulties with the passage of the guidewire. None of these challenging cases resulted in CVC malposition.

Table 1 Characteristics of subjects, and IJ and SC CVC placements

Clinical characteristics	
Age, mean (SD) year*	62.1 (15.6)
Female	83 (55%)
Systolic BP (mm Hg) median (IQR)	104 (38)
Diastolic BP (mm Hg) median (IQR)	59 (28)
HR (bpm) mean (SD)	97.2 (20.4)
Mechanically ventilated (%) during testing	80/151 (51%)
Type of CVC	
Triple lumen	107 (70.9%)
PreSep	44 (29.1%)
CVC insertion site	
Right IJ: 105 (69.5%)	
Left IJ: 32 (21.1%)	
Right SC: 8 (5.3%)	
Left SC: 6 (4.0%)	
Depth of CVC median (IQR) (cm)	
Overall	15 (1)
Triple lumen	15 (0)
PreSep	19 (4)
Ultrasound guidance for CVC placement	140/151 (92.7%)

*All mean values are given with SD; median values with IQR.

†Triple Lumen if 'hubbed' =16 cm mark; PreSep if 'hubbed'=21 cm mark. CVC, central vascular catheter; IJ, internal jugular vein; SC, subclavian.

Table 2 CXR for central vascular catheter tip location

Saline flush echo test	Correct	Malposition	Total
Correct	147	1	148
Malposition	0	3	3
Total	147	4	151

DISCUSSION

The use and reliance on post-CVC placement CXR entails additional ionising radiation exposure, cost, personnel and resources with potential time delays to CVC use or clinical management when compared with bedside US. We showed that this US evaluation, performed after CVC placement, was highly specific for CVC malposition and for PTX detection. The incidences of both CVC malposition and PTX were rare in our cohort, suggesting that this post-CVC placement US evaluation may be an important risk-stratification tool for prioritising and limiting CXR use after the CVC placement.

The saline flush echo component of the post-CVC US assessment helps in confirming that there is venous placement of the CVC. In a study by Horowitz *et al*, arterial placement of femoral catheters was associated with the absence of turbulence within the right atrium after saline flush. However, femoral venous catheterisation was associated with the rapid onset of turbulence within the right atrium after saline flush.²⁰ In addition, the rapidity of onset of turbulence within the right atrium correlates with the proximity of the distal CVC tip to the right atrium. Previous studies have shown that delays or absence of turbulence were associated with aberrant CVC tip positioning.^{16 18 19} Although other studies use 2 s as the cut-off for rapid appearance of turbulence with the saline echo technique, we have noticed that optimally positioned CVC displayed turbulence within 1.1 s of the rapid saline flush.¹⁹

In related studies, the goal was direct US visualisation of the CVC catheter. The approach looked at the junction of the right atrium and the distal superior vena cava for direct visualisation of the CVC tip. CVC distal tips detected in the right heart were considered too deep and defined as 'intracardiac' malpositioning. The US also looked at bilateral IJ and SC veins to detect aberrant 'intravascular' CVC positioning.^{12 13} The definition of correct versus incorrect CVC tip positioning, however, differed

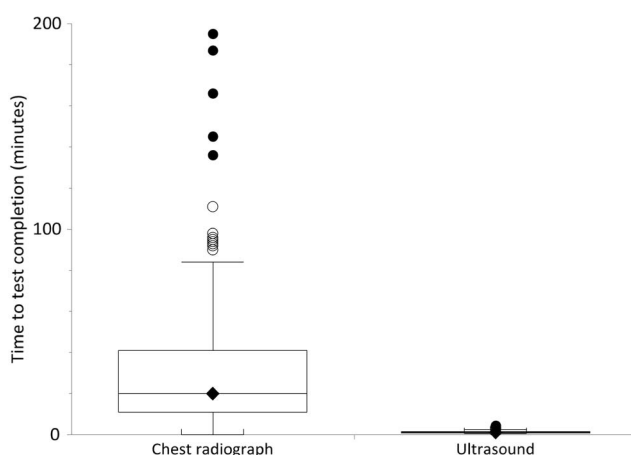


Figure 1 Box and whisker plot comparing the time to test completion for chest radiograph versus the ultrasound assessment. The scale of this figure excludes six outliers who had their chest radiograph completed between 245 and 776 min.

slightly in various reports. Zanobetti *et al* reported that 98 of the 201 CVC evaluated were detected either in the right atrium or at the junction of the superior vena cava and the right atrium. These were considered correct placements per the research protocol.¹⁴ In our study, RAS was defined as the entry of turbulence into the right atrium. Although the direct identification of CVC tip is not the primary use of this saline flush echo test (a surrogate test of CVC position), an indirect identification of intracardiac CVC tip location is suggested by initial appearance turbulence within the right ventricle or right atrium.

Our study did not investigate the clinical outcomes associated with the four malpositioned CVCs. One was removed later in the ICU, and the other catheters were used for fluid administration. There were no clinical complications related to CVC malposition in these three cases. In the study of 1619 patients by Pikwer *et al*, there were few clinical complications of the 53 malpositioned catheters.²⁷ In this study, the authors suggested that post-CVC CXR use be reserved for cases where central venous pressure monitoring was the primary indication for placement, aspiration of venous blood was not possible, mechanical complications were difficult to exclude and vascular injury was possible especially with high pressure and flow infusions or the fluid infused was caustic to the veins.

PTX detection

We compared US with portable CXR for PTX detection in patients in the supine position. Although we did not calculate test characteristics of US for PTX because there were no cases of PTX in our cohort, multiple studies have demonstrated that US is indeed highly sensitive for PTX. In fact, portable CXR has a significantly lower sensitivity than thoracic US,^{1–8} even in immediate postprocedural evaluations.^{9–11} None of our patients developed subsequent PTX during the hospital course. Our findings support Agency for Healthcare Research and Quality (AHRQ) assertions that US-guided CVC placement is an important patient safety practice leading to a reduced rate of iatrogenic PTX. Although we cannot comment on the performance of US identifying PTX in our cohort, it has been well established that US has better diagnostic accuracy for PTX than CXR.

Time to CXR completion

In our study, US completion time was defined as the time interval between starting the US (transducer placed on the chest) to the end of the last recorded images. We defined CXR completion time as the interval between electronic order entry for CXR and portable CXR completion. These variables were well defined by electronic audit. We did not include the other defined time-points that influence treating physicians' awareness of CVC status such as the time the treating physician viewed the CXR, time to completion of the radiologist's report or time to awareness of the radiologist's interpretation. This design biases our findings towards the earliest possible CXR interpretation, though in practice, the time to confirmation of CVC placement and evaluation for PTX were likely to be significantly longer. Other research studies have used CXR interpretation by radiology services as the endpoint.^{13–16 18} We report on the time to US completion because there was immediate availability of US (the majority of CVC insertions were performed with US guidance), and the same physicians acquiring the US images also immediately interpreted the findings. A recent study involving the saline flush test and pleural sliding assessment after CVC placement noted that US confirmation of CVC placement was 37 min earlier than CXR.²¹

LIMITATIONS

Our study has several limitations. Direct visualisation of the CVC tip by US is only feasible if the tip is at the SVC/right atrial junction. US cannot directly detect aberrant CVC tips in an SC or IJ. The majority of correct CVC placements are within the SVC or the left innominate vein, and thus, are not directly visualised by transthoracic US. Rather, the saline flush echo technique is a surrogate test of CVC placement, and infers SVC or innominate venous positioning of the CVC tip when turbulence rapidly enters the right atrium immediately after saline flush of the distal CVC port. In the study by Vezzani *et al*, the US survey included direct IJ and SC views, and direct views of the heart looking for CVC tip, followed by contrast-enhanced views of the heart and pleural sliding assessments. This more comprehensive survey, however, took an average of 10 min.¹⁸

The diagnostic accuracy of US for locating CVC placement can be improved by including direct IJ and SV views to the saline flush echo technique. A modified US technique using saline flush echo with the option of direct IJ and SC views reserved for dubious cases of CVC placement.

It is possible that our research study was underpowered. We estimated 5% prevalence of CVC malposition based on the previous study by Ruesch *et al*²⁶; however, only 2.6% of our CVC cohort were malpositioned. In a report by Pikwer *et al*,²⁷ the incidence of CVC malpositioning, defined as intraventricular or extrathoracic, was 3.3%.

We did not have any cases of PTX, and therefore, did not calculate the test characteristics of US to detect PTX in our cohort. There were no false-positive PTX by US. Previous studies of internal jugular and SC CVC placement have shown a low rate of PTX.²⁶

Our research setting may lead to results that are not generalisable. The existence of a well-established emergency US programme may have impacted our study results. The availability and timeliness of CXR in our academic ED at a level-1 trauma centre may differ significantly from the community ED or inpatient settings. In our centre, CVC use took place immediately after CVC placement as venous placement was usually highly successful after US-guided CVC insertion. As such, we did not report on the actual time between CVC placement and CVC use. The CXR was performed for routine practice, and the impetus for the study at our institution was to determine the potential for US to reduce delays and resources associated with ubiquitous CXR use. In the ED, vascular access is usually the primary indication for venous CVC placement. In the critical-care setting, CVC placement for central venous monitoring and blood sampling may have higher priority for CVC tip location in the superior vena cava. At another institution, the benefits of rapid US confirmation of CVC placement may be more pronounced if delays in critical care were reduced.

Prospective studies involving the use of this US protocol at multiple centres will help assess the generalisability of the approach, its cost-effectiveness and its accuracy in determining CVC placement.

CONCLUSIONS

In our study, US performed similarly to CXR for the detection of malpositioned SC and IJ CVCs. Confirmation of adequate position by US was completed in a significantly shorter time to CXR and without the use of ionising radiation. Our results suggest that lack of confirmation of adequate CVC placement by the saline flush echo test should prompt further evaluation by CXR. We saw no cases of PTX in our patients with CVC placement performed by ED staff.

Contributors AJW and SMK conceived the study and designed the trial. AJW and BE supervised the conduct of the trial and data collection. AJW, SMK, BE and SG recruited patients. AJW and BE managed the data, including quality control. MR provided statistical advice on study design and analysed the data. AJW drafted the manuscript, and all authors contributed substantially to its revision. AJW takes responsibility for the paper as a whole.

Competing interests None declared.

Ethics approval Institutional review board.

Provenance and peer review Not commissioned; externally peer reviewed.

REFERENCES

- Abbasi S, Farsi D, Hafezimoghadam P, *et al.* Accuracy of emergency physician-performed ultrasound in detecting traumatic pneumothorax after a 2-h training course. *Eur J Emerg Med* 2013;20:173–7.
- Alrajab S, Youssef AM, Akkus NI, *et al.* Pleural ultrasonography versus chest radiography for the diagnosis of pneumothorax: review of the literature and meta-analysis. *Crit Care*. 2013;17:R208.
- Dente CJ, Ustin J, Feliciano DV, *et al.* The accuracy of thoracic ultrasound for detection of pneumothorax is not sustained over time: a preliminary study. *J Trauma* 2007;62:1384–9.
- Ding W, Shen Y, Yang J, *et al.* Diagnosis of pneumothorax by radiography and ultrasonography: a meta-analysis. *Chest* 2011;140:859–66.
- Ianniello S, Di Giacomo V, Sessa B, *et al.* First-line sonographic diagnosis of pneumothorax in major trauma: accuracy of e-FAST and comparison with multidetector computed tomography. *Radiol Med* 2014;119:674–80.
- Jalli R, Sefidbakht S, Jafari SH. Value of ultrasound in diagnosis of pneumothorax: a prospective study. *Emerg Radiol* 2013;20:131–4.
- Kumar S, Agarwal R, Aggarwal AN, *et al.* Role of ultrasonography in the diagnosis and management of pneumothorax following transbronchial lung biopsy. *J Bronchol Interv Pulmonol* 2015;22:14–19.
- Zhang M, Liu ZH, Yang JX, *et al.* Rapid detection of pneumothorax by ultrasonography in patients with multiple trauma. *Crit Care*. 2006;10:R112.
- Chung MJ, Goo JM, Im JG, *et al.* Value of high-resolution ultrasound in detecting a pneumothorax. *Eur Radiol* 2005;15:930–5.
- Sartori S, Tombesi P, Trevisani L, *et al.* Accuracy of transthoracic sonography in detection of pneumothorax after sonographically guided lung biopsy: prospective comparison with chest radiography. *AJR Am J Roentgenol* 2007;188:37–41.
- Wilkerson RG, Stone MB. Sensitivity of bedside ultrasound and supine anteroposterior chest radiographs for the identification of pneumothorax after blunt trauma. *Acad Emerg Med* 2010;17:11–17.
- Matsushima K, Frankel HL. Bedside ultrasound can safely eliminate the need for chest radiographs after central venous catheter placement: CVC sono in the surgical ICU (SICU). *J Surg Res* 2010;163:155–61.
- Maury E, Guglielminotti J, Alzieu M, *et al.* Ultrasonic examination: an alternative to chest radiography after central venous catheter insertion? *Am J Respir Crit Care Med* 2001;164:403–5.
- Zanobetti M, Coppa A, Bulletti F, *et al.* Verification of correct central venous catheter placement in the emergency department: comparison between ultrasonography and chest radiography. *Intern Emerg Med* 2013;8:173–80.
- Cortellaro F, Mellace L, Paglia S, *et al.* Contrast enhanced ultrasound vs chest x-ray to determine correct central venous catheter position. *Am J Emerg Med* 2014;32:78–81.
- Duran-Gehring PE, Guirgis FW, McKee KC, *et al.* The bubble study: ultrasound confirmation of central venous catheter placement. *Am J Emerg Med* 2015;33:315–19.
- Lanza C, Russo M, Fabrizio G. Central venous cannulation: are routine chest radiographs necessary after B-mode and colour Doppler sonography check? *Pediatr Radiol*. 2006;36:1252–6.
- Vezzani A, Brusasco C, Palermo S, *et al.* Ultrasound localization of central vein catheter and detection of postprocedural pneumothorax: an alternative to chest radiography. *Crit Care Med* 2010;38:533–8.
- Weekes AJ, Johnson DA, Keller SM, *et al.* Central vascular catheter placement evaluation using saline flush and bedside echocardiography. *Acad Emerg Med* 2014;21:65–72.
- Horowitz R, Gossett JG, Bailitz J, *et al.* The FLUSH study—flush the line and ultrasound the heart: ultrasonographic confirmation of central femoral venous line placement. *Ann Emerg Med* 2014;63:678–83.
- Gekle R, Dubensky L, Haddad S, *et al.* Saline Flush Test: Can Bedside Sonography Replace Conventional Radiography for Confirmation of Above-the-Diaphragm Central Venous Catheter Placement? *J Ultrasound Med* 2015;34:1295–9.
- Weekes AJ, Johnson DA, Keller SM, *et al.* Central vascular catheter placement evaluation using saline flush and bedside echocardiography. *Acad Emerg Med* 2014;21:65–72.
- Stonelake PA, Bodenham AR. The carina as a radiological landmark for central venous catheter tip position. *Br J Anaesth* 2006;96:335–40.
- Mahlon MA, Yoon HC. CT angiography of the superior vena cava: normative values and implications for central venous catheter position. *J Vasc Interv Radiol* 2007;18:1106–10.
- Buderer NM. Statistical methodology: I. Incorporating the prevalence of disease into the sample size calculation for sensitivity and specificity. *Acad Emerg Med* 1996;3:895–900.
- Ruesch S, Walder B, Tramèr MR. Complications of central venous catheters: internal jugular versus subclavian access—a systematic review. *Crit Care Med* 2002;30:454–60.
- Pikwer A, Bååth L, Davidson B, *et al.* The incidence and risk of central venous catheter malpositioning: a prospective cohort study in 1619 patients. *Anaesth Intensive Care* 2008;36:30–7.