

motor signs. For this reason we believe patients presenting with severe, unexplained shoulder girdle pain should be offered follow up, preferably by their general practitioner. If motor signs develop, the diagnosis can be confirmed with EMG and the patient reassured that the prognosis is excellent.

We thank Dr L A Loizou, Consultant Neurologist, for his help in the preparation of the manuscript.

- 1 Parsonage NJ, Turner JWA. Neuralgic amyotrophy—the shoulder girdle syndrome. *Lancet* 1948;ii:973–8.
- 2 Aymond JK, Goldner JL, Hardaker WT. Neuralgic amyotrophy. *Orthop Rev* 1989;12:1275–9.
- 3 Tonali P, Uncini A, Di Pasqua DG. So called neuralgic amyotrophy: clinical features and long-term follow-up. *Ital J Neurol Sci* 1983;4:431–7.
- 4 Rifisch A, van Laack W. Neuralgic amyotrophy of the lumbar area. *Arch Orthop Trauma Surg* 1989;108:329–32.
- 5 Pierre PA, Laterre CE, van den Bergh PY. Neuralgic amyotrophy with involvement of cranial nerves IX, X, XI and XII. *Muscle Nerve* 1990;13:704–7.
- 6 Mulvey DA, Aquilina RJ, Elliot MW, Moxham J, Green M. Diaphragmatic dysfunction in neuralgic amyotrophy: an

- electrophysiological evaluation of 16 patients presenting with dyspnoea. *Am Rev Respir Dis* 1993;147:66–71.
- 7 Ferrini L, Della Torre P, Preticoni G, Cantisani TA. Neuralgic amyotrophy of the shoulder girdle; the Parsonage-Turner syndrome. *Ital J Orthop Traumatol* 1986;12:223–31.
  - 8 Cumming WJK, Thrush DC, Kenwood DH. Bilateral neuralgic amyotrophy complicating Weil's disease. *Postgrad Med J* 1978;54:680–1.
  - 9 Reutens DC, Dunne JW, Leather H. Neuralgic amyotrophy following recombinant DNA hepatitis B vaccination. *Muscle Nerve* 1990;13:461.
  - 10 Malow MA, Dawson DM. Neuralgic amyotrophy in association with radiotherapy for Hodgkin's disease. *Neurology* 1991;41:440–1.
  - 11 Wyburn-Mason R. Brachial neuritis occurring in epidemic form. *Lancet* 1941;ii:662–3.
  - 12 Bardos V, Somodská V. Epidemiologic study of a brachial plexus neuritis outbreak in north east Czechoslovakia. *World Neurol* 1961;2:973–9.
  - 13 Sierra A, Prat J, Bas J, Romeu A, Montero J, Matos JAM, et al. Blood lymphocytes are sensitised to brachial plexus nerves in patients with neuralgic amyotrophy. *Acta Neurol Scand* 1991;82:183–6.
  - 14 Devathanan G, Tong HI. Neuralgic amyotrophy: criteria for diagnosis and a clinical with electromyographical study of 21 cases. *Aust NZ J Med* 1980;10:188–91.

## CASE REPORTS

# Potassium permanganate poisoning—a rare cause of fatal self poisoning

K L Ong, T H Tan, W L Cheung

### Abstract

**Attempted suicide by self poisoning is common because of the ready availability of drugs, whether prescribed or bought over the counter. In some cases, the ingestion of seemingly innocuous household products or chemicals can result in death. Potassium permanganate is an example. Poisoning with potassium permanganate can be fatal when a significant amount is ingested, as shown by a patient who suffered both the corrosive and systemic toxic effects of this chemical.**

(*J Accid Emerg Med* 1997;14:43–45)

Keywords: potassium permanganate poisoning; liver damage; kidney damage; laryngeal oedema

Potassium permanganate is a readily available over the counter agent that is widely used as an antiseptic for baths in patients with eczema—particularly the exudative types—due to its astringent properties. Historically its uses have been interesting: it has been used as an abortifacient,<sup>1</sup> as a urethral irrigation fluid for treatment of gonorrhoea, as a fluid for stomach washout in cases of alkaloid poisoning, and in the solid form as a local remedy for snake bite.<sup>2</sup>

Although the chemical is readily available, potassium permanganate poisoning is not common.

### Case report

Our patient was a 24 year Chinese female with no previous psychiatric history. She ingested an unknown quantity of potassium permanganate crystals after a domestic quarrel. She was immediately stopped by her relative and then drank a large amount of water. No other drug was ingested. She was first seen at a district hospital where gastric lavage was performed before her transfer to our department.

On arrival, she was alert and oriented. Her airway was patent and she had no stridor. There were brownish black stains on her hands and lips. There were similar staining of the entire oropharynx. The tongue and lips were swollen and bled on contact. Direct laryngoscopy under local anaesthesia showed a stained and oedematous pharynx, with gross swelling of the laryngeal structures. She was anaesthetised, intubated, and ventilated and was admitted to the intensive care unit.

Initial chest x ray was normal. Oesophagoscopy soon after admission showed staining of the upper oesophagus. The rest of the oesophagus, stomach, and duodenum were normal,

Department of  
Accident and  
Emergency, Prince of  
Wales Hospital, Shatin,  
Hong Kong

K L Ong  
W L Cheung

Department of  
Diagnostic Radiology,  
Caritas Medical  
Centre, Kowloon,  
Hong Kong  
T H Tan

Correspondence to:  
Dr Ong Kim Lian,  
Department of Accident and  
Emergency, Prince of Wales  
Hospital, Shatin, New  
Territories, Hong Kong.

Accepted for publication  
12 July 1996

with no evidence of burn or perforation. Follow up oesophagoscopy two days after admission was normal.

Activated charcoal and broad spectrum antibiotics were given after admission. Renal and liver function tests and complete blood picture were done and all were normal. Toxicological screen for paracetamol was negative. Serum amylase was normal. Methaemoglobinaemia level was normal at 0.5%.

During the first 24 hours after admission, her vital signs were stable although she required up to six litres of colloid to maintain her pulmonary artery wedge pressure. At about 36 hours she deteriorated with cardiovascular instability despite fluid loading and required adrenaline infusion. She developed disseminated intravascular coagulation with falling platelet count and prolonged activated partial thromboplastin time. Her liver function started to deteriorate, with rising alanine aminotransferase. By 48 hours she showed a clinical picture of acute hepatic necrosis which later deteriorated into fulminant hepatic failure. She was oliguric with a rising creatinine level due to acute tubular necrosis, and by 72 hours she required continuous veno-venous haemofiltration due to renal failure. By now she showed signs of adult respiratory distress syndrome. There was progressive cardiovascular failure and on day 6 she went into asystole and could not be resuscitated.

Necropsy examination showed severe fatty change and necrosis of the liver, consolidation of the lungs, and petechial haemorrhages of the subcortical and papillae regions of the kidneys, and these were consistent with her clinical findings. Serum manganese concentrations on day 5 and day 6 were between 756 and 1629  $\mu\text{mol/litre}$  (a level above 100  $\mu\text{mol/litre}$  is toxic).

### Discussion

Potassium permanganate is a powerful oxidising agent and it reacts with tissue to produce a coagulation type of necrosis similar to that produced by acid. It is readily reduced by organic matter and sometimes milk and egg white have been given to reduce toxicity.

The probable lethal adult dose of potassium permanganate is 10 g<sup>4</sup> or the equivalent of 1.5 teaspoons of crystals.<sup>3</sup>

Potassium permanganate is absorbed poorly by the gastrointestinal tract but systemic symptoms may result from oral exposure.<sup>5</sup> Our patient appeared to have absorbed most of the potassium permanganate from the oropharyngeal region as there was little evidence of the chemical in the rest of the gastrointestinal tract, judging by the absence of staining or corrosive effect in the lower oesophagus and the stomach and yet a markedly raised serum manganese level.

The immediate concern after the ingestion of potassium permanganate is the threat of acute laryngeal oedema<sup>6</sup> and this necessitates early endotracheal intubation or even emergency surgical airway. Although this patient did not have stridor at presentation, there was

laryngeal oedema and this would probably have progressed to upper airway obstruction with time.

Manifestations of the gastrointestinal effects include nausea and vomiting in the mild cases. Burns and ulceration of the mouth, oesophagus, and stomach occur and are due to its caustic action. It combines with proteins to form proteinate and with fats to form soaps, resulting in necrotic ulcers which may continue to penetrate for days<sup>7</sup> and may lead to perforation. Early oesophagoscopy is recommended to assess the severity of the oesophageal burns, although the manganese staining may obscure the area of the burn. Haemorrhagic pancreatitis has also been reported in a patient who ingested 20 g of potassium permanganate<sup>8</sup> but this was not seen in our patient. Late complications of upper gastrointestinal ulceration include oesophageal stricture<sup>9</sup> and pyloric stenosis.<sup>10</sup> Hepatic and renal damage has been well documented and in one patient, liver damage occurred after self injection of potassium permanganate into the chest.<sup>11</sup> Our unfortunate patient suffered both the hepatic and renal toxic effects of potassium permanganate.

Methaemoglobinaemia has been reported,<sup>12</sup> although it did not occur in our patient. Cardiovascular depression and collapse with shock is another feature of severe potassium permanganate poisoning although the pathogenesis is uncertain and it is often the cause of death in those who do not succumb to the immediate threat of airway obstruction or massive haemorrhage due to gastrointestinal erosions.

The mainstay in the treatment of potassium permanganate is supportive. The immediate priority is to secure the airway. Although gastric lavage has been recommended by some,<sup>6</sup> it is potentially hazardous<sup>7</sup> as there is danger of perforation. The effectiveness of activated charcoal is not known in potassium permanganate poisoning and thus its administration is controversial. Drinking of milk or water may have a diluting and neutralising effect.<sup>13</sup> Early oesophagoscopy is useful to determine the extent of upper gastrointestinal injury. Useful investigations include liver and renal function tests, methaemoglobin level, serum amylase, and serum manganese. Other supportive treatment includes the administration of methylene blue and vitamin C for methaemoglobinaemia<sup>12</sup> and broad spectrum antibiotics in view of the risk of perforation and subsequent peritonitis. The use of corticosteroids is controversial although it has been postulated that they minimised tissue oedema and the pathological inflammatory response in one patient.<sup>13</sup>

Thus what appears to be a harmless topical agent can, when ingested in sufficient amounts, result in widespread systemic toxicity that can cause much morbidity and even mortality.

- 1 McDonough JF. Vaginal bleeding from potassium permanganate as abortifacient. *N Engl J Med* 1945;232:189.
- 2 Willimott SG, Freiman M. Potassium permanganate poisoning. *BMJ* 1936;i:58-9.
- 3 Cowie RL, Escreet BC. Potassium permanganate toxicity. *South Afr Med J* 1981;60:304.

- 4 Deichmann WB, Gerarde HW. Toxicology of drugs and chemicals. New York: Academic Press, 1969.
- 5 Ellenhorn MJ, Barreloux DG. Metals and related compounds. In: Medical toxicology—diagnosis and treatment of human poisoning. New York, Elsevier, 1988:1057–8.
- 6 Gosselin RE, Smith RP, Hodge HC. Clinical toxicology of commercial products. Baltimore: Williams & Wilkins, 1984.
- 7 Dreisbach RH, Robertson WO. Handbook of poisoning: prevention, diagnosis and treatment. California: Lange Medical Publications, 1983.
- 8 Middleton SJ, Jacyna M, McClaren D, Robinson R, Thomas HC. Haemorrhagic pancreatitis—a cause of death in severe potassium permanganate poisoning. *Postgrad Med* 1990;66:657–8.
- 9 Kochhar R, Das K, Mehta SK. Potassium permanganate induced oesophageal stricture. *Hum Toxicol* 1986;5:393–4.
- 10 Dagli AJ, Golden D, Finkel M, Austin E. Pyloric stenosis following ingestion of potassium permanganate. *Am J Dig Dis* 1973;18:1091–4.
- 11 Lustig S, Pitlik SD, Rosenfeld JB. Liver damage in acute self-induced hypermanganemia. *Arch Intern Med* 1982; 142:405–6.
- 12 Mahomedy MC, Mahomedy YH, Canham PA, Downing JW, Jeal DE. Methaemoglobinaemia following treatment dispensed by witch doctors. Two cases of potassium permanganate poisoning. *Anaesthesia* 1975;30:190–3.
- 13 Southwood T, Lamb CM, Freeman J. Ingestion of potassium permanganate crystals by a three year old boy. *Med J Aust* 1987;146:639–40.

## Inadvertent intracranial insertion of a nasogastric tube in a non-trauma patient

R M Freij, S T H Mullett

### Abstract

**Complications following nasogastric intubation in patients with basal skull fractures are well documented. This report is of a rare cause of inadvertent intracranial placement of a nasogastric (NG) tube in a non-trauma patient. The patient subsequently died. The use of NG tubes, their place in airway management, and lessons to be learned from this case are discussed.** (*J Accid Emerg Med* 1997;14:45–47)

Keywords: nasogastric tube; aspiration; airway; frontoethmoidal defect

### Case report

A 59 year female patient with a history of known epilepsy presented to our accident and emergency (A&E) department in status epilepticus of six hours' duration. The fit was terminated on arrival by administering intravenous diazepam. She was resuscitated with high flow

oxygen, an oropharyngeal airway was inserted, and intravenous fluids were given. The history obtained from her husband was of several hours vomiting before the fit, but no history of any febrile illness or upper respiratory tract symptoms. She had been epileptic for 12 years, and despite taking vigabatrin (Sabril) and sodium valproate was poorly controlled. Of relevance in her past medical history was that she had suffered from an episode of pneumococcal meningitis before the start of her epilepsy.

On examination she was pyrexial (38.4°C) with a tachycardia of 130 beats/min. There was decreased air entry to the right lung base, consistent with aspiration, later confirmed by chest radiograph. Her Glasgow coma score was between 6 and 10. Further examination revealed no other abnormalities.

She was nursed in the recovery position. To reduce the risk of further aspiration the insertion of a nasogastric tube (NG) was

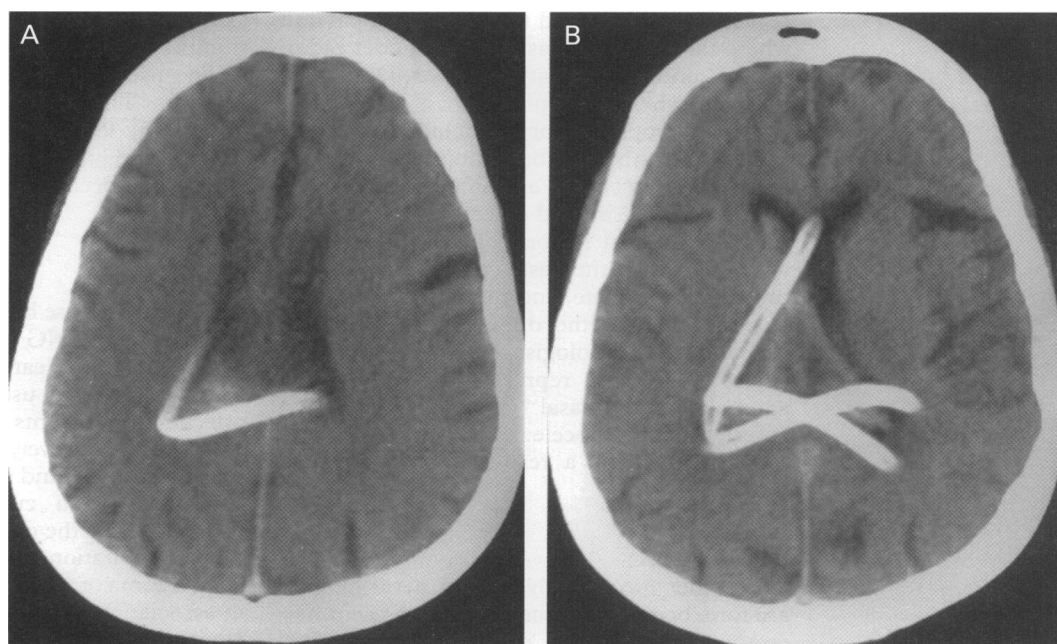


Figure 1 Computerised tomography scan showing the intracranial placement of the nasogastric tube.

Department of  
Accident and  
Emergency Medicine,  
Central Middlesex  
Hospital, Acton Lane,  
Park Royal, London  
NW10 7NS  
R M Freij  
S T H Mullett

Correspondence to:  
R M Freij FRCS, Registrar  
in Accident and Emergency  
Medicine. e-mail  
101453.2323@  
compuserve.com

Accepted for publication  
17 July 1996