

LETTERS TO THE EDITOR

Radiography for head trauma in children: what guidelines should we use?

EDITOR,—I was very interested to read the paper by Moreea *et al* from the Leeds General Infirmary comparing a set of British and American guidelines for the use of skull radiography in children.¹ If statistically valid, their conclusion that we should follow the American guidelines would result in a considerable financial saving and reduction in unnecessary and potentially harmful radiation.

However, there are a couple of points of confusion which their paper introduces. Firstly, their guidelines compare British criteria for x ray with American criteria for NO x ray. The list of criteria for NO x ray reads: "Asymptomatic; Headache; Scalp laceration/contusion/abrasion/haematoma; Dizziness; Absence of other risk criteria."

This is clearly nonsense, as it would imply that anybody with, say, a scalp laceration does not need an x ray—notwithstanding any other signs or symptoms that may be present. The paper from which these recommendations are taken, by Masters *et al*,² divides patients into three groups: a high risk group, requiring neurosurgical consultation or emergency CT, a low risk group requiring discharge with head injury advice, and a moderate risk group in whom close observation is recommended and possibly skull x ray, although CT should also be considered. Masters *et al* gave a list of criteria which would indicate that a patient should be in the moderate risk group. These were not reproduced by Moreea *et al* and without them it is, of course, impossible to follow the guidelines. For the record, these criteria are:

- History of change of consciousness at the time of injury or subsequently
- History of progressive headache
- Alcohol or drug intoxication
- Unreliable or inadequate history of injury
- Age less than 2 years (unless injury very trivial)
- Post-traumatic seizure
- Vomiting
- Post-traumatic amnesia
- Multiple trauma
- Serious facial injury
- Signs of basilar fracture
- Possible skull penetration or depressed fracture
- Suspected non-accidental injury

Also, in the paper by Moreea *et al* the figures given in table 4 are completely different from those described under the paragraph beginning "table 4 shows . . ." in the text.

F L P HEYES

Accident and Emergency Department, Rotherham District General Hospital, Rotherham, South Yorkshire S60 2UD

- 1 Moreea S, Jones S, Zoltie N. Radiography for head trauma in children: what guidelines should we use? *J Accid Emerg Med* 1997;14:13-15.
- 2 Masters SJ, Maclean P, Arcarese JS, Brown RF, Kembell JA, Freed HA, *et al*. Skull examinations after head trauma. *N Engl J Med* 1987;316:84-91.

Drug doses in children

EDITOR,—Greig *et al* demonstrate the potential inaccuracies of calculating drug doses and fluids based on estimates of weight in children.¹ Weighing children is routine in paediatric accident and emergency and outpatient departments, and usually involves undressing younger children. Indeed, parents expect younger children to be undressed for weighing, based on their experience at Health Visitor clinics.

There is another important message for general departments: undressing younger children for weighing also allows visual inspection for signs of non-accidental injury, particularly in non-mobile children, and is an opportunity not to be missed.

S M HEWITT

Accident and Emergency Department, Derbyshire Royal Infirmary, Derby DE1 2QY

- 1 Greig A, Ryan J, Glucksman E. How good are doctors at estimating children's weight? *J Accid Emerg Med* 1997;14:101-3.

Bradycardia due to an eye dressing

EDITOR,—We wish to warn of the potential danger of facial dressings placed over the eye which may cause stimulation of the oculovagal reflex and produce profound bradycardia and circulatory collapse.

A normally fit young man attended the accident and emergency department following an assault with a machete. He had wounds to the left chest and a pressure dressing over his left face, which had been applied by the paramedics.

On arrival the patient was talking anxiously. He had a respiratory rate of 17/min, a central trachea, and symmetrical air entry. Oxygen saturation was 97%. Heart rate was 50 beats/min and blood pressure 109/70 mm Hg. Heart sounds were heard clearly and jugular venous pressure was not elevated. Within five minutes he became sweaty and less responsive. His pulse rate had fallen to 37/min. Review of his airway and breathing showed no deterioration. Before giving atropine his facial dressing was removed, whereupon his pulse rate rapidly increased to 80/min, his blood pressure increased to 150/60 mm Hg, and his anxiety decreased. Radiology of the chest and face was normal.

The oculocardiac reflex described by Aschner in 1908¹ involves an afferent pathway via the trigeminal nerve, the reticular formation of the brain stem, and the vagus. Compression of the orbit causes bradycardia. Bradycardias have been observed with direct pressure from a Honan balloon,² and during surgery of facial fractures.³ This patient was relatively bradycardic on arrival and rapidly deteriorated. Prompt recognition of the role of the oculocardiac reflex reversed his shock. The bradycardia was caused by the pressure dressing alone and not by any underlying injury.

K LENDRUM

M W COOKE
Accident and Emergency Department, City Hospital, Dudley Road, Birmingham B18 7QH

- 1 Aschner B. Über einen bisher noch nicht beschriebenen Reflex vom Auge auf Kreislauf und Atmung. *Wien Klin Wochenschr* 1908;21:1529.
- 2 Arnold RW, Gould RB, MacKenzie R, Dyer JA, Low PA. Lack of global propensity in patients with oculocardiac reflex. *Ophthalmology* 1994; 101:1347-52.
- 3 Stott DG. Reflex bradycardia in facial surgery. *Br J Plast Surg* 1989;42:595.

Injuries from broken china

EDITOR,—Injuries from broken china are commonly seen in the accident and emergency department. Often the hands are injured during the washing of crockery, although domestic altercations and enthusiastic postprandial entertainments may also be responsible.

It has long been established that all forms of glass are radio-opaque,^{1,2} but the properties of china have been less well defined. Metal salts are added to silica in the manufacture of both glass and china clay but lead is added only to glass and this is thought to increase its radiodensity.

Patients who have sustained lacerations to their hands from broken china are often seen in A&E. In managing these injuries it is important to know whether china fragments are radio-opaque, and therefore if x rays can be expected to reveal any significant foreign body.

We conducted a simple experiment to determine whether china fragments are detectable by x rays when embedded in human tissue. A chicken drumstick was used as an animal model of a metacarpal or phalanx. Pieces of china and glass of various dimensions were inserted into the muscles and x rays taken at various exposures. Using a range of exposures we found that 45 mV, which is exactly that used for glass localisation in the hand, gave the clearest image.

As is clear from the x ray shown (fig 1) all forms of china are well demonstrated, even if they are small. China has a radiodensity indistinguishable from glass, and the type of china seems to be irrelevant, as does the presence of glaze, metallic or otherwise, on the china fragments.

It has long been accepted that wounds due to glass should be x rayed; not to do so is negligent if a retained fragment is missed. We suggest that wounds due to broken china should also be x rayed to reveal the presence or absence of a china foreign body.

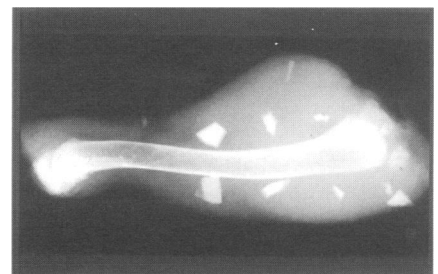


Figure 1 Radiograph of a chicken drumstick taken at 45 mV showing glass and china fragments.