

missed by a routine clinical examination. It would be interesting for these data to be subjected to peer review so that they may be more thoroughly evaluated by a wider audience.

- 1 Turner M, Esaw M, Clark RJ. Carbon monoxide poisoning treated with hyperbaric oxygen: metabolic acidosis as an indicator of treatment requirements. *J Accid Emerg Med* 1999;16:96-8.
- 2 Turner M, Hamilton-Farrell MR, Clark RJ. Carbon monoxide poisoning: an update. *J Accid Emerg Med* 1999;16:92-6.

### Pre-hospital nalbuphine analgesia

EDITOR,—I read with interest the paper by Houlihan *et al.*<sup>1</sup> I thus ask the question why they did not continue to use nalbuphine as the analgesic in their accident and emergency unit? It is a drug that has been around since 1963 with only about 80 or 90 adverse reactions and no deaths ever related to this analgesic. Its dosage has been described as up to 200 mg without adverse effects. One would have thought that in cases 1 and 2, if their patients required further analgesia, they could have continued with a 20 mg or 40 mg dose as needed to control the pain, without resorting to opiates.

ALAN G JONES  
Consultant in Accident and Emergency,  
Accident and Emergency Unit,  
Queen Elizabeth the Queen Mother Hospital,  
St Peter's Road, Margate,  
Kent CT9 4AN

- 1 Houlihan KPG, Mitchell RG, Flapan AD, *et al.* Excessive morphine requirements after pre-hospital nalbuphine analgesia. *J Accid Emerg Med* 1999;16:29-31.

### The authors reply

We read with interest Dr Jones' comments on our article. We agree that nalbuphine is a potent analgesic agent with few adverse effects and no reported fatalities. Nalbuphine has gained wide acceptance in a variety of clinical situations including the field of pre-hospital care. We acknowledge that it is possible to persevere with nalbuphine when additional analgesia is required after arrival in hospital, but it is our experience that the treatment of moderate to severe pain more commonly includes the administration of intravenous morphine and related opioids which are titrated to gain rapid and effective pain relief. This policy is adopted by the majority of clinicians involved in treating acute medical and surgical emergencies in our area. The prime objective of our article was to report excessive morphine requirements in certain patients who had received nalbuphine before arrival at hospital. This phenomenon has been previously discussed but only as a theoretical occurrence and had not been reported in practice. We contend that our experience merits discussion and additional evaluation of policies of analgesia administration.

### Securing intercostal drains

EDITOR,—The method of securing chest drains described by Boyle using a 1cm cylinder of portacath tubing provides a simple technique for adjusting the position of an intrapleural drain.<sup>1</sup> However, the commonest reason for a chest drain "falling out" is that an inadequate bite of tissue is taken with an anchoring suture of inadequate tensile strength. It is not commonly due to poor knot tying by inexperienced clinicians. As a further simplification of the method described, if the

chest drain is moved to one end of the chest wall wound, a single suture (for example a No 1 Ethilon suture on a curved hand held needle) secured as described by Boyle would hold the drain in situ perfectly adequately. If this single anchoring suture were tied flush thus approximating the skin against the intercostal tubing, then any potential air leak at skin level (should it prove necessary to apply high flow low pressure suction) would be obliterated. The remainder of the chest wound can then be closed with simple interrupted sutures of the clinician's choice.

JOHN J M BLACK  
Senior Registrar,  
Emergency Medicine, Wycombe Hospital,  
Queen Alexandra Road,  
High Wycombe, Bucks HP11 2TT

- 1 Boyle A. Securing intercostal drains. *J Accid Emerg Med* 1999;16:239.

### Ectopic pregnancy

EDITOR,—The diagnosis of ectopic pregnancy continues to present a challenge to the emergency physician as reliance on the standard history and examination is insufficiently sensitive. Early diagnosis and referral limit the morbidity and mortality associated with this potentially life threatening condition, which accounts for 8% of all maternal deaths.<sup>1</sup> Previous studies have shown that only 33%–53% of cases are diagnosed correctly on initial presentation.<sup>2,3</sup> Clancy and Illingworth have suggested that incorrect diagnoses were made either because ectopic pregnancy was not considered or because relevant symptoms and signs were overlooked.<sup>3</sup>

Dart *et al* identified findings in both the history and physical examination that were predictive.<sup>4</sup> Pain that was moderate to severe, lateral in location, and/or sharp in nature was important. The presence of an intrauterine contraceptive device within the previous year, a history of infertility, pelvic surgery, or tubal ligation were also noted to be predictive for ectopic pregnancy. The presence of cervical excitation, lateral or bilateral abdominal tenderness, lateral or bilateral pelvic tenderness, and positive peritoneal signs were important in the examination. However no constellation of findings resulted in a highly reliable diagnostic tool. The most important of these signs were the history of tubal ligation (odds ratio 18.0) and the presence of positive peritoneal signs (odds ratio 7.9).

We performed a retrospective case note review of all patients attending the West Middlesex University Hospital accident and emergency department between January 1994 and June 1998 (55 months) in whom an ectopic pregnancy was subsequently confirmed. We looked in detail at those in whom there was a delay before diagnosis using an evaluation questionnaire to assess the clinical findings.

Of 109 patients, 70 (64%) cases of ectopic pregnancy were correctly diagnosed at first presentation. In the remaining 39 cases (36%) the most common historical features leading to a diagnostic delay were the absence of pain or the poor localisation of that pain. The most common atypical findings were the absence of cervical excitation and adnexal tenderness. The most common initial misdiagnosis was miscarriage.

The diagnosis of ectopic pregnancy continues to be difficult, mainly because the symptoms and signs often do not fit a recognised pattern. In particular the presence of abdominal pain is considered to be impor-

tant in the diagnosis of ectopic pregnancy, as is adnexal pain and cervical excitation. Doctors may not consider the diagnosis of ectopic pregnancy when any one of these features is absent. The diagnosis must always be considered in pregnant patients who have yet to have an intrauterine pregnancy confirmed on ultrasound scan. It is essential that the presence, location, and nature of pain is fully elucidated. In addition, a history of tubal surgery should always be sought.

S S AHMAD  
Registrar,  
Department of Accident and Emergency Medicine,  
West Middlesex University Hospital

K CHUMBLEY  
Senior House Officer,  
Department of Obstetrics and Gynaecology,  
Hillingdon Hospital

D HULBERT  
Consultant,  
Department of Accident and Emergency Medicine,  
West Middlesex University Hospital,  
Twickenham Road,  
Isleworth, Middlesex TW7 6AF

- 1 Department of Health and Social Security. Report on confidential enquiries into maternal deaths in the United Kingdom 1988-90. London: HMSO, 1994;6:66-7.
- 2 Gilling-Smith C, Panay N, Wadsworth J, *et al.* Management of women presenting to the accident and emergency department with lower abdominal pain. *Ann R Coll Surg Engl* 1995;77:193-7.
- 3 Clancy M J, Illingworth RN. The diagnosis of ectopic pregnancy in an accident and emergency department. *Arch Emerg Med* 1989;6:205-10.
- 4 Dart RG, Kaplan B, Varaklis K. Predictive value of history and physical examination in patients with suspected ectopic pregnancy. *Ann Emerg Med* 1999;33:283-90.

### Foreign body in the throat

EDITOR,—A 1 year old baby girl was brought to the accident and emergency (A&E) department of Bishop Auckland General Hospital with a history of "swallowing" a ring that she and her 4 year old sister had been playing with. She had difficulty in breathing with choking, coughing, and blueness of the face.

She arrived in the A&E department in a distressed condition with the mother holding her head down as this eased her breathing. Portable radiography of the chest and neck revealed a radio-opaque foreign body (ring) lodged in the upper respiratory tract (fig 1). Back slapping and attempted finger sweep of the mouth and throat was unsuccessful. The child was kept in the head down position until a general anaesthetic could be administered and the ring retrieved from her pharynx.

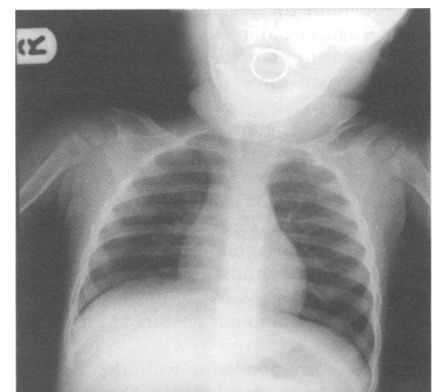


Figure 1 Radiograph showing ring in the child's throat.