

EMERGENCY CASEBOOKS

A magnetic nasal attraction

V M M Ward, D Selvadurai

A 12 year old girl presented to the ear, nose, and throat department with a history of foreign bodies in both nostrils. The young girl had attempted to wear magnetic earrings as nose rings. Unfortunately both magnets became polarised and attracted across the septum (see fig 1).

We present a simple and easy solution for removal under local anaesthesia with a mixture of lignocaine and phenylephrine in an accident and emergency setting. It is possible to polarise a wax hook, which has magnetic properties, by rubbing it with another instrument (wax hook or Jobson horn). One of the magnets was then attracted away from the septum by the polarised wax hook, thus releasing the magnetic attraction of the opposing magnet.

They were successfully removed without any significant trauma to the septum. The underlying mucosa, however, was indurated due to local pressure. The most common complication of foreign bodies is septal perforation, thus

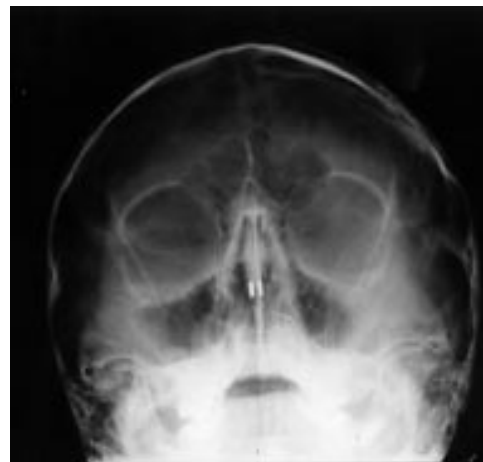


Figure 1 Radiograph showing the magnets on either side of the septum.

identification and removal of the offending foreign body is paramount to its prevention.

Ear, Nose, and Throat Department, Leicester Royal Infirmary, Infirmary Square, Leicester LE1 5WW
V M M Ward
D Selvadurai

Correspondence to: Miss Ward

Complete open dislocation of the talus

Elisha Krasin, Michal Goldwirth, Itzhak Otremski

A 64 year old man fell from a ladder directly onto his right foot. Physical examination disclosed a wound on the lateral aspect of the ankle and the midfoot. The talus was completely

dislocated and loosely connected to some soft tissue. There were no other apparent injuries except a non-displaced fracture of the fifth metatarsal head. After radiography of the

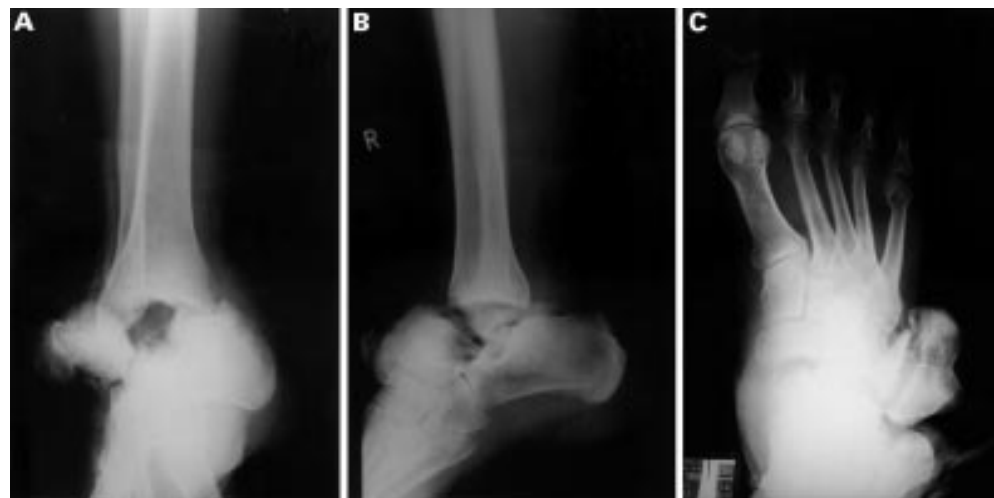

Figure 1 (A)-(C) Anteroposterior and lateral radiographs of the ankle and the foot on admission, demonstrating complete lateral dislocation of the talus and an associated fracture of the fifth metatarsal head.

Department of Orthopaedics "A", Tel-Aviv Sourasky Medical Centre affiliated to the Sackler Faculty of Medicine, Tel-Aviv University, Tel-Aviv, Israel
E Krasin
M Goldwirth
I Otremski

Correspondence to: Dr Elisha Krasin, Resident in Orthopaedic Surgery, Department of Orthopaedics "A", Tel-Aviv Sourasky Medical Centre, 6 Weizman Street, Tel-Aviv 64239, Israel (e-mail: ekrasin@tasmc.health.gov.il)

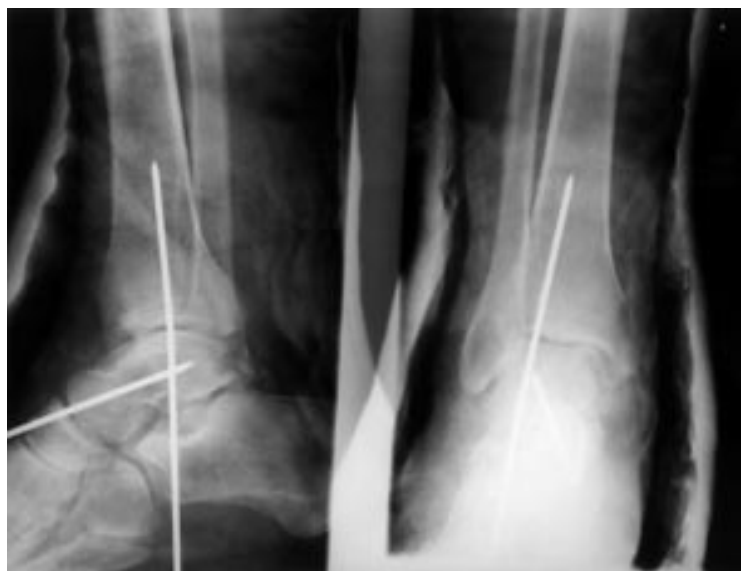


Figure 2 Postoperative anteroposterior and lateral radiographs of the ankle demonstrating the reduction and internal fixation of the talus.

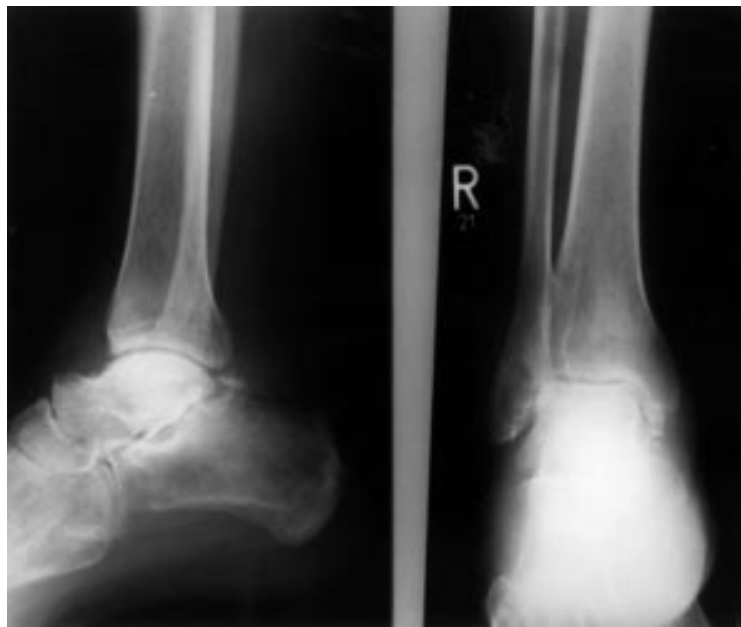

Figure 3 One year postoperative radiographs demonstrating avascular necrosis of the talar body.

injured area (fig 1A–C), the patient underwent surgery that involved a thorough irrigation of the wound, debridement of avascular skin and soft tissue, and reduction of the talus, followed by fixation by Steinmann pins and primary closure. The leg was placed in a short leg cast (fig 2). His

postoperative course was unremarkable, and he was discharged from the hospital with the recommendation to avoid any weight bearing on his right foot. After six weeks, the cast and the pins were removed and weight bearing was gradually resumed. At the one year follow up he continued to complain of ankle and foot pain. On examination the ankle was swollen and painful, and there was limitation of motion at the ankle and the subtalar joints. Radiography showed signs of avascular necrosis of the talus (fig 3). The patient preferred conservative treatment, involving the use of an ankle brace and analgesic medications.

Complete open dislocation of the talus from all its adjacent joints with or without a fracture is a very rare type of injury, with only a few such cases having been described in the literature.^{1–4} It is usually a consequence of a severe trauma to the foot incurred by a car or motorcycle accident or a fall from height. In some cases the talus is completely disconnected from the foot (“missing talus”).¹ Treatment usually involves irrigation, debridement, open reduction, some method of internal fixation, and primary or secondary closure of the wound. Tibiocalcaneal arthrodesis can be performed in cases of a “missing talus”.¹ Long term results are variable: some reports describe good results and functional outcome,^{2–4} while others describe high rates of infection, avascular necrosis of the talus,⁴ wound healing problems, and prolonged postoperative pain.¹ Palomo-Traver *et al* report that late avascular necrosis or ankle joint arthrosis may be treated by talectomy with or without some form of arthrodesis,² but Ritsema recommends that talectomy should be avoided.⁴

Avascular necrosis and infection are the most common complications and they can be anticipated among many of the patients, even if the primary treatment was appropriate. Development of arthrosis in the surrounding joints can cause long term pain and disability, and probably can be treated successfully by conventional methods such as ankle joint arthrodesis or triple arthrodesis.

- 1 Hiraizumi Y, Hara T, Takahashi M, *et al*. Open total dislocation of the talus with extrusion (missing talus): report of two cases. *Foot and Ankle* 1992;13:473–7.
- 2 Palomo-Traver JM, Cruz-Renovell E, Granell-Beltran V, *et al*. Open total talus dislocation: case report and review of the literature. *J Orthop Trauma* 1997;11:45–9.
- 3 Korovessis P, Spastris P, Sidiropoulos P, *et al*. Complete lateral dislocation of the talus without fracture. *J Orthop Trauma* 1992;6:125–8.
- 4 Ritsema GH. Total talar dislocation. *J Trauma* 1988;28:692–4.

Unguarded electric plugs cause penetrating head injuries in children

G W Couper, D E Boddie, M S Eljamel, G F Kaar

A 9 month old boy fell from a bed onto an electric plug embedding the earth pin within his skull. The child did not lose consciousness and the mother removed the plug causing initial brisk bleeding. Examination revealed a 1 cm laceration to the left of the midline in the frontal area immediately behind the hairline. Neurological examination was normal. Radiography of the skull demonstrated a depressed skull fracture (fig 1). The wound was debrided under general anaesthesia with prophylactic antibiotic cover. The bone fragments were raised to reveal an intact dura. The fragments were washed and replaced and the pericranium, galea, and skin closed in separate layers. Postoperative recovery was uncomplicated with no long term sequelae at follow up.

A second child of 17 months attended the casualty department with an electric plug embedded in the left parietal area of his skull, again after falling out of bed. There had been no loss of consciousness and the child was alert and well. The live pin of the plug was almost completely embedded in the skull. Radiography demonstrated a depressed fracture beneath the pin (fig 2). Under general anaesthesia the plug was dismantled, the wound extended and debrided. The penetrating pin was removed and the fracture enlarged to reveal a 1cm laceration to the dura. There was no significant underlying brain injury. The dura was repaired, the bone fragments were replaced, and the wound closed in layers. Postoperative recovery was unremarkable and the child remained well at 12 month follow up.

Children under 5 years of age rarely sustain injury falling out of bed.^{1 2} Most falls are onto carpeted floors that help cushion the impact. The small percentage of skull fractures that do occur in young children from short distance falls are generally uncomplicated, linear frac-

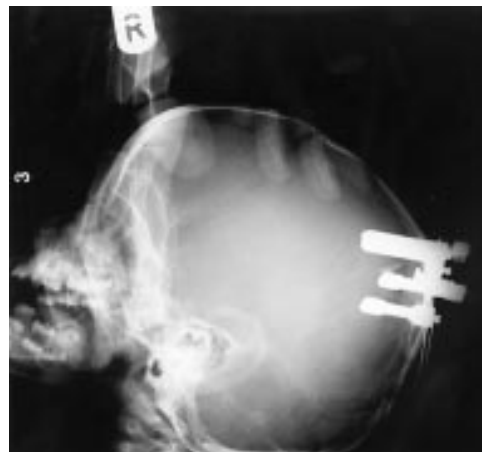


Figure 2 Embedded plug with underlying fracture.

tures which rarely have long term sequelae.³ However, the relatively soft skull of a child striking a hard object can result in a penetrating injury. These cases illustrate the potential hazards for young children from such seemingly innocuous household items. In case 1 involvement of the sagittal sinus could have resulted in air embolism or exsanguination on removal of the plug by the mother at home. If, as in case 2, the plug is still embedded at the time of presentation controlled removal in theatre is essential.

A review of 520 children admitted to the Royal Aberdeen Children's Hospital with a skull fracture over a 24 year period identified only 25 patients (4.8%) with an open injury. Road traffic accidents, falls, and golf club injuries^{4 5} were the most common cases of these latter serious injuries. Fourteen patients required surgery, the remainder were managed by immediate wound toilet and penicillin based antimicrobial prophylaxis. Of the 14 patients who underwent exploration seven (50%) had a dural tear. Prophylactic anticonvulsants were not routinely prescribed and no child during the review period developed post-traumatic epilepsy or infective complications.

In conclusion, we highlight a previously unreported mechanism of open head injury in children resulting from unguarded electric plugs. When such a history is obtained skull radiography should be performed, despite an unremarkable clinical examination, to exclude an underlying skull fracture and dural tear.

- 1 Helfer RE, Slovis TL, Black M. Injuries resulting when small children fall out of bed. *Pediatrics* 1977;60:533-5.
- 2 Root I. Head injuries from short distance falls. *Am J Forensic Med Pathol* 1992;13:85-7.
- 3 Sheridan F, Anthony AM, Reiber GD, et al. Head injuries from short distance falls. *Am J Forensic Med Pathol* 1992;14:172-3.
- 4 Lindsay KW, McLatchie G, Jennet B. Serious head injury in sport. *BMJ* 1980;281:789-91.
- 5 Smith RA, Ling S, Alexander FW. Golf related head injuries in children. *BMJ* 1991;302:1505-6.

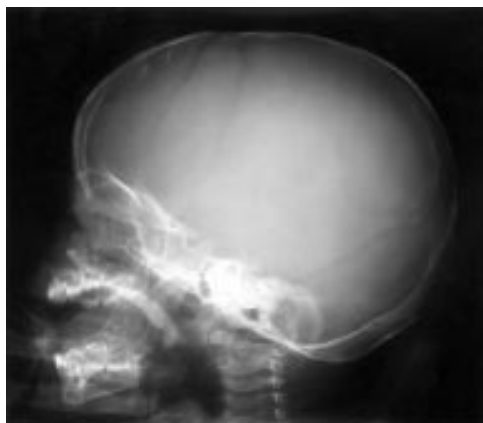


Figure 1 Depressed frontal skull fracture.

Department of
Neurosurgery,
Aberdeen Royal
Infirmery
G W Couper
D E Boddie
G F Kaar

Department of
Neurosurgery, Dundee
Royal Infirmery
M S Eljamel

Correspondence to:
Mr George Kaar, Consultant
Neurosurgeon, Ward 40,
Aberdeen Royal Infirmery,
Foresterhill, Aberdeen
AB25 2ZD

Occult injury in a diabetic

P A Leonard, J O'Donnell

A 55 year man presented to the accident and emergency department with a bluish discoloration of his left second toe. He did not complain of any pain but had noticed the colour change while in the bath the previous evening. Three years previously he had been recognised to have type 2 (non-insulin dependent) diabetes, and was subsequently managed with a combination of diet and oral hypoglycaemic agents. He had not been seen at the diabetic clinic for nearly two years. Despite current recommendations¹ he did not usually check his feet and had no regular follow up by a chiropodist.

Clinical examination showed a strong femoral pulse but absent ankle and foot pulses on the left, and black-blue discoloration of the second toe leading to a provisional diagnosis of vascular insufficiency with gangrene. A sensory peripheral neuropathy to the level of the ankle joint was demonstrated. Admission for intravenous antibiotics and angiography was arranged. A radiograph of the foot was taken to detect any changes suggestive of osteomyelitis. This demonstrated the presence of a radiopaque foreign body (a nail) within the soft tissues of the foot (fig 1).

On further questioning the patient had no recollection of standing on a nail nor was he aware that he had any sensory disturbance in his feet. Unfortunately he required amputation of the toe and a prolonged hospital stay for repeated dressing changes and antibiotics.

This case highlights the importance of recognising that occult injury can occur in the

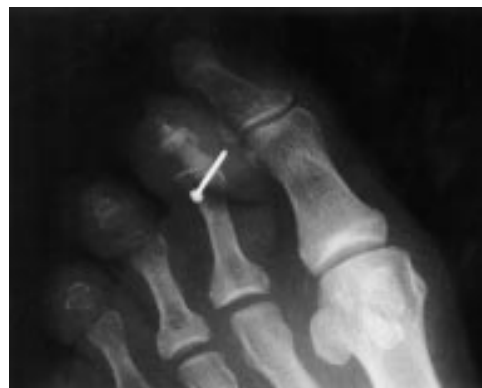

Figure 1 Radiograph showing the presence of a nail in the soft tissues.

feet of diabetics with peripheral neuropathy.² In such patients coexistent peripheral vascular disease adds to the resultant morbidity by increasing the predisposition to infective complications. Particular attention should be paid to the possibility of painless injury and a low threshold for radiography is indicated. Follow up at a specialist diabetic foot clinic should be considered for all these patients.

We would like to thank Mr D Steedman, Consultant in Accident and Emergency Medicine, for permission to publish this case.

- 1 Bulat T, Kosinski M. Diabetic foot: strategies to prevent and treat common problems. *Geriatrics* 1995;**50**:46–55.
- 2 Levin M. Diabetic foot wounds: pathogenesis and management. *Advances in Wound Care* 1997;**10**:24–30.

**Department of
Accident and
Emergency, Royal
Infirmary of
Edinburgh, Lauriston
Place, Edinburgh EH3
9YW**

P A Leonard
J O'Donnell

Correspondence to:
Dr Leonard, Specialist
Registrar