

## EMERGENCY CASEBOOKS

## Two cases of near asphyxiation in children, using non-releasing plastic garden ties

N Makwana, H M Evans, D Moore, K Berry

We present two cases of children recently seen in our accident and emergency (A&E) department with near asphyxiation attributable to non-releasing plastic garden ties around the neck.

**Case 1**

A 6 year old boy presented after his older brother had put a non-releasing garden tie around his neck during unsupervised play in the garden. He was unable to release the tie and in his attempt to do so, pulled it tighter. Fortunately, his grandmother was quick to respond and cut the tie off with kitchen scissors. On examination, he had petechiae over his face but neither neck swelling or apparent trauma to his larynx. He had a 1 cm × 1 cm, V shaped laceration to his neck where the tie had been cut off. He required no treatment other than a warning of the obvious dangers of his actions.

**Case 2**

A 10 year old boy arrived as a helicopter transfer to the Birmingham Children's Hospital Accident and Emergency Department after near asphyxiation secondary to a similar but larger non-releasing tie around the neck. This incident occurred on a golf course and his father's attempts to remove it only served to tighten it further. No one had a sharp implement to hand and the ligature was in place for 5-10 minutes before finally being removed. When the paramedic team arrived, the child was unresponsive but self ventilating. On assessment in the A&E department he had facial congestion with central cyanosis with extensive well demarcated petechial haemorrhages from the neck upward and bilateral conjunctival haemorrhages (fig 1). He was extremely agitated and confused, being totally uncooperative. He was stabilised, intubated and ventilated. Subsequently he underwent computed tomography, which showed mild cerebral oedema. He was transferred to the paediatric intensive care unit for monitoring and was extubated that evening with no apparent neurological deficit. He was observed for a further 48 hours and was fortunate to survive this episode without sustaining major neurological injury.

**Discussion**

There are no similar reported cases of near asphyxiation of these widely available garden ties. Some reported cases of asphyxiation in children include accidental strangulation including drawstrings,<sup>1</sup> car electric windows,<sup>2</sup> and stroller prams.<sup>3</sup> All these cases proved fatal.

Clinical features of ligature strangulation resemble those of non-judicial hanging as there is no significant drop involved and injury occurs secondary to compression of neck structures. The features include marks around the neck from the device used for hanging as well as skin and subconjunctival petechial haemorrhages because of increased venous pressure.<sup>4</sup> These are not invariable but were found in both cases presented here.

The treatment of both our patients was principally supportive with endotracheal intubation as necessary. Cervical spine injury has not been reported and is unlikely in ligature strangulation victims. As in one of our cases severe

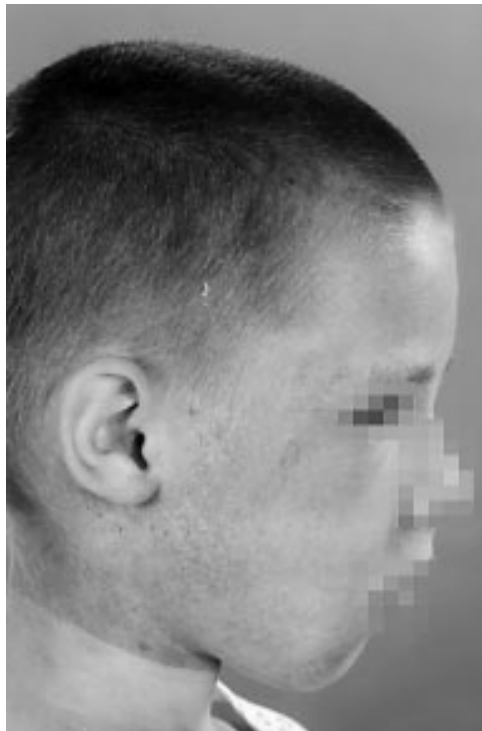

Figure 1 Case 2 showing the facial petechiae and subconjunctival haemorrhages, typical of ligature strangulation.

Accident and  
Emergency  
Department,  
Birmingham  
Children's Hospital,  
Steelhouse Lane,  
Birmingham B4 6NH,  
UK

Correspondence to:  
Dr Makwana, Senior House  
Officer  
(niten@makwana37.freeserve.  
co.uk)

neurological deficit may be reversed and despite initial findings victims should be aggressively resuscitated.<sup>5</sup>

Our cases illustrate the inherent dangers of the non-releasing plastic garden tie. Their design means that even small children are able to manipulate them but once tight find it impossible to effect release. These ties are widely available in do it yourself stores and garden centres and can also be used for tying electrical flexes. The products we examined did not display any warnings on the packaging. Easy release versions of this product exist and, for the majority of purposes, a non-releasing tie is perhaps not the most practical design and adjustable ones would be more suitable.

Except when non-release is essential for security reasons outside the domestic setting, for example, clinical waste, we would strongly advocate the use of the releasable versions and recommend that non-releasing ties display a clear warning on their packaging to keep them out of the reach of children.

- 1 Petruk J, Shields E, Cummings GE, *et al.* Accidental strangulation with clothing drawstrings. *Can Med Assoc J* 1996;155:1429–31.
- 2 Strauss RH, Thompson JE, Macasaet A. Accidental strangulation by a motor vehicle window. *Pediatr Emerg Care* 1997;13:346.
- 3 Byard RW, Beal SM, Simpson A, *et al.* Accidental infant death and stroller-prams. *Med J Austr* 1996;165:140–1.
- 4 Clarke MA, Feezko JD, Hawley DA, *et al.* Asphyxial deaths due to hanging in children. *J Forensic Sci* 1993;38:344–52.
- 5 Digeronimo RJ, Mayes TC. Near hanging injuries in childhood: a literature review and report of three cases. *Pediatr Emerg Care* 1994;10:150–6.

## Epidural abscess misdiagnosed as cholecystitis

F Lam, M Hynes

A 65 year old man presented to the accident and emergency department with a four week history of worsening pain in the right upper quadrant of his abdomen. There was no history of jaundice or change in appearance of his stools or urine. On admission, he was feverish with a temperature of 37.8°C and his abdomen was soft and non-tender. Blood tests revealed a neutrophilia of 16 with a raised C reactive protein at 180. Apart from an increased alkaline phosphatase of 160, the rest of the liver function tests were all within normal limits.

Ultrasound showed multiple gall stones with no evidence of biliary obstruction. A preliminary diagnosis of acute cholecystitis was made, and he was treated with intravenous antibiotics.

On the following day, he developed sudden onset flaccid paralysis of his right lower limb with acute urinary retention. Rectal examination revealed loss of contraction of the anal sphincter. Magnetic resonance imaging (see figs 1 and 2) confirmed the clinical diagnosis of cauda equina compression and at surgery, an epidural abscess was found compressing the spinal cord around T9/10. Laminectomy was performed to decompress the cord posteriorly and a costotransversectomy was also carried out to excise the ninth rib proximally allowing access to the abscess and its drainage. Instrumented posterior fusion of T6 to L1 was then performed.

Neurological symptoms in his lower limb improved considerably after a prolonged course of antibiotics and at three months he was able to stand with crutches.

This case illustrates several important learning points. Firstly, extra-abdominal pathology including those arising from the spine must be considered in the evaluation of a patient with

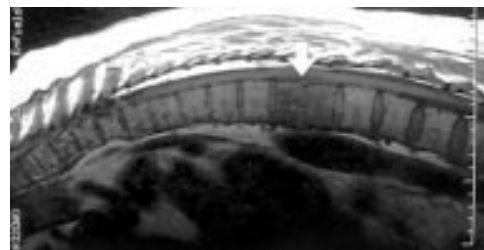


Figure 1 T1 weighted sequence of the thoracic spine showing abnormal high signalling involving T9 and T10 vertebral bodies, with abnormal material surrounding the cord in the spinal canal.

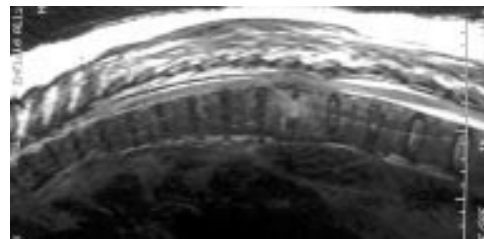


Figure 2 T2 weighted sequence of the thoracic spine showing abnormal high signalling involving T9 and T10 vertebral bodies, with abnormal material surrounding the cord in the spinal canal.

abdominal pain.<sup>1</sup> Secondly, liver function tests are not specific for liver disease, for example, alkaline phosphatase may also be raised in disease processes of bone, intestine and prostate. Finally, any patient presenting with acute neurological symptoms such as paralysis or a sensory level,<sup>2</sup> requires urgent specialist referral as a delay in diagnosis and treatment correlates with a poor prognosis.<sup>3</sup>

- 1 Tyson GW, Grant A, Strachan WE. Spinal epidural abscess presenting as acute abdomen in a child. *Br J Surg* 1979;66:3–4.
- 2 Verner EF, Musher DM. Spinal epidural abscess. *Med Clin North Am* 1985;69: 375–84.
- 3 Liem LK, Rigamonti D, Wolf AL, *et al.* Thoracic epidural abscess. *J Spinal Disord* 1994;7:449–54.

Chase Farm Hospital  
NHS Trust, London

Correspondence to:  
Mr Lam, 4 Middlefield,  
St John's Wood, London  
NW8 6NE, UK  
(mrflam@hotmail.com)

## Epidural abscess after dental extraction

B J Burgess

A 20 year old woman attended the accident and emergency department complaining of right sided neck pain three days after extraction of a wisdom tooth under general anaesthetic. The physical examination was consistent with a musculoskeletal neck sprain resulting from posture during the extraction and the patient was discharged with a soft cervical collar, non-steroidal analgesia and referred to physiotherapy. She returned three days later (six days after the original procedure) complaining of increased right sided neck pain and a sensation of numbness to the right arm. On examination she was found to have no neurological deficit but was found to be very tender over the C5 spinous process and marked tenderness was found on the right side of the neck. A radiograph was normal and further analgesia was prescribed.

The patient was referred to the on call orthopaedic team by the general practitioner three days later (nine days after the original presentation) with severe neck pain and having developed a paresis in her right arm and right leg. Later that day she developed a right sided paralysis in addition to a left sided paresis. The patient was sent for computed tomography and subsequent magnetic resonance imaging (MRI), which revealed an epidural abscess to the right side of C4/C5 vertebrae with an abnormal signal from within the cord at this level. This was also found to communicate with a large pre-vertebral collection (see fig 1). She was then urgently given intravenous antibiotics and referred to the on call neurosurgical team for drainage of the abscess and cord decompression. A total recovery resulted to the left arm and left leg. However, paralysis persisted to the right arm and right leg.

This case report is only the second recorded episode of an epidural abscess resulting from a dental extraction.<sup>1</sup> The diagnosis of an epidural abscess was made by MRI, which is currently regarded as gold standard.<sup>2</sup> The abscess is mainly caused by local and haematogenous spread. Blood cultures showed the presence of *Streptococcus milleri*, which is a known mouth

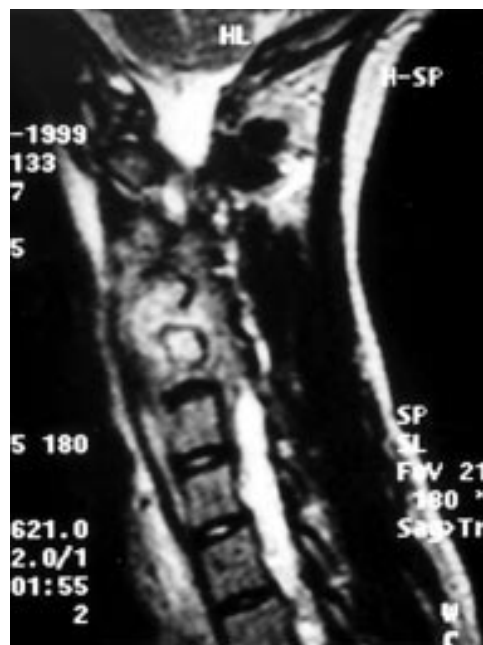

Figure 1 MRI revealing abscess around the 4th and 5th cervical vertebrae.

commensal and an uncommon cause of epidural abscess. Culture of the abscess after surgical decompression revealed *Corynebacteria*, which are non-specific for an oral cause. The difficulty with the differential diagnosis of acute torticollis has been previously eluded to<sup>3</sup> and the vital importance of early diagnosis leading to early treatment is well documented.<sup>4</sup> It also exemplifies a serious underlying disorder with an apparent innocuous cause.

- 1 Gelfand MS, Bakhtian BJ, Simmons BP. Spinal sepsis due to *Streptococcus milleri*: two cases and review. *Review of Infectious Diseases* 1991;13:559-63.
- 2 Okano K, Kondo H, Tsuchiya R, et al. Spinal epidural abscess associated with epidural catheterisation: report of a case and a review of the literature. *Jpn J Clin Oncol* 1999;29:49-52.
- 3 McKnight P, Friedman J. Torticollis due to cervical epidural abscess and osteomyelitis. *Neurology* 1992;42:696-7.
- 4 Simpson RK Jr, Azordegan PA, Sirbasku DM, et al. Rapid onset of quadriplegia from a paraspinous epidural abscess. *Spine* 1991;16:1002-5.

**Accident and  
Emergency  
Department,  
Broomfield Hospital,  
Court Road,  
Broomfield,  
Chelmsford, Essex  
CM1 7ET, UK**

Correspondence to:  
Mr Burgess  
(bburgess@doctors.org.uk)