

## EMERGENCY CASEBOOKS

## Pneumomediastinum secondary to dental extraction

T Sood, R Pullinger

A 45 year old man presented to the emergency department with a suspected "allergic reaction". He described facial and neck swelling, progressive inspiratory difficulty and pain on swallowing during the previous seven hours. On further

questioning he said that swelling had begun one hour after a prolonged dental extraction for a right lower molar tooth abscess. The procedure had entailed several local anaesthetic injections and the use of an air turbine drill. After the procedure he had started a course of oral penicillin V. He had no known allergies. On general examination, he was alert, well perfused and did not have afebrile. Swelling was noted in the submandibular region, the anterior part of the neck and the supraclavicular fossa (fig 1). His trachea was central and there was no clinical evidence of airway obstruction or ventilatory compromise. Pulse, blood pressure and heart sounds were normal. Subcutaneous crepitus was palpable over the neck, chest and right cheek. An antero-posterior chest radiograph showed extensive subcutaneous emphysema of the soft tissues of the chest and neck, with a pneumomediastinum (fig 2). Prophylactic intravenous cefuroxime and metronidazole were prescribed and the patient was admitted for observation under maxillofacial surgery. The patient's cervical and thoracic symptoms subsided and he remained afebrile and systemically well during the following three days and he was discharged.

Surgical emphysema is a recognised complication of dental treatment. It is important in the emergency department because almost 10% of cases are misdiagnosed as "allergic reactions", which may lead to errors in treatment.<sup>1</sup> Air may be introduced into the mediastinum via the fascial spaces of the neck using high speed air turbine drills or through an incision or empty socket after extraction.<sup>2</sup> Approximately one third of cases are secondary to extractions of the mandibular third molar. The differential diagnosis in patients presenting with a combination of face and neck swelling after dental procedures includes pneumothorax, expanding haematoma, infection in the fascial planes of the neck,

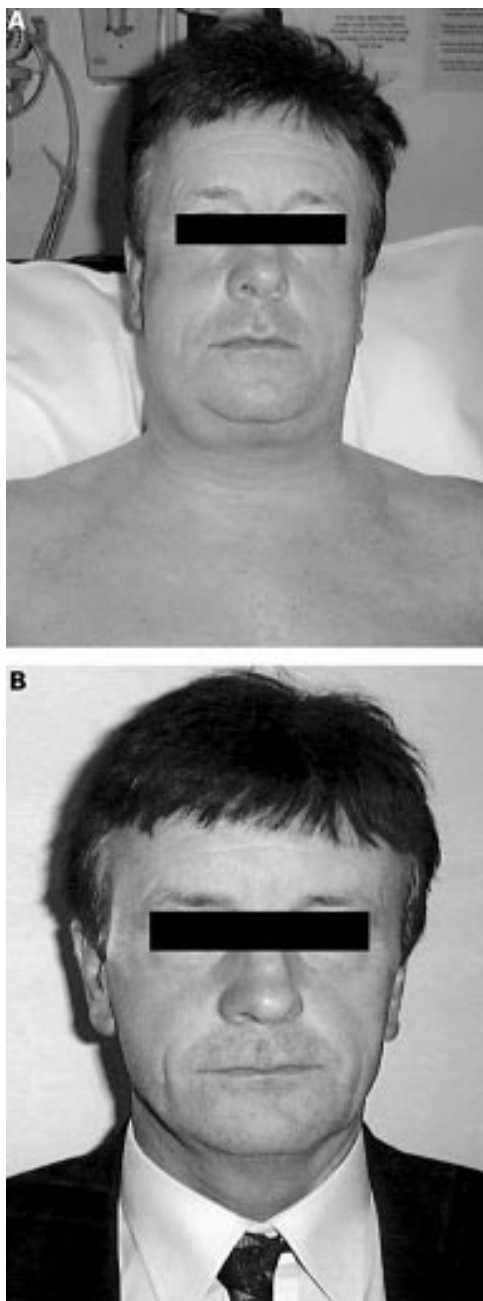


Figure 1 Facial appearance on presentation (top) and two months after discharge (bottom).

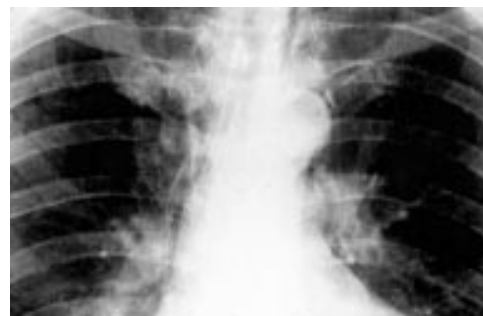

Figure 2 Chest radiograph showing pneumomediastinum.

Accident and  
Emergency  
Department, John  
Radcliffe Hospital,  
Oxford OX3 9DU, UK

Correspondence to:  
Dr Pullinger

anaphylaxis, local allergic reaction and angioneurotic oedema.

Complications of cervical emphysema and pneumomediastinum after oral surgery may include mediastinitis, cardiac tamponade and airway obstruction. In addition they may be associated with simple and tension pneumothorax and with pneumoperitoneum. Hence although the condition is not usually life threatening antibiotic prophylaxis is recommended and

patients are admitted for observation. The importance in the emergency department is that misdiagnosis as allergic reaction may lead to errors in treatment and adverse outcome.

- 1 Heyman SN, Babayof I. Emphysematous complications in dentistry 1960–1993 an illustrative case and review of the literature. *Quintessence International* 1995;**26**:535–43.
- 2 Kost M. Thoracic complications associated with the air turbine drill. *Journal of the American Association of Nurse Anaesthetists* 1996;**64**:288–92.

## Controlling epistaxis with an improvised device

V Moxham, C Reid

Anterior epistaxis accounts for 90% of all nosebleeds and its initial treatment requires the application of firm bilateral pressure on the nasal septum by compressing the cartilaginous part of the nose.<sup>1</sup> This is often done by a nurse if the patient is infirm or confused, which is an inefficient use of staff time. During the busy winter period emergency department physicians improvised with this simple device made from a wooden tongue depressor and elastic band (fig 1). The degree of pressure can be varied by adjusting the position of the elastic band. Swimmer's nose clips have been recommended for such use in this journal,<sup>2</sup> but our device provides a cheaper and more readily available alternative, which is disposable. This patient's epistaxis resolved after 10 minutes and required no further treatment.

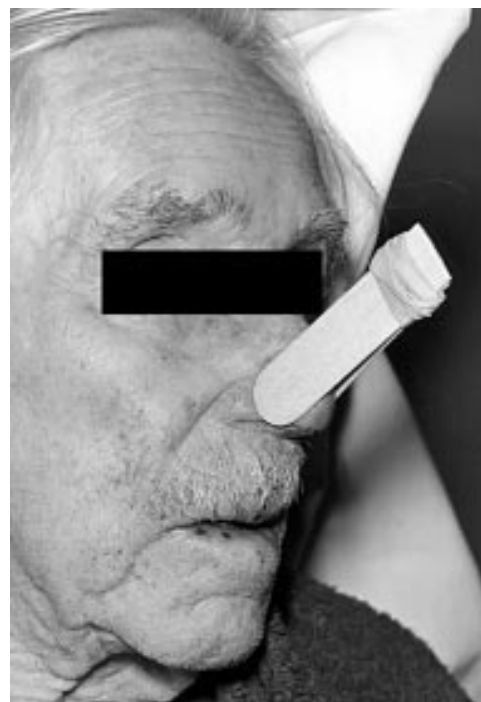

Figure 1

**Emergency  
Department, North  
Hampshire Hospital,  
Basingstoke, UK**  
V Moxham

**Intensive Care Unit,  
Queen Alexandra  
Hospital, Portsmouth,  
UK**  
C Reid

Correspondence to:  
Dr Reid, 36 Berkeley Close,  
Southampton SO15 2TR,  
UK

1 Rosen P, Barkin R, Danzl DF, *et al.* *Emergency medicine—concepts and clinical practice*. St Louis: Mosby, 1998:2725.

2 Turner P. The swimmer's nose clip in epistaxis. *J Accid Emerg Med* 1996;**13**:134.

## Cardiac air gun pellet injury

A J Hudson, J P Wyatt

An 11 year old boy was brought to accident and emergency by ambulance with a history of having been struck by a “ricochet” from a 0.22 inch air rifle fired from approximately 10 metres away by a friend. He had reportedly been clammy at scene, but on arrival at hospital was undistressed, with an oxygen saturation of 100% on oxygen, pulse 100 per minute with no ectopic beats and blood pressure 108/57 mm Hg. A 0.5 cm wound was noted on the right anterior chest wall at the 3rd intercostal space with no palpable underlying pellet.

A chest radiograph (fig 1) demonstrated a pellet within the mediastinum, with a lateral view (fig 2) confirming this to be intracardiac. Computed tomography was performed (fig 3), which showed a small haemothorax and haemopericardium with the pellet lodged between the atria. No pneumothorax was seen, although the track of the pellet through the right lung was noted. The ECG was normal.

He was transferred to the regional paediatric cardiothoracic unit where he underwent emergency surgery using cardiopulmonary bypass and atriotomy to remove the pellet. There was a tense haemopericardium and the pellet was found lodged within but not completely penetrating the intra-atrial septum.

He made a good postoperative recovery and was discharged home after six days. The power of legally available air weapons often appears to be underestimated. Weapons with muzzle velocities of up to 260 m/s are available without licence in the United Kingdom to those aged over 17 years, even although it has previously been estimated that the impact velocity of a

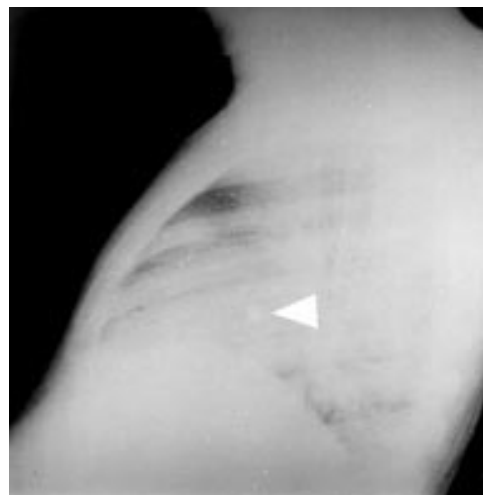


Figure 2 Lateral chest radiograph demonstrating pellet (indicated by arrow) within cardiac shadow.

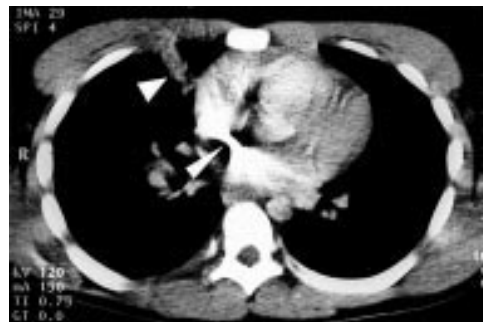

Figure 3 Thoracic computed tomography showing pellet within intra-atrial septum (narrow arrowhead) and missile track (broad arrowhead) through right lung.

0.22 pellet required to penetrate skin is only in the region of 75 m/s.<sup>1</sup> This case serves as a reminder of the potential of such weapons to cause life threatening injuries. Previous reports have illustrated the ability of air gun pellets to embolise from the heart as well as to cause arrhythmias<sup>2,3</sup> so consideration needs to be given to emergent removal with careful monitoring for potential complications.

### Contributors

Tony Hudson and Jonathan Wyatt were both responsible for the initial management of the patient and initiated the report. The literature search was jointly undertaken and Tony Hudson wrote the report. Tony Hudson is the guarantor for this paper.

Funding: none.

Conflicts of interest: none.

- 1 Di Maio VJM, Copeland AR, Besant-Matthews PE, *et al.* Minimal velocities necessary for perforation of skin by air-gun pellets and bullets. *J Forens Sci* 1982;27:894–8.
- 2 Wascher RA, Gwinn BC. Air rifle pellet injury to the heart with retrograde caval migration. *J Trauma* 1995;38:379–81.
- 3 Willemsen P, Kuo J, Azzu A. Dysrhythmia from an intrapericardial air gun pellet: a case report. *Eur J Cardiothorac Surg* 1996;10:461–2.

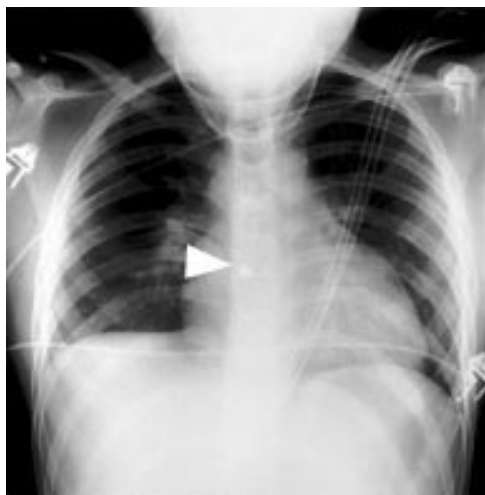

Figure 1 Anteroposterior chest radiograph with pellet (indicated by arrow) seen in mediastinum.

Accident and  
Emergency  
Department,  
Derriford Hospital,  
Plymouth, Devon  
PL6 8DH, UK  
A J Hudson

Accident and  
Emergency  
Department, Royal  
Cornwall Hospital,  
Truro, Cornwall  
J P Wyatt

Correspondence to:  
Dr Hudson  
(a.hudson@ukonline.co.uk)

## Rhabdomyolysis and polydipsic hyponatraemia

J Y S Ting

A 41 year old man was brought to the emergency department late in the afternoon with a reduced conscious level. He was found unresponsive in his bedroom, having last been seen well that morning. On presentation, his temperature was 36.1°C, pulse rate 90/min in sinus rhythm, blood pressure 140/70 mm Hg, respiratory rate 15/min and oxygen saturation 96% on room air. He had a blood sugar level of 7 mmol/l. The patient had a Glasgow Coma Scale score of 5 (E1 V1 M3) without external signs of a head injury. His pupils were sluggishly reactive, at 4 mm on the right and 2 mm on the left. He had a history of chronic schizophrenia treated with thioridazine, a previous head injury and was a heavy smoker.

His biochemistry on presentation showed serum sodium concentration of 113 mmol/l, potassium concentration 3.4 mmol/l, chloride concentration 76 (100–110 mmol/l), bicarbonate 25 (22–33 mmol/l) and a creatine kinase (CK) of 179 (<200 U/l). No measured serum osmolality was performed, but his calculated serum osmolality was 229 (270–290 mmol/kg). CK concentrations rose over the next 48 hours, peaking at 49 300 U/l. Serum toxicology screening for paracetamol and salicylates was negative. His ECG showed an old right bundle branch block with a corrected QT duration of 453 msec. Computed tomography of the head and lumbar puncture were normal. Urine biochemistry before treatment showed an osmolality of 158 mmol/kg, sodium 29 mmol/l, potassium 6.7 mmol/l, creatinine 3.1 mmol/l and urea 51 mmol/l. The provisional diagnoses were psychogenic polydipsia induced hyponatraemia, leading to cerebral dysfunction and rhabdomyolysis. Although CK subfraction analysis was not performed, the magnitude of the CK rise, normal serial ECGs and the presence of urinary myoglobin favoured rhabdomyolysis over myocardial injury.

The patient was endotracheally intubated for airway protection by a rapid sequence induction (RSI) method using midazolam, fentanyl and suxamethonium. Correction of hyponatraemia with intravenous 3% hypertonic saline to raise the serum sodium by 1 mmol/l per hour was accompanied by a large diuresis and a significant improvement in conscious level, permitting extubation after 48 hours. Despite having rhabdomyolysis, his urine output, serum creatinine and urea levels remained normal. Causes of skeletal muscle injury such as seizures, compartment syndrome, recent intramuscular injections, pressure areas, dystonic reaction and hyperthermic syndromes<sup>1</sup> were absent. Although the use of suxamethonium during RSI has been associated with rhabdomyolysis,<sup>2</sup> there was no evidence of sustained rigidity, masseteric spasm or a hyperthermic reaction at the time of intubation.

Psychogenic polydipsia is the behaviourally driven consumption of large volumes of fluids in the absence of an appropriate physiological stimulus, where underlying organic disease has been excluded.<sup>1</sup> It is seen in up to 17% of schizophrenic patients. Severe hyponatraemia (serum sodium < 120 mmol/l) develops in one quarter of these.<sup>3</sup> Proposed mechanisms include disturbed osmoregulation of fluid intake, excessive secretion of antidiuretic hormone (ADH) and renal hypersensitivity to ADH. An association exists between psychogenic polydipsia and the use of antipsychotics and antidepressants, traumatic head injury and heavy smoking,<sup>4</sup> which were present in our patient. Rhabdomyolysis attributable to hyponatraemia may be due to decreased extracellular sodium disturbing the function of membrane sodium-calcium pumps, which normally exchange an extracellular sodium ion for an intracellular calcium cation. A reduced concentration gradient for sodium entry into the muscle cell results in lessened outward shift of intracellular calcium. Intracellular incarceration of calcium activates enzymatic processes that leads to cell death.<sup>1</sup> An association between rhabdomyolysis in schizophrenia and severe polydipsic hyponatraemia has been described infrequently.<sup>1,3</sup> No other contribution to muscle damage aside from hyponatraemia was identified in this patient, and there was no personal and family history of neuropathy or myopathy. Patients with hyponatraemia related to psychogenic polydipsia are potentially at risk of developing rhabdomyolysis and myoglobinuric renal failure. Reported cases have involved serum sodium concentrations of less than 120 mmol/l. This case report provides further evidence that patients with severe hyponatraemia associated with psychogenic polydipsia should have CK concentrations monitored to detect rhabdomyolysis, even in the absence of other recognised causes of muscle injury. More importantly in the emergency department, hyponatraemia induced cerebral dysfunction should be considered in any patient with a previous psychiatric history presenting with an altered conscious level, and the serum sodium level should be measured urgently.

I wish to thank Dr D Cook and Associate Professor A F T Brown for critically reviewing the manuscript.

Department of  
Emergency Medicine,  
Princess Alexandra  
Hospital,  
Woolloongabba,  
Brisbane 4102,  
Queensland, Australia

Correspondence to:  
Dr Ting  
(jyting@mailbox.uq.edu.au)

- 1 Korzets A, Ori Y, Floro S, *et al.* Severe hyponatremia after water intoxication: a potential cause of rhabdomyolysis. *Am J Med Sci* 1996;312:92–4.
- 2 Ryan JF, Kagen LJ, Hyman AI. Myoglobinemia after a single dose of succinylcholine. *N Engl J Med* 1971;285:824–7.
- 3 Rizzeri DA. Rhabdomyolysis after correction of hyponatremia due to psychogenic polydipsia. *Mayo Clin Proc* 1995;70:473–6.
- 4 Siegler EL, Tamres D, Berlin JA, *et al.* Risk factors for the development of hyponatremia in psychiatric inpatients. *Arch Intern Med* 1995;155:953–7.



# The Ottawa Ankle Rules and missed fractures of the talus

N P Warren, J D Knottenbelt

Less than a decade ago, clinical epidemiologist Ian Stiell, working with emergency department physicians, formulated the Ottawa Ankle Rules.<sup>1</sup> The local climate was highly conducive to slips and falls. The rules are intended to guide clinical decisions about the efficient use of radiography in the diagnosis of malleolar zone fractures and midfoot zone fractures, minimising expenditure, unnecessary exposure to ionising radiation and emergency department waiting times for patients. In summary, they state that radiographic examination is not required unless, in the first instance, there is tenderness at the posterior edge or tip of the medial or lateral malleolus, or in the latter instance over the navicular bone or base of the fifth metatarsal. The rules leave fractures of the talus as an intrinsic “blind spot”, and seem to assume that fractures of the cuboid bone are innocuous, in the two distinct “zones” respectively. A later article<sup>2</sup> encapsulated Ian Stiell’s motivation in drawing up the Ottawa Ankle Rules (OAR). The OAR project had demonstrated that more than 95% of patients with ankle injuries had radiographic examinations, but that 85% of the radiographs showed no fractures. A group of Ottawa emergency physicians developed the two rules described above, and their application reduced radiographic examinations by 28% for the ankle, and 14% for the foot, (that is, by 2/7 and 1/7). Inability to bear weight either initially, or on examination, requires radiography.

## Case report

A 31 year old man was parachuting when his main parachute failed to open. Using a reserve parachute, he landed awkwardly on an aircraft’s wing on his left foot. He was immediately aware of pain in his left ankle, but was able to pack his parachute and travel home. He took analgesia overnight, and presented to our accident and emergency department the next day.

The patient had sustained an “acute ankle injury” as defined by OAR. On examination he had an antalgic gait, so by definition he was weight bearing, and the ankle was not radiographed. He was given a compression bandage, and advised to rest and elevate the limb. On the fifth day after the injury he returned, still complaining of pain in the ankle. Once again, the malleoli were non-tender, and he was

discharged. After two weeks, a third consultation at a different hospital resulted in an ankle radiograph that showed a fracture of the dome of the talus.

## Discussion

Continued evaluation of the OAR in North America by emergency department physicians has led to confirmation of the original thesis, with sensitivities calculated at 100%.<sup>3,4</sup> A comparatively small study of 71 children<sup>5</sup> has suggested that the rules can be extended to paediatric patients.

The only major dissenting paper comes from outside that continent.<sup>6</sup> In New Zealand a prospective, multicentre trial of 350 adult patients presenting with acute ankle injuries correlating with the OAR gave the following results. There were 75 fractures in 350 patients, five of which would have been missed by the clinical decision rule. These included one fracture of the talus, and one of the cuboid. The study concluded that the sensitivity of the rule was 93%, and the false negative rate 14%, which was “unacceptable for application in emergency departments in New Zealand.”

Talar fractures are potentially very serious, requiring a prolonged period of negative weight bearing, and carrying a significant risk of avascular necrosis. While they are commoner in high velocity injuries, such as falls from a height or motor vehicle accidents, they can also occur during forced hyperextension injuries in simple stumbles and falls. The authors recommend that such risk is best managed by excluding all high velocity incidents (however trivial they may seem at first) and all forced hyperextension injuries from inclusion, or triage, into the Ottawa Ankle Rules.

Funding: none.

Conflicts of interest: none.

- 1 Stiell IG, Greenberg, GH, McKnight RD, *et al.* A study to develop clinical decision rules for the use of radiography in acute ankle injuries. *Ann Emerg Med* 1992;21:384–90.
- 2 Stiell I. The Ottawa ankle rule project. *Can Fam Physician* 1996;42:478–80.
- 3 Stiell IG, Greenberg GH, McKnight RD, *et al.* Decision rules for the use of radiography in acute ankle injuries. *JAMA* 1993;269:1127–32.
- 4 Stiell IG, McKnight RD, Greenberg GH, *et al.* Implementation of the Ottawa Ankle Rules. *JAMA* 1994;271:827–2.
- 5 Chande VT. Decision rules for current roentgenography of children with acute ankle injuries. *Arch Pediatr Adolesc Med* 1995;149:255–8.
- 6 Kelly AM, Richards D, Kerr L, *et al.* Failed validation of a clinical decision rule for the use of radiography in acute ankle injury. *N Z Med J* 1994;107:363.

**Accident and  
Emergency  
Department,  
Northwick Park  
Hospital, Harrow,  
Middlesex HA1 3UJ,  
UK**

Correspondence to:  
Mr Warren  
(Ripperana@btinternet.com)

# Subcutaneous emphysema of upper limb

M De, J Stevenson

## Abstract

**A case is reported of subcutaneous emphysema involving upper limb resulting from a trivial laceration to the elbow. Gas in the soft tissues after the injury can be caused by infection with a gas forming organism or by a variety of non-infective causes. It is hypothesised that this minor skin wound has acted like a ball-valve mechanism leading to air being trapped in the soft tissue.**

(*Emerg Med J* 2001;18:522)

Keywords: subcutaneous emphysema; upper limb

## Case report

A 73 year old woman presented to accident and emergency (A&E) with history of fall and sustaining a trivial laceration to the extensor aspect of the left olecranon. The wound was cleaned and closed with adhesive skin strips. Radiography showed no abnormality. She was discharged. She was referred back to A&E the following day by her general practitioner because of extensive swelling on the dorsum of the hand and forearm.

On examination she had surgical emphysema extending from the tips of the fingers to the mid-arm. There was no clinical evidence of infection in the arm. Radiography of her arm and forearm confirmed extensive surgical emphysema in the superficial tissues extending from mid-humerous to the hand (fig 1). The chest radiograph showed no abnormality. Wound swabs and blood cultures identified no pathogens. The swelling gradually resolved and had completely settled by final review, seven days after the injury.

## Discussion

Subcutaneous emphysema affecting an isolated limb is rare. It is important to differentiate between gas in the soft tissues secondary to infection and other causes of subcutaneous emphysema. Infection with gas forming organisms usually takes around 18 hours to produce clinically detectable crepitus. Subcutaneous emphysema from a non-infective cause is normally present much earlier. Signs of infection such as erythema, fever, systemic upset, and increased WBC count are not associated with non-infective causes. The presence of gas within the muscle bellies, as well as in the soft tissue, is suggestive of a deep seated infection with gas forming organisms.<sup>1</sup>

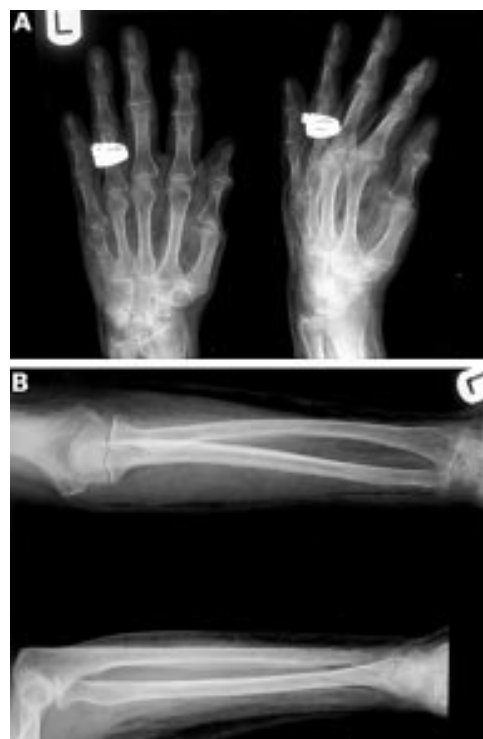

Figure 1 Subcutaneous emphysema of hand (A) and forearm (B).

Treatment for serious infections resulting from gas forming organisms include high dose antibiotics, wound exploration and extensive wound debridement.<sup>2</sup>

Subcutaneous emphysema in an isolated limb has been described secondary to a number of causes, including after perforation of appendix, migration of fracture fixation device, irrigation of wound with hydrogen peroxide, air gun injury, dental extraction.<sup>3</sup>

In the case described, the history, the lack of clinical signs and the laboratory investigations all mitigate against infection being the cause. It has previously been reported that air can be trapped in tissues deep to relatively small wounds and it is hypothesised that this results from air being sucked into the wound, secondary to the movement of the limb.<sup>3</sup>

- 1 Filler RM, Grimscom NT, Pappas A. Post traumatic crepitation falsely suggesting gas gangrene. *N Engl J Med* 1968;278:756-61.
- 2 Green RJ, Dafoe DC, Raffin TA. Necrotising fasciitis. *Chest* 1996;110:219-29.
- 3 Stevenson J. Sucking wounds of the limbs. *Injury* 1995;26:151-3.

Department of  
Accident and  
Emergency,  
Crosshouse Hospital,  
Kilmarnock, UK

Correspondence to:  
Dr De, 45 Clos George  
Morgan, Morriston, Swansea  
SA6 6LZ, UK  
(mrigankade@hotmail.com)