

CASE REPORTS

A solution to the non-deflating balloon of a suprapubic catheter

T S Huseyin, S M Moalypour

Emerg Med J 2002;**19**:354

A case report describes the successful aspiration of a non-deflating suprapubic urinary catheter by passing a cannula directly down the fistula tract. It is a relatively safe and simple procedure that can be performed in an accident and emergency department.

Replacing a long term suprapubic urinary catheter in accident and emergency is not uncommon. They are often in patients with disabling diagnoses. On occasion the balloon will not deflate. This case report highlights a technique used to deflate the balloon after all reasonable avenues had been exhausted.

CASE REPORT

A bedbound 62 year old woman attended our department. She had multiple sclerosis and her long term suprapubic catheter was not draining. The catheter balloon would not deflate. The valve mechanism was cut off and a fine guidewire was passed down the balloon's insufflation passage, but the balloon would still not deflate. The following action was taken. Gentle traction was applied to the catheter, which brought the balloon close to the internal opening of the fistula tract. An intravenous cannula 18G (Green Venflon) was taken and its hub and cap were removed. A 20 ml empty syringe was attached to the sheathed needle. The sheath was advanced over the cannula needle to hide its point. This blunt end was slowly passed down the fistula close to the catheter wall until resistance was met (presumed to be the balloon). The needle tip was advanced through the sheath and the syringe started to automatically fill with the balloon fluid. Once all the fluid was aspirated the catheter was easily removed. The balloon was intact.

DISCUSSION

Many methods have been described for overcoming non-deflating urinary catheter balloons. Once techniques to dislodge balloon port obstruction have failed, balloon rupture is the next step. Over distension and chemical rupture can be used¹ but tends to leave balloon debris. Percutaneous needle puncture has been used² but is invasive. Transurethral deflation has been successfully described³ using a smaller 23G needle⁴ and a 20G angiographic catheter.¹ Our technique used a trans-fistula approach for the first time and used a larger needle. Figure 1 shows that a 18G needle does not burst the balloon if approached near the base of the balloon. Experimentally this was repeated on a total of 15 Folsyl (silicone

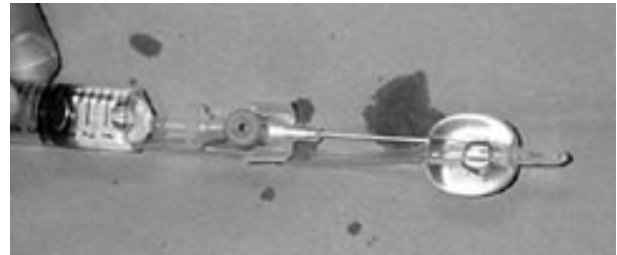

Figure 1 Successful aspiration from the base of the balloon. Note the balloon is still intact. The length of the cannula allows complete passage down the fistula tract.

Foley) catheters sizes ranging from 12 to 16 Ch gauge. All were successfully aspirated without bursting the balloon. Complications of this procedure may include local injury by a poorly guided unsheathed needle, and balloon fragmentation.

CONCLUSION

Trans-fistula peri-catheter aspiration of a non-deflating suprapubic urinary catheter balloon is a relatively simple procedure to perform in a busy accident and emergency department. It is reproducible and has few potential adverse events.

Contributors

Mr T S Huseyin performed the procedure described, searched the literature, and wrote the paper. Mr S M Moalypour supervised the procedure, assisted in writing the paper, and is the guarantor.

Authors' affiliations

T S Huseyin, S M Moalypour, Accident and Emergency, Kingston Hospital, Surrey, UK

Correspondence to: Mr T S Huseyin, 42 Beechcroft Avenue, New Malden, Surrey KT3 3EE, UK; turansev@btinternet.com

Accepted for publication 12 December 2001

REFERENCES

- 1 Carr LK. An alternative to manage a nondeflating Foley catheter in women. *J Urol* 1995;**153**:716-17.
- 2 Higgins WL, Mace AH. Puncture of a nondeflatable Foley balloon using ultrasound guidance. *Radiology* 1984;**151**:801.
- 3 Davies BW, Thomas DG. Management of the non-deflating Foley catheters in women. *Br J Urol* 1994;**74**:117.
- 4 German K, Crossan I. A method to avoid bursting the blocked catheter balloon in the female patient. *Br J Urol* 1995;**76**:657-8.

Delayed asystolic cardiac arrest after diltiazem overdose; resuscitation with high dose intravenous calcium

G K Isbister

Emerg Med J 2002;**19**:355–357

A 51 year old man took a mixed overdose including 1.8–3.6 g of diltiazem, paracetamol, aspirin, isosorbide nitrate, and alcohol. He initially presented to hospital after six hours with mild hypotension and was treated with activated charcoal and intravenous fluids. Eighteen hours after the overdose he had two generalised tonic-clonic seizures. The patient remained unresponsive with junctional bradycardia, unrecordable blood pressure, and then became asystolic. He was resuscitated with high dose (13.5 g) intravenous calcium and adrenaline (epinephrine). He required inotropic support and temporary pacing over the next 48 hours. This case suggests there is a role for aggressive high dose intravenous calcium therapy in severe diltiazem overdose, particularly with the onset of asystole. It should be considered early in cases of cardiac arrest after diltiazem overdose. The case also highlights the problems with delayed toxicity when whole bowel irrigation is not administered.

Calcium channel blocker (CCB) overdose is relatively uncommon, but has a higher mortality and morbidity compared with other drug overdoses.¹ Diltiazem overdose has been reported previously, mainly as case reports^{2–8} and in a few case series.^{1,9} In particular, overdose of its slow release formulations may lead to severe toxicity if appropriate decontamination is not started.³ There remains considerable controversy about the treatment of severe CCB overdose, particularly with the use of intravenous calcium.^{10–13}

Here is reported an overdose of slow release diltiazem causing delayed asystolic arrest, and successful resuscitation with rapidly administered, high dose calcium gluconate.

CASE REPORT

A 51 year old white man took a mixed overdose comprising diltiazem 1.8–3.6 g (slow release preparation), paracetamol, aspirin, isosorbide nitrate, and alcohol. He presented to hospital six hours after the overdose complaining of nausea, vomiting, weakness, and lethargy. He had a past history of ectopic coronary arteries and cardiomyopathy, asthma, bipolar mood disorder, and alcohol misuse.

Examination on presentation revealed: heart rate (HR) 80 bpm and blood pressure (BP) 90/40 mm Hg. He was orientated and cooperative. Cardiovascular, respiratory, and neurological examinations were normal. An electrocardiograph (ECG) showed sinus rhythm. He was treated with 50 g activated charcoal, 3 litres of intravenous crystalloid solution, and 1 g of calcium gluconate. BP improved to 100/50. Salicylate and paracetamol concentrations were not in the toxic range. Whole bowel irrigation was not undertaken. Over the next 12 hours he remained alert and well, with no significant decrease in BP or HR.

Eighteen hours after the overdose, he had two generalised tonic-clonic seizures and remained unresponsive with a junctional bradycardia, HR 43, BP unrecordable. He then became

asystolic with no palpable pulses. He was intubated and ventilated while cardiopulmonary resuscitation was started. Over a period of 12 minutes he was given 10 g calcium gluconate as 1 g boluses and 9 mg of adrenaline (epinephrine). He responded with HR 54 (junctional bradycardia) and BP 137/80 mm Hg. Five minutes later, he had a second asystolic cardiac arrest and was given a further 2.5 g calcium gluconate and 1 mg adrenaline (total of 12.5 g of calcium gluconate given over 28 minutes). An external pacemaker was attached, and an adrenaline infusion (6 mg/100 ml at 5 ml/h) and a calcium gluconate infusion of 1 g in 100 ml/h were started.

After one hour, calcium was stopped but high dose noradrenaline (norepinephrine) and dobutamine were required to maintain blood pressure, and a temporary pacing wire was necessary to maintain rhythm. There was no response in haemodynamic parameters to glucagon. Severe metabolic acidosis (pH 6.83 base excess 26) and acute renal failure were treated with a bicarbonate infusion and 24 hours of continuous veno-venous haemofiltration. Insulin was required for hyperglycaemic control.

Over 48 hours inotropes were weaned, the acidosis resolved, renal function improved, and pacing was stopped (table 1 presents serial blood parameters). The only other complication was pulmonary oedema. This was initially treated as aspiration pneumonia with antibiotics and oxygen therapy, but radiographical findings were more consistent with pulmonary oedema. The patient was discharged from intensive care on day 5 and discharged himself against medical advice eight days after presentation. On subsequent attendances to the emergency department, he had a normal neurological examination, normal chest radiograph, ECG, and creatinine.

DISCUSSION

This case illustrates the potentially life threatening effects of slow release diltiazem overdose and the problems with delayed toxicity if decontamination is incomplete or not undertaken. The clinical effects in the patient described were consistent with CCB overdose. The spectrum of CCB toxicity includes hypotension (combination of vasodilatation and negative inotropic effects), bradycardia, conduction abnormalities (sinus node depression and AV conduction block), pulmonary oedema, metabolic effects (hyperglycaemia and metabolic acidosis), and neurological symptoms (lethargy, coma, seizures).^{1–7,9,14} The pharmacokinetics and mechanism of toxicity have been reviewed previously.^{5,14}

Whole bowel irrigation is being used increasingly in poisoning with slow release formulations.¹⁵ Similar to most treatment modalities in clinical toxicology, the evidence for the use of whole bowel irrigation in slow release CCB overdose is based on case reports alone. There is a reported case of two

Abbreviations: CCB, calcium channel blocker; BP, blood pressure; HR, heart rate

Table 1 Serial biochemical parameters including corrected serum calcium concentrations; 13.5 g calcium gluconate given 18 hours after the overdose

Time after overdose (h)	7	13	19 ½	28	58	86	112
Creatinine (µmol/l) (Range: 50–120 µmol/l)	112	252	174	201	405	351	268
Corrected serum calcium (mmol/l) (range: 2.20–2.60 mmol/l)	2.23	2.51	3.36	2.45	–	2.16	2.28
pH (7.35–7.45)	7.45	–	6.83	7.40	7.42	7.37	–
Base excess	–6.7	–	–26	–1.7	3.3	3.3	–
Blood glucose (glucometer)	6.5	–	18.1	11.1	7.8	9.6	–

patients who took similar doses of slow release verapamil, where one patient had whole bowel irrigation and developed only minimal toxicity, while the other patient, who did not receive whole bowel irrigation, developed severe toxicity.¹⁶ Although whole bowel irrigation has not been proved effective in controlled trials of slow release CCB overdoses, the seriousness of this poisoning and the effectiveness of whole bowel irrigation in previous case reports,¹⁶ make it an important consideration for decontamination, until clinical trials are undertaken.

The patient had two generalised tonic-clonic seizures minutes before the asystolic arrest. Seizures have been reported uncommonly with calcium channel overdoses.¹⁷ Quezado *et al* also reported a generalised seizure before asystole in a verapamil overdose.¹⁷ It may be hypothesised that the seizures precipitated asystole by causing acidosis and increasing the amount of ionised drug available for channel blockade.

There is disagreement about the use of intravenous calcium in CCB overdose.^{10–13} Recently published Toxicologic-Oriented Advanced Cardiac Life Support guidelines recommend the use of 1 g–3 g of intravenous calcium as a slow intravenous bolus, only after shock is refractory to other treatments.¹² However, there is some evidence that intravenous calcium is a useful first line therapy.^{16, 18} There is one report of an asystolic arrest after diltiazem overdose responding to 2 g of calcium gluconate alone.⁶

In situations of severe haemodynamic compromise, such as asystole, larger doses may be beneficial.^{13, 16} In the case reported here, much larger doses were administered rapidly, and then repeated after a second episode of asystole, with good response. High dose intravenous calcium, that is, greater than 3 g, has been reported in a number of cases of CCB overdose,^{13, 16, 18} but not previously in diltiazem overdose.⁵

In contrast, in cases of CCB poisoning reporting failure of intravenous calcium, the dose was 1 g–3 g.^{3, 4, 8} Failure of high dose intravenous calcium seems to occur less commonly,¹⁹ suggesting that a higher dose may be more appropriate in severe poisoning. Proponents of high dose calcium suggest that in cases of failure, the overdose is often refractory to all treatment.¹ No serious side effects have been reported despite transient high serum calcium (up to 4.8 mmol/l).^{13, 16, 18} Multi-centre clinical trials will be required to test the hypothesis that high dose intravenous calcium is beneficial in CCB poisoning because it is an uncommon poisoning.

Although the severe delayed toxicity in this case most probably resulted from inadequate decontamination, his pre-existing cardiac disease may have exacerbated it. However, good outcomes with severe CCB toxicity have been reported in patients with a history of coronary artery disease,^{6, 8} and poor outcomes have been reported in otherwise healthy persons.^{16, 20} It is unclear if continuing the calcium infusion postcardiac arrest would have reduced the amount and time inotropes were required. Previous case reports have suggested that continuing a calcium infusion is beneficial,^{7, 16, 18} but a controlled trial would be required to test this hypothesis.

This case suggests there is a role for aggressive intravenous calcium therapy in severe diltiazem (and other CCB) overdose,

particularly with the onset of asystole. It should be considered early in cases of cardiac arrest after CCB overdose. The case also highlights the problems with delayed toxicity when whole bowel irrigation is not administered.

ACKNOWLEDGEMENTS

Thanks to Dr Patricia McGettigan and Ms Corrine Balit for reading the manuscript. Thank you to Associate Professors Ian Whyte and Andrew Dawson for their comments on the manuscript.

Contributors

Geoffrey Isbister attended the patient in the emergency department, wrote and revised all manuscripts and will be guarantor for the paper. Ian Whyte and Andrew Dawson discussed the idea and focus of the case report with the author, but did not read the manuscript. Patricia McGettigan and Corrine Balit read and commented on the manuscript.

Author's affiliations

G K Isbister, Discipline of Clinical Pharmacology, University of Newcastle and Department of Clinical Toxicology and Pharmacology, Newcastle Mater Misericordiae Hospital, Australia

Correspondence to: Dr G K Isbister, Discipline of Clinical Pharmacology, Level 5, Clinical Sciences Building, Newcastle Mater Hospital, Edith Street, Waratah, NSW 2298, Australia; gsbite@bigpond.com

Accepted for publication 31 January 2002

REFERENCES

- Howarth DM, Dawson AH, Smith AJ, *et al*. Calcium channel blocking drug overdose: An Australian series. *Hum Exp Toxicol* 1994;**13**:161–6.
- Morimoto S, Sasaki S, Kiyama M, *et al*. Sustained-release diltiazem overdose. *J Hum Hypertens* 1999;**13**:643–4.
- Williamson KM, Dunham GD. Plasma concentrations of diltiazem and desacetyldiltiazem in an overdose situation. *Ann Pharmacother* 1996;**30**:608–11.
- Proano L, Chiang WK, Wang RY. Calcium channel blocker overdose. *Am J Emerg Med* 1995;**13**:444–50.
- Erickson FC, Ling LJ, Grande GA, *et al*. Diltiazem overdose: case report and review. *J Emerg Med* 1991;**9**:357–66.
- Connolly DL, Nettleton MA, Bastow MD. Massive diltiazem overdose. *Am J Cardiol* 1993;**72**:742–3.
- Luomanmaki K, Tiula E, Kivisto KT, *et al*. Pharmacokinetics of diltiazem in massive overdose. *Ther Drug Monit* 1997;**19**:240–2.
- Ferner RE, Odemuyiwa O, Field AB, *et al*. Pharmacokinetics and toxic effects of diltiazem in massive overdose. *Hum Toxicol* 1989;**8**:497–9.
- Ramoska EA, Spiller HA, Winter M, *et al*. A one-year evaluation of calcium channel blocker overdoses: toxicity and treatment. *Ann Emerg Med* 1993;**22**:196–200.
- Kenny J. Treating overdose with calcium channel blockers. *BMJ* 1994;**308**:992–3.
- Buckley NA, Whyte IM, Dawson AH. Overdose with calcium channel blockers. *BMJ* 1994;**308**:1639.
- Albertson TE, Dawson A, De Latorre F, *et al*. TOX-ACLS: Toxicologic-oriented advanced cardiac life support. *Ann Emerg Med* 2001;**37** (4 Pt 2):S78–90.
- Luscher TF, Noll G, Sturmer T, *et al*. Calcium gluconate in severe verapamil intoxication. *N Engl J Med* 1994;**330**:718–20.
- Pearigen PD, Benowitz NL. Poisoning due to calcium antagonists. Experience with verapamil, diltiazem and nifedipine. *Drug Saf* 1991;**6**:408–30.
- Tenenbein M. Position statement: whole bowel irrigation. American Academy of Clinical Toxicology; European Association of Poisons Centres and Clinical Toxicologists. *J Toxicol Clin Toxicol* 1997;**35**:753–62.

- 16 **Buckley N**, Dawson AH, Howarth D, *et al*. Slow-release verapamil poisoning. Use of polyethylene glycol whole-bowel lavage and high-dose calcium. *Med J Aust* 1993;**158**:202-4.
- 17 **Quezado Z**, Lippmann M, Wertheimer J. Severe cardiac, respiratory, and metabolic complications of massive verapamil overdose. *Crit Care Med* 1991;**19**:436-8.
- 18 **Haddad LM**. Resuscitation after nifedipine overdose exclusively with intravenous calcium chloride. *Am J Emerg Med* 1996;**14**:602-3.
- 19 **Crump BJ**, Holt DW, Vale JA. Lack of response to intravenous calcium in severe verapamil poisoning. *Lancet* 1982;ii:939-40.
- 20 **Roper TA**, Sykes R, Gray C. Fatal diltiazem overdose: report of four cases and review of the literature. *Postgrad Med J* 1993;**69**:474-6.

An unusual case of paralytic ileus after jellyfish envenomation

R Ponampalam

Emerg Med J 2002;**19**:357-358

A 31 year old tourist presented with paralytic ileus after jellyfish sting. This unusual presentation after jellyfish envenomation is reported and the literature reviewed for jellyfish envenomation syndromes.

Jellyfish venom contains a mixture of toxic and antigenic polypeptides, which are species specific. The manifestations of jellyfish envenomation in humans have been noted to include allergic reactions, cardiac syndromes presenting with cardiac arrest and heart failure, and neurological syndromes. Although a wide variety of neurological manifestations have been reported, no reports of paralytic ileus from jelly fish envenomations have been reported.

A case report of a 31 year old man stung by a jellyfish and who subsequently presented with paralytic ileus is discussed.

CASE REPORT

A 31 year old man was on a beach in Medan, Sumatra, when he came across a large jelly-like mass floating in the water. He picked it up and handled it for a minute or two before feeling a sharp pain on his left forearm. He immediately dropped the unknown creature and noticed a linear urticarial lesion on the left forearm (fig 1). This corresponded with a jellyfish sting reaction. Within half an hour he developed generalised malaise, weakness, lethargy, and joint pains followed by a sensation of abdominal bloatedness. He was treated at a local hospital but decided to seek further treatment in Singapore. The patient presented at the Department of Emergency Medicine at Singapore General Hospital 24 hours after envenomation. He complained of persistence of his original symptoms and was beginning to develop abdominal distension, vomiting, and had no urge to move his bowels since the incident. Examination revealed a lethargic looking patient with linear urticarial lesions on his left forearm. Vital signs were stable and neurological examination was essentially normal. Pupils were 4 mm, equal and reactive bilaterally. Abdominal distension was noted with absent bowel sounds. No abdominal tenderness was elicited and per rectal examination revealed soft brown stools. A clinical diagnosis of paralytic ileus (adynamic intestinal obstruction) was made. Abdominal radiographs showed distended small and large bowel loops with multiple fluid levels confirming the clinical suspicion. Full blood count, serum electrolytes, amylase, cardiac enzymes, liver function tests, and coagulation profile were all normal except for mildly increased total white with polymorphonuclear leucocytosis of 81.6%. Electrocardiogram showed normal sinus rhythm with rate of 75 beats/minute. A surgical consul-

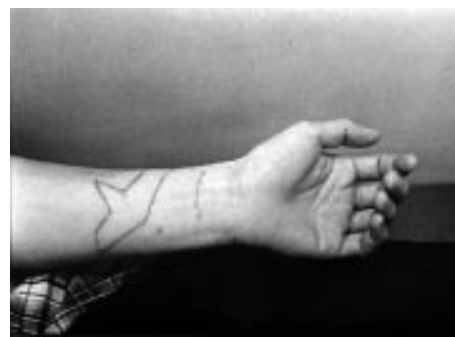

Figure 1 Linear urticarial lesion on the forearm typical of jellyfish sting.

tation was made and patient was treated conservatively with intravenous infusion and suction. The patient was admitted and treatment continued for four days before symptoms resolved and patient was able to move his bowels again. He was discharged on the fourth day and returned for review a week later when he was noted to be well and discharged without any further follow up.

DISCUSSION

Jellyfish belong to the phylum called cnidarians or coelenterates. The unique feature of these organisms is the presence of millions of nematocysts (or stinging cells) on their tentacles, which surround the venom glands. These act as the plunger of the hypodermic syringe discharging the contents of the venom gland when activated either by contact or pressure. The organism has no control over the discharge of the nematocyst and hence, envenomation can occur when people brush against the tentacles even of dead jellyfish.

There are several species of jellyfish that have been known to produce envenomations in humans. These include the *Chironex fleckeri* (box jellyfish or sea wasp), *Carukia barnesi*, and *Physalia physalis* (Portuguese man of war). The Chironex is a large jellyfish, which has 50 to 60 tentacles each five to six feet long. Fatalities have been reported with envenomation with this species. This species tends to be found around the coastal waters of Australia and because of its lethal stings the emergency ambulance services carry the antivenom and have protocols for administering it in the prehospital setting. The Portuguese man of war jellyfish is found in tropical waters and floats on the water surface. It tends to cause severe local urticarial lesions and joint pain on being stung. *Carukia barnesi* is found off the coastal waters of Northern Australia. Its bell

reaches 2 cm diameter when fully grown. It has been noted to cause the Irukanji Syndrome manifesting with sudden cardiac arrest or heart failure.

Human reactions to jellyfish envenomation can be fatal, local, or systemic.¹

Local reactions are usually linear and papular or urticarial skin lesions. These are attributable to kinin-like mediators in the venom. These may progress to erythematous, vesicular, haemorrhagic, necrotising, or ulcerative lesions. Localised hyperhidrosis, lymphadenopathy, fat atrophy, vasospasm with limb necrosis and gangrene have been reported. Persistent rubbing can produce lichenification.

A variety of systemic reactions have been reported involving the cardiac, respiratory, and neurological systems. Neurological manifestations include dysautonomia, peripheral sensory neuropathies, mononeuritis multiplex, central or peripheral motor paralysis, ophthalmological symptoms, neuropsychological derangements, and cardiomyopathies.²

Parasympathetic dysautonomia resulting from jellyfish sting to the thighs of a Chinese fisherman was reported in 1984.³ This patient presented with abdominal distension, retention of urine, constipation, absence of lacrimation, and failure of erection. This was possibly the result of a selective anti-muscarinic effect of the jellyfish venom. In our case, the patient presented with isolated paralytic ileus with no other manifestations of parasympathetic dysfunction. Occasional reports of cases of jellyfish sting presenting with isolated neurological deficits are noted in the past. One such case had prolonged blurring of vision after jellyfish sting, which persisted for a week.⁴ The exact mechanism of these isolated effects is yet to be discovered.

There are a wide variety of manifestations after jellyfish envenomation. The pathological effects are attributable to a combination of toxic and allergic mechanisms. The actual

pathogenesis of human injury from jellyfish venom is yet to be elucidated. Allergic effects are managed in a similar way as any other anaphylaxis. Toxic effects are managed with a combination of specific antidotes and supportive care.

The aetiology of paralytic ileus secondary to toxins include effects of drugs such as opioids, anticholinergics and tricyclics; as well as intestinal ischaemia after cocaine or oral contraceptive use; and electrolyte disturbances such as hypokalaemia and hypomagnesaemia produced by toxins. It is now apparent that jellyfish envenomation should be added to the differential diagnosis of patients presenting with paralytic ileus after an unidentified marine bite or sting.

Contributors

Dr Ponampalam was responsible for the management of the patient at the emergency department, reviewing inpatient and follow up patient records, literature review, and writing of the paper.

Author's affiliations

R Ponampalam, Department of Emergency Medicine, Singapore General Hospital Correspondence to: Mr R Ponampalam, Department of Emergency Medicine, Singapore General Hospital, Outram Road, Singapore 169608; gaerpo@sgh.gov.sg

Accepted for publication 20 August 2001

REFERENCES

- 1 **Joseph WB**, Gary JC. Jellyfish envenomation syndromes updated. *Ann Emerg Med* 1987;**16**:1000–5.
- 2 **Joseph WB**, Daniel W, John AW, *et al*. Autonomic neurotoxicity of jellyfish and marine animal venoms. *Clin Auton Res* 1998;**8**:125–30.
- 3 **Pratap CR**, Selliah K. Reversible parasympathetic dysautonomia following stinging attributed to the box jellyfish. *Aust N Z J Med* 1984;**14**:673–5.
- 4 **Henry WB**, Joseph WB. Prolonged blurred vision following coelenterate envenomation. *Toxicol* 1990;**28**:731–3.

Cardioversion by venepuncture in sustained stable supraventricular tachycardia

W D Carroll, T A Willis

Emerg Med J 2002;**19**:358–359

Two cases are described of cardioversion from stable supraventricular tachycardia after venepuncture. In both cases usual vagal manoeuvres at home and in the casualty department were unsuccessful. However, attempts to site intravenous cannulas by the attending medical staff terminated his supraventricular tachycardia. Venepuncture is probably the commonest vagal manoeuvre performed in hospital but has not previously been reported as a method of cardioversion.

CASE 1

A 14 year old boy presented after two hours of sustained tachycardia. He was sweaty and tachypnoeic but had a normal blood pressure and normal capillary return. Clinical examination and electrocardiogram revealed a heart rate of 240 beats per minute and a narrow complex tachycardia. The young man was known to have Wolf-Parkinson-White syndrome and was awaiting radiofrequency ablation at a specialist centre.

Previous episodes of tachycardia had been terminated with standard vagal manoeuvres—that is, unilateral carotid pressure or Valsalva. However, on this occasion these had not been successful, so he had attended the accident and emergency department with his mother.

The casualty officer and then the paediatric registrar continued attempts at vagal stimulation, first with one sided carotid body massage, then ice, and finally Valsalva. All were unsuccessful and so the first three standard doses of adenosine were prepared while the child had an 18G cannula inserted into his antecubital fossa. The first attempt at cannulation was unsuccessful resulting in three things: a cry of “ouch” from the patient (who had insisted on watching nervously), a small haematoma, and restoration of normal sinus rhythm with a rate of 75 beats per minute. The rhythm strip taken after cardioversion clearly demonstrated the delta wave phenomenon of Wolff-Parkinson-White syndrome (fig 1).

CASE 2

An 11 year old boy presented with sudden onset of a rapid heart rate after a physical education class at school. He had

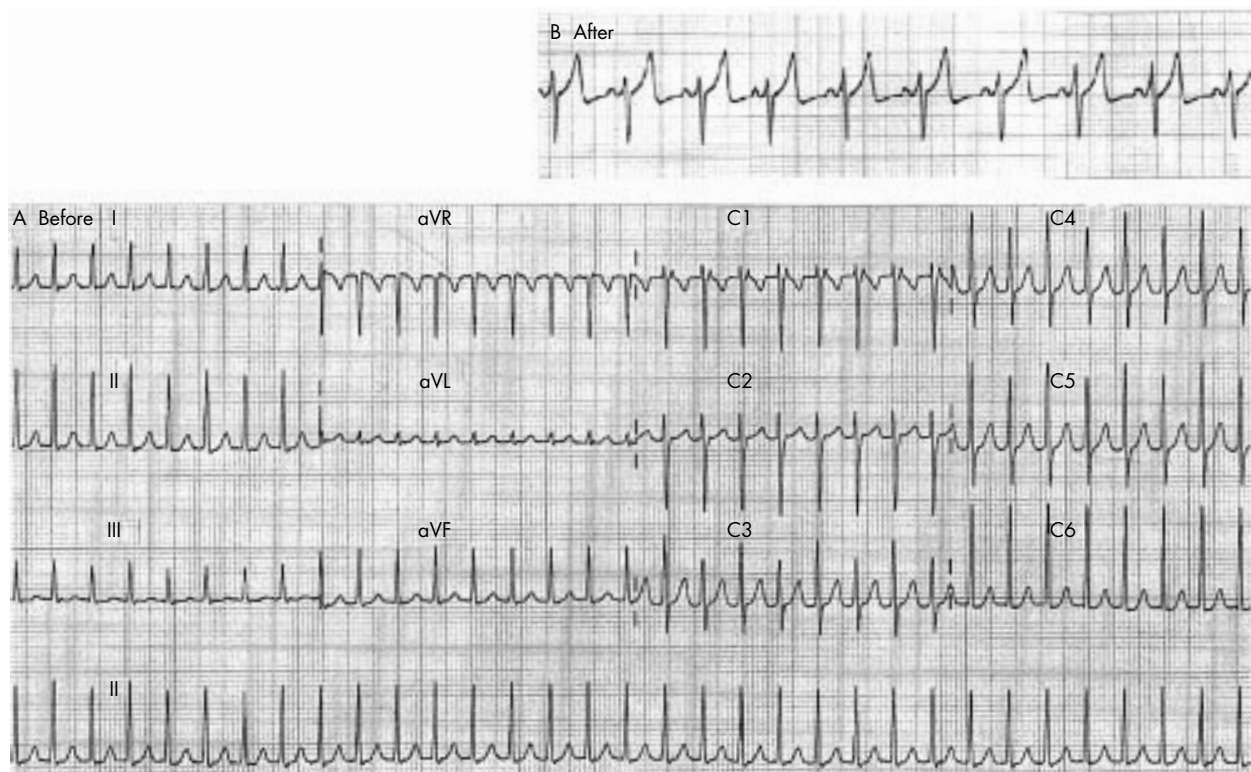


Figure 1 The 12 lead ECG before cardioversion (A) and rhythm strip taken after attempted cannulation in case 1 (B).

some mild central chest pain, but had no shortness of breath and no signs of cardiovascular compromise. Examination and electrocardiography confirmed a heart rate of 240 beats per minute with a narrow complex tachycardia. Valsalva manoeuvres and unilateral carotid sinus massage resulted in a transient but unsustained reduction in heart rate. Once again adenosine was drawn up and an intravenous cannula was sited. Cannulation resulted in successful sustained cardioversion and adenosine was not given.

COMMENT

Manoeuvres that increase vagal tone have been used to terminate paroxysmal supraventricular tachycardia since at least 1913 and have gained wide acceptance.¹ Termination of tachycardia by an increase in vagal tone is not only immediate but also may be a specific test for paroxysmal supraventricular tachycardia.² The APLS guidelines suggest unilateral carotid body massage, ice, or Valsalva.³ All of these were tried in our patient without success. More obscure methods of vagal stimulation as a treatment for paroxysmal supraventricular tachycardia have been reported in the medical literature in the past few years. These include sudden jolts along a bumpy road surface,⁴ the passing of a nasogastric tube,⁵ and the application of military antishock trousers.⁶ Vasovagal reactions are commonly seen after venepuncture in young patients.⁷ However, we could find no reports of successful cardioversion by venepuncture in the literature. Given our understanding of the physiology of vagal cardioversion and the high

incidence of vasovagal reactions after venous cannulation in young adults we would like to recommend that medical staff wait until after cannulation before drawing up adenosine that may otherwise be wasted.

Authors' affiliations

W D Carroll, T A Willis, Department of Paediatrics, City General Hospital, Stoke on Trent, ST10 1UQ, UK

Correspondence to: Dr W D Carroll; LisaorWill@aol.com

Accepted for publication 20 August 2001

REFERENCES

- 1 Waxman MB, Wald RW, Cameron DA. Vagal techniques for the termination of paroxysmal supraventricular tachycardia. *Am J Cardiol* 1990;**46**:655-64.
- 2 Lown B, Levine SA. The carotid sinus: clinical value of its stimulation. *Circulation* 1961;**23**:766-89.
- 3 Advanced Life Support Group. *Advanced paediatric life support—the practical approach*. London: BMJ Publishing Group, 1997.
- 4 Wong MP, Armstrong PW. Supraventricular tachycardia terminated by external mechanical stimulation a case of "pothole conversion". *Pacing Electrophysiol* 1999;**22**:376-8.
- 5 Gupta A, Lennmarken C, Lemming D, et al. Termination of paroxysmal supraventricular tachycardia with a nasogastric tube—a case report. *Acta Anaesthesiol Scand* 1991;**35**:786-7.
- 6 Tandberg D, Hauswald M, Rusnak R. MAST conversion of paroxysmal supraventricular tachycardia in Wolff-Parkinson-White syndrome. *Ann Emerg Med* 1987;**16**:712-14.
- 7 Pavlin DJ, Links S, Rapp SE, et al. Vaso-vagal reactions in an ambulatory surgery center. *Anesth Analg* 1993;**76**:931-5.

Beware the tooth fairy

W D Carroll, T M Lo

Emerg Med J 2002;19:360

After a period of stability, trauma patients can unexpectedly deteriorate. If this happens it is important to follow a systematic approach, if necessary repeating the primary survey. The following is an unusual case of airway obstruction not previously reported in the literature.

CASE REPORT

An 11 year old boy was admitted to the emergency department after a fall of approximately 30 feet from the roof of a factory. His initial Glasgow Coma Scale was 7 at the scene and had fallen to 6 by the time of his arrival at hospital. He was intubated with a size 6.5 cuffed endotracheal tube (18 cm at the lips). Chest, pelvis, and C-spine radiographs were taken as part of the primary survey. These showed correct position of nasogastric and endotracheal tubes, no bony injuries, and no foreign bodies. The secondary survey revealed a Smith's fracture of the left forearm and minor cuts and bruises across his face. Urgent computed tomography of the head was performed. This showed cerebral oedema, a right petrous bone fracture, and a small right frontal subdural effusion.

He was initially stable and arterial carbon dioxide was easily kept between 4.0 and 4.5 kPa. However, he suddenly became difficult to ventilate and his oxygen requirements increased. His endotracheal tube remained well secured and still at 18 cm from the lips. Auscultation showed symmetrical poor air entry with hand ventilation. Initially this deterioration was thought to be related to secretions but we were unable to pass the suction catheter down the endotracheal tube. An anterior-posterior chest radiograph was performed showing a tooth shaped radio-opaque foreign body at the tip of the endotracheal tube (fig 1).

A lateral neck radiograph was urgently requested (fig 2). This confirmed that the tooth was actually posterior to the trachea within the upper oesophagus. Its presence within the oesophagus caused posterior wall compression of the trachea resulting in partial obstruction of the endotracheal tube. The tooth (a deciduous first molar that had been wobbly before the fall) was removed successfully by the ENT surgeons under direct vision using a laryngoscope and McGill forceps. This instantly relieved the obstruction. The patient went on to make a complete recovery and was discharged from hospital two weeks later. Oesophageal foreign body is an important cause of tracheal¹ and endotracheal tube obstruction.² If suspected this can easily be confirmed with a lateral radiograph.

Contributors

Dr Carroll acts as guarantor for this article. Dr Lo drafted the original clinical details of the patient. Dr Carroll performed the literature review and prepared the final version for publication.

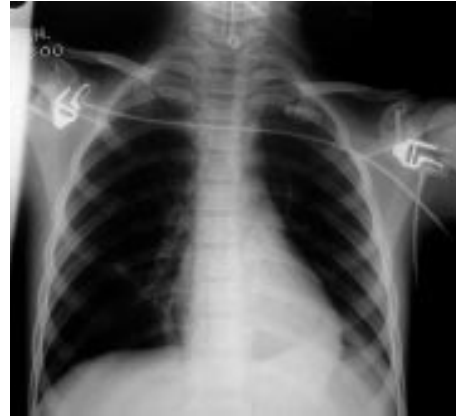

Figure 1 Plain chest radiograph showing the tooth at the tip of the endotracheal tube.

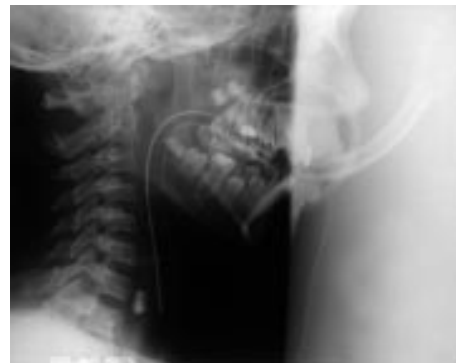

Figure 2 Lateral neck radiograph shows that the tooth is posterior to the trachea, within the oesophagus.

Authors' affiliations

W D Carroll, T M Lo, Department of Child Health, City General Hospital, Stoke on Trent, UK

Correspondence to: Dr W D Carroll

Accepted for publication 14 September 2001

REFERENCES

- 1 Handler SD, Beaugard ME, Canalis RF, *et al*. Unsuspected esophageal foreign bodies in adults with upper airway obstruction. *Chest* 1981;80:234-7.
- 2 Shah MK, Lim YC. A case of tracheal obstruction during oesophageal removal of a foreign body. *Sing Med J* 1997;38:120-2.

Pharyngeal foreign body in a child persisting for three years

S Kurul, T Kandogan

Emerg Med J 2002;**19**:361–362

Foreign body ingestions are common in children. They can pose a diagnostic problem if the foreign body is embedded in the soft tissues of pharynx. A 4 year old girl presented with halitosis for two years. A pharyngeal foreign body, a metallic ring, was seen on lateral radiographs of the neck. The foreign body was removed under general anaesthesia. A completely embedded pharyngeal foreign body should be considered in cases presenting with halitosis.

The ingestion of foreign bodies is not uncommon in infants and children. In some instances, this can go undetected, if the foreign body is embedded in the base of the tongue or pharynx.¹ We present a rare case with a longstanding foreign body, a metal ring, in the pharynx.

CASE REPORT

A 4 year old girl presented to our department with a history of halitosis. This complaint had been first noticed two years ago and had a gradual onset. It was noted that she was diagnosed with upper respiratory tract or dental infections for many times and treated with antibiotics without any benefits. The repeated throat cultures were all negative.

Examination of the oropharynx showed no abnormality except for a slightly inflamed posterior pharyngeal wall. The tonsils were normal. There were multiple bilateral microlymphadenopathies in the neck. In the endoscopic examination of the pharynx, it was noted that above the sulcus terminalis, just in the midline, there was a slight reddish, granulated tumefaction with a foul smelling discharge on it. Other clinical examinations were unremarkable. A lateral radiograph of the neck was performed to evaluate the retropharyngeal space. It showed a metallic ring stuck to the posterior pharyngeal wall at the junction of oropharynx and hypopharynx between the C1-C2 cervical vertebrae (fig 1). The parents were asked again for the source of the ring. Then, the parents informed that, at the age of 9 months, the child had swallowed her mother's golden ring while playing with it. At that time, only serial abdominal radiographs were performed and they did not show the foreign body. It was thought that, either the mother failed to detect the excretion of the ring, or that the ring had not been swallowed at all.

The foreign body was removed under general anaesthesia. The outcome of the patient was excellent. No complications were observed.

DISCUSSION

Foreign body ingestion is a common complaint in paediatric practice. The ingested foreign bodies are usually toy parts, coins, needles, pins, or plugs. They usually pass harmlessly through the gastrointestinal tract but a few become impacted at various levels of pharyngeal soft tissues.² The diagnosis of a pharyngeal foreign body may pose a problem, particularly when the history is not forthcoming, as in the patient described here. The symptoms of pharyngeal foreign bodies are usually dysphagia, pain, stertor, excessive salivation, upper respiratory tract infection, or refusal to eat and drink.^{3,4} None

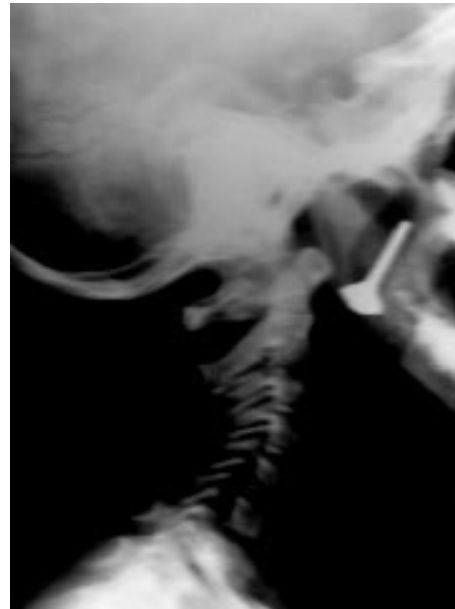

Figure 1 Lateral neck radiograph shows metallic ring density in the oropharyngeal airway.

of these symptoms were present in our patient and that was uncommon. She only complained of halitosis. The causes of halitosis are stomatitis, pharyngitis, tonsillitis, dental caries, bad oral hygiene, sinusitis, foreign bodies in upper airway, continuous oral breathing, oesophageal diverticulae, gastric bezoar, and rarely bronchiectasy and lung abscess. For the patient presented here, the lateral radiograph of the neck showed the longstanding pharyngeal foreign body as the cause of halitosis.

Undiagnosed pharyngeal foreign bodies can result in retropharyngeal cellulitis or abscess. The history provides a clue to the diagnosis. But if the history is not reliable enough, as in our patient, plain radiographic evaluation of the upper airway may provide information to the diagnostician. If the impacted foreign body is radiolucent, in the presence of positive history, symptoms or clinical suspicion, endoscopic examination is suggested.⁵ The diagnosis of radio-opaque foreign body ingestion does not pose a major problem. However, it is crucial to take a radiograph from the pharynx, where the foreign body is most likely to become impacted, to the level of pylorus.⁶ In our case, only serial abdominal radiographs had been performed during the ingestion period in infancy. For that reason, there was a delay in the diagnosis of the foreign body for this patient.

Endoscopic techniques for evaluation and management of airway problems in paediatric patients have improved greatly in the past decade. Careful selection of the most appropriate instrument and technique by well trained medical or surgical endoscopists will result in safe and effective diagnosis and treatment.⁷ For the patient presented here, the longstanding foreign body could only be removed surgically, because it was completely embedded in pharyngeal soft tissues.

In conclusion, it is important to be aware of the possibility of a pharyngeal foreign body in young children, particularly when the history is unreliable or if the clinical symptoms are atypical.

.....
Authors' affiliations

S Kurul, Dokuz Eylül University Department of Paediatrics, Izmir, Turkey
T Kandogan, Ege University Department of Otorhinolaryngology, Izmir, Turkey

Correspondence to: Dr S Kurul, Dokuz Eylül Üniversitesi Tıp Fakültesi, Çocuk Sağlığı ve Hastalıkları Anabilim Dalı, 35340, Inciraltı, Izmir, Turkey; skurul@hotmail.com

Accepted for publication 29 October 2001

REFERENCES

- 1 **Sheikh S**, Natarajan B, Johnston A. Foreign body in the hypopharynx – an unusual presentation. *J Accid Emerg Med* 1996;**13**:292–3.
- 2 **Hachimi-Idrissi S**, Corne L, Vandenplas Y. Management of ingested foreign bodies in childhood: our experience and review of the literature. *Eur J Emerg Med* 1998;**5**:319–23.
- 3 **Singh B**, Kantu M, Har-El G, *et al*. Complications associated with 327 foreign bodies of the pharynx, larynx, and esophagus. *Ann Otol Rhinol Laryngol* 1997;**106**:301–4.
- 4 **Sekhar P**, El-Jassar P, Ell SR. Recurrent unilateral tonsillitis secondary to a penetrating foreign body in the tonsil. *J Laryngol Otol* 1998;**112**:584.
- 5 **Walner DL**, Donnelly LF, Ouanounou S, *et al*. Utility of radiographs in the evaluation of pediatric upper airway obstruction. *Ann Otol Rhinol Laryngol* 1999;**108**:378–83.
- 6 **Wunsch R**, Zieger B, Darge K, *et al*. Foreign body ingestion. *Radiologe* 1999;**39**:472–7.

Respiratory papillomatosis: a rare cause of collapse in a young adult presenting to the emergency department

C D C Carroll, N C Saunders

Emerg Med J 2002;**19**:362–365

Treating patients with rapidly deteriorating respiratory compromise in the emergency room is difficult and stressful. The patient in front of you is rapidly progressing towards total cardiorespiratory collapse and you may have no idea why. A case is reported of an adult presenting with impending cardiorespiratory collapse attributed to asthma who actually had upper airway obstruction caused by laryngeal papillomata. This case report reinforces the importance of airway assessment, gives an overview of respiratory papillomatosis, and reiterates both the non-surgical and surgical approach to the difficult airway.

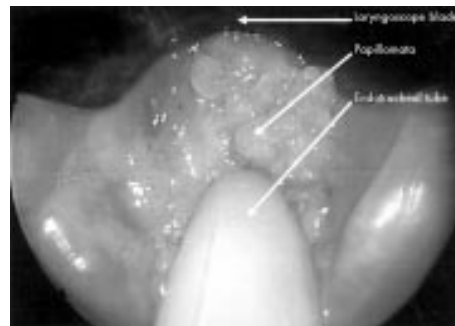


Figure 1 Photograph of the intubated larynx with the mass of papillomata surrounding the endotracheal tube.

A 21 year old woman was brought to the emergency department by paramedic ambulance, having collapsed at a bus stop. The only history available was that of a sudden onset of respiratory difficulty with an associated “wheeze”. Initial treatment was oxygen and nebulised salbutamol. On arrival at the emergency department her condition had deteriorated. She was unresponsive, hypoventilating and cyanosed, pulse oximetry reading 60%, and a heart rate of 100 beats per minute.

Having excluded contamination of the oropharynx, bag and mask ventilation was attempted, however inflation of the lungs proved unsuccessful. Venous access was established.

An initial working diagnosis of bronchospasm was made. Anaphylaxis was considered, however hypotension, urticaria, and angio-oedema were not present.

Because of the inability to ventilate the patient’s lungs, the decision was made to intubate the patient. Etomidate 10 mg followed by 100 mg suxamethonium was given intravenously.

The larynx was easily identified, with a view of the vocal cords and arytenoids (Cormack and Lehane Grade 1). However, located above the right vocal cord was a polypoid mass extending over the laryngeal inlet. This inhibited the passage of a size 8 cuffed orotracheal tube into the trachea.

One final attempt at oral endotracheal intubation was attempted while surgical airway equipment was being prepared. A gum elastic bougie was passed through the laryngeal inlet, passing the mass easily and a cuffed size 6 endotracheal tube was then passed over the bougie into the trachea. (The smallest endotracheal tube readily available in the department) (fig 1).

Ventilation of the lungs with 100% oxygen was now possible and the patient’s oxygen saturation improved quickly despite the presence of pulmonary oedema fluid in the endotracheal tube.

On auscultation of the chest, air entry was present in both lungs with slight wheeze and fine crepitations. Lung compliance was good and tidal volumes of 600 ml were achieved with peak airway pressures of 25 cm water

The diagnosis of airway occlusion secondary to supraglottic tumour was made, with pulmonary oedema resulting from excessive negative intra pulmonary pressure.

The patient was sedated, paralysed, and transferred to intensive care.

Table 1 Upper airway obstruction misdiagnosed as asthma

Author	Title	Details
Scott PMJ, Glover GW ¹⁸	All that wheezes is not asthma	66 year old woman presented for an ENT consultation with a six week history of dysphonia. She had been treated for asthma over the preceding two years. Despite usual therapies her "asthma" had worsened. The cause of the airway compromise was found to be an adenoid carcinoma at the level of the cricoid cartilage. The case report highlights the difficulty of detecting upper airway obstruction of an insidious nature.
Fortunato FD 1980 ¹⁹	Tracheal papillomatosis in an asthmatic presenting as upper airway obstruction	53 year old woman, with reversible airways obstruction presented with worsening breathlessness unresponsive to her usual bronchodilator and steroid therapy. Spirometry demonstrated flattening of inspiratory and expiratory phases of the flow-volume loop demonstrating intrathoracic obstruction. Laryngoscopy demonstrated multiple polyps originating from the subglottic region.
Coleman SA, Cooper PD 1987 ²⁰	Upper airway obstruction misdiagnosed as asthma	Three cases described 61 year old woman with a benign laryngeal cyst. Treated by her GP for late onset asthma. Presented to the ED with stridor. 69 year old woman with bilateral vocal cord palsy resulting from previous thyroid surgery, she had experienced two previous episodes of acute dyspnoea, which settled spontaneously. Stridor was recognised in the ED. After endotracheal intubation a formal tracheostomy was performed. (Both intubation and tracheostomy were technically difficult.

Collateral history revealed that the patient suffered from respiratory papillomatosis and that she had an appointment for treatment of respiratory papillomata the following day.

The patient was taken to theatre and an extensive mass of supraglottic papillomatous tissue was excised. She was returned to the ICU where she was ventilated until the following morning, and was extubated without incident. She had no neurological deficit, and was discharged home four days later.

DISCUSSION

There are numerous reports of upper airway obstruction misdiagnosed as asthma (see table 1). It is understandable why such misdiagnoses can be made. In many circumstances the patient may present late (as in this case) therefore the classic features of the "obstructed upper airway" may no longer be apparent.

The airway can be divided in the upper and lower regions. The upper region includes the mouth to carina, and this subdivided into extrathoracic and intrathoracic regions.

An ideal assessment of a partially obstructed airway in the emergency setting includes a detailed history to assess symptoms of dysphonia, hoarseness, dysphagia, and drooling. Information should be sought relating to the speed of onset of problems, the progression of the symptoms and signs, any precipitant factors, for example, inhaled foreign body, upper airway burn, neck trauma or surgery, exposure to specific allergens (drugs, latex, or food). Symptoms related to infection should also be sought (epiglottitis, laryngitis, tracheitis, quinsy, tonsillitis, abscesses). Trauma in the anterior region of the neck may result in external tracheal compression; laryngeal fracture should also be considered especially if the classic triad of hoarseness of voice, palpable laryngeal damage, and subcutaneous emphysema are present.

Signs of upper airway obstruction are initially those of noisy respiration with stridor.

The stridor can originate from any site in the upper airway. In laryngeal stridor the sound differs from the wheeze of asthma in that it is inspiratory and most prominent in the neck. The wheeze of asthma is predominantly expiratory and louder in the chest.¹ Stridor originating from trachea is a lower pitch than laryngeal noise. To illicit the sign the patient should be asked to cough then take a breath in. The noise is best heard at the mouth in the first breaths after this manoeuvre.¹ Some authors suggest that intrathoracic obstruction may result in expiratory stridor.²

With worsening obstruction to airflow, work of respiration is increased because of the necessity to produce greater swings in inspiratory/expiratory pressure. This results in the use of accessory muscles of respiration and associated tracheal tug, supraclavicular and intercostal indrawing, and paradoxical see-saw respiration. The respiratory rate will also be increased. Powerful inspiratory effort may result in the development of dermal ecchymoses and even subcutaneous emphysema.

Progression of the obstruction results in inadequate respiration, resulting in hypercarbia and hypoxia. The patient will become agitated, distressed, and if the obstruction is not relieved progressive respiratory failure will result in coma. Bradycardia, bradypnoea, hypotension, and cyanosis herald imminent cardiorespiratory arrest.³

In the less acute setting plain radiographs of neck and chest may show foreign body or soft tissue swelling, however caution must be exercised when requesting such investigations in the unstable patient. Spirometry and flow-volume loops may also give information as to the site of the upper airway obstruction.

When confronted with a patient who is in the pre-arrest phase of upper airway obstruction, and when the clinician has little or no history as a guide, it may be impossible to decide clinically the cause of the respiratory problem. Therefore, when considering tracheal intubation in the obtunded patient, upper airway obstruction should be considered, and therefore the appropriate staff and equipment present.

Recurrent respiratory papillomatosis (RRP) is an uncommon condition with an incidence of 3–4 per 100 000. In the United States an estimated 9000 adults and 6000 children are known to suffer from the disease, and in excess of 16 000 surgical procedures are conducted annually for this condition.⁴ However, this is not a condition commonly dealt with in the emergency department. To date, only one documented case of out of hospital respiratory arrest attributable to RRP has resulted in a non-fatal outcome.⁵ There are numerous recorded deaths as a direct result of total airway obstruction.^{6–8} There are no published cases of patients surviving acute respiratory occlusion from RRP in young adults (see table 2).

Papillomata are benign lesions associated with infection by human papilloma virus (HPV) types 6 or 11.^{9,10} They most commonly affect the larynx but can occur throughout the aerodigestive tract, at squamociliary epithelial junctions, and at sites of mucosal damage¹¹ including tracheotomy wounds.¹² The clinical course of the condition varies widely between people and can be difficult to predict. Growth of the lesions

Table 2 Case reports describing acute airway obstruction caused by RRP

Author	Title	Details
Helmrich G 1992 ²¹	Fatal maternal laryngeal Papillomatosis in pregnancy: a case report	24 year old pregnant woman with RRP since childhood noted to develop hoarseness and alteration in voice at antenatal visits. Failed to attend ENT clinic appointments made by the obstetricians. Developed acute airway obstruction at home, taken to ED where she had a cardiopulmonary arrest. She was resuscitated but died in ITU 10 days later.
Sperry K 1994 ⁸	Lethal asphyxiating juvenile laryngeal papillomatosis. A case report with human papilloma virus in situ hybridisation analysis	22 month girl who died in her sleep the night before evaluation and resection of RRP diagnosed three months previously.
Balazic J 1997 ²²	Sudden death caused by laryngeal papillomatosis	19 year old woman died at home hours after discharge from hospital. Surgery for known papillomatosis had been postponed that day.
Reeber CB 1999 ⁵	Laryngeal papillomatosis presenting as acute airway obstruction in a child	8 year old child admitted to hospital after out of hospital respiratory arrest attributed to asthma. The child was intubated by paramedics. A diagnosis of upper airway compromise due to laryngeal papillomata was made in ITU days later during changing of the endotracheal tube.

can be prolific, and there is a risk of malignant transformation.¹²

RRP may present either in childhood or in adult life. Upper airway papillomata generally present with hoarseness of voice whereas papillomata of the distal bronchopulmonary tree present after distal airway occlusion as atelectasis and after obstructive infection.¹² There is a significant risk of subglottic stenosis in patients who have undergone repeated excision of tracheal lesions.¹³

Papillomata have a tendency to progress down the tracheo-bronchial tree,¹⁴ and this may complicate needle cricothyroidotomy as the presence of tracheal lesions may hinder location and cannulation of the tracheal lumen.

Formal tracheostomy should be avoided if at all possible in these patients, as it may predispose to distal dissemination of papillomata previously confined to the larynx and a consequent worsening of long term prognosis.⁹ It is therefore important that this condition is recognised if at all possible at the time of attempted intubation. The papillomata appear as raised wart-like lesions (fig 1), which may coalesce into a large fleshy mass of extremely friable tissue, sometimes significantly distorting or obscuring normal anatomy. There may also be scarring present from multiple excisions or laser ablations of the papillomata. The main differential diagnosis is squamous carcinoma, but papillomatosis should be especially suspected in those aged less than 40 years, in whom malignancy of this sort is less common. In this case, the ideal management would have been attempted intubation with a small diameter uncuffed endotracheal tube. If this had been unsuccessful a temporary airway may have been achieved with an airway exchange catheter, (Cook (UK Ltd), Monroe House, Letchworth SG6 1LN); such devices have been described for maintaining the airway in patients with RRP in the elective and emergency setting.¹⁵

If endotracheal intubation had not been possible then an emergency surgical airway would have been the next course of action. Needle cricothyroidotomy (as described in the ATLS manual) would provide a means of oxygenation before performing a tracheostomy.

CONCLUSION

The management of the airway in an emergency situation is often more difficult than in the elective setting.^{16, 17} Patients may be unfasted, hypoxic, hypercarbic, shocked, and combative. The cause of the respiratory problem, as in this case, may be unexpected or require specialist airway skills and equipment.

This case shows the potential difficulties when treating airway problems in the emergency setting and emphasises the need for experienced practitioners when dealing with these problems.

Authors' affiliations

C D C Carroll, Department of Anaesthesia, Manchester Royal Infirmary, Oxford Road, Manchester M13 9WL, UK
N C Saunders, Department of Otolaryngology Head and Neck Surgery, St Mary's Hospital, London, UK

Correspondence to: Dr C D C Carroll; craigdc@carroll17.freemove.co.uk

Accepted for publication 29 October 2001

REFERENCES

- Crompton GK**. The Respiratory System. In: Munro J, Edwards C, eds. *Macleod's clinical methods*. Edinburgh: Churchill Livingstone, 1990:129-30.
- Yentis SM**, Hirsch NP, Smith GM. *Anaesthesia A to Z*. London: Butterworth Heinemann, 1993:421.
- Joynt GM**. Acute upper airway obstruction. In: Oh TE, ed. *Intensive care manual*. Oxford: Butterworth Heinemann, 1997:238-45.
- Derkay CS**. Task force on recurrent respiratory papillomas. A preliminary report. *Arch Otolaryngol Head Neck Surg* 1995;**121**:1386-91.
- Reeber CB**, Truemper EJ, Bent JP. Laryngeal papillomatosis presenting as acute airway obstruction in a child. *Pediatr Emerg Care* 1999;**15**:419-21.
- Blackie RA**, Hardcastle PF. Laryngeal polyposis causing airway obstruction. *Cent Afr J Med* 1986;**32**:36-9.
- Helmrich G**, Stubbs TM, Stoerker J. Fatal maternal laryngeal papillomatosis in pregnancy: a case report. *Am J Obstet Gynecol* 1992;**166**:524-5. [Published erratum appears in *Am J Obstet Gynecol* 1992;**166**:1313.]
- Sperry K**. Lethal asphyxiating juvenile laryngeal papillomatosis. A case report with human papillomavirus in situ hybridization analysis. *Am J Forensic Med Pathol* 1994;**15**:146-50.
- Cole RR**, Myer CM, Cotton RT. Tracheotomy in children with recurrent respiratory papillomatosis. *Head Neck* 1989;**11**:226-30.
- Gabbott M**, Cossart YE, Kan A, et al. Human papillomavirus and host variables as predictors of clinical course in patients with juvenile-onset recurrent respiratory papillomatosis. *J Clin Microbiol* 1997;**35**:3098-103.
- Kashima H**, Mounts P, Leventhal B, et al. Sites of predilection in recurrent respiratory papillomatosis. *Ann Otol Rhinol Laryngol* 1993;**102** (8 Pt 1):580-3.
- Green GE**, Bauman NM, Smith RJ. Pathogenesis and treatment of juvenile onset recurrent respiratory papillomatosis. *Otolaryngol Clin North Am* 2000;**33**:187-207.
- Perkins JA**, Inglis AF Jr, Richardson MA. Iatrogenic airway stenosis with recurrent respiratory papillomatosis. *Arch Otolaryngol Head Neck Surg* 1998;**124**:281-7.
- Alberti PW**, Dykun R. Adult laryngeal papillomata. *J Otolaryngol* 1981;**10**:463-70.
- Hulme GJ**, Blues CM. Acromegaly and papillomatosis: difficult intubation and use of the airway exchange catheter. *Anaesthesia* 1999;**54**:787-9.
- Crosby ET**, Cooper RM, Douglas MJ, et al. The unanticipated difficult airway with recommendations for management. *Can J Anaesth* 1998;**45**:757-66.
- Tayal VS**, Riggs RW, Marx JA, et al. Rapid-sequence intubation at an emergency medicine residency: success rate and adverse events during a two-year period. *Acad Emerg Med* 1999;**6**:31-7.
- Scott PM**, Glover GW. All that wheezes is not asthma. *Br J Clin Pract* 1995; **49**:43-4.
- Fortunato FD**, Bolanowski P, Carnes R, et al. Tracheal papillomatosis in an asthmatic presenting as upper airway obstruction. *J Med Soc N J* 1980;**77**:275-7.

- 20 **Coleman SA**, Cooper PD. Upper airway obstruction misdiagnosed as asthma. *Br J Hosp Med* 1989;**41**:184.
- 21 **Helmrich G**, Stubbs TM, Stoerker J. Fatal maternal laryngeal papillomatosis in pregnancy: a case report. *Am J Obstet Gynecol*

- 1992;**166**:524–5. [published erratum appears in *Am J Obstet Gynecol* 1992;**166**:1313.]
- 22 **Balazic J**, Maser A, Poljak M. Sudden death caused by laryngeal papillomatosis. *Acta Otolaryngol Suppl* 1997;**527**:111–13.

Haemorrhage into an arachnoid cyst: a serious complication of minor head trauma

K De, K Berry, S Denniston

Emerg Med J 2002;**19**:365–366

Arachnoid cysts are infra-arachnoidal cerebrospinal fluid collections that are usually asymptomatic. However, they can become acutely symptomatic because of haemorrhage and cyst enlargement, which may result from minor head trauma. The range of symptoms is wide and many are “soft” signs. Diagnosis is important as cysts causing mass effect require surgery. A case is reported of a child presenting with localised headaches after minor head trauma. Computed tomography demonstrated an arachnoid cyst with evidence of haemorrhage, which required surgical intervention. Other cases of arachnoid cyst presenting to our hospital or reported in the literature are reviewed with respect to presenting symptoms and signs. Localised headaches, behavioural or cognitive changes and ataxia are more commonly associated with this disorder than nausea, vomiting, visual disturbances or seizures. This range of symptomatology following minor head trauma may warrant computed tomography when other criteria for this investigation are not met.

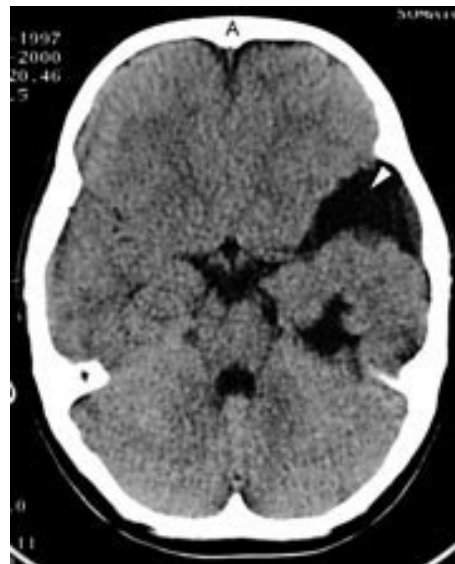


Figure 1 CT scan showing right temporal arachnoid cyst.

Intracranial arachnoid cysts are relatively rare, comprising 1% of all intracranial mass lesions,¹ of which 75% occur in children. They are benign collections of cerebrospinal fluid that are usually primary developmental abnormalities. Most are asymptomatic and found incidentally, most commonly in the middle cranial fossa and more frequently on the left side, however they may become acutely symptomatic after minor head trauma. Cysts may rupture or intracystic vessels may bleed into the cyst cavity resulting in mass effect and onset of symptoms. This may be associated with a subdural haematoma. The diagnosis is usually apparent on computed tomography although a subacute haemorrhage may appear isodense with adjacent brain tissue and require magnetic resonance imaging.² The treatment for arachnoid cysts with intracystic haematoma is surgical decompression and marsupialisation of the cyst.³

CASE REPORT

A 2 year old previously healthy boy, with normal development, presented eight days after a minor head injury. He had fallen 5–6 feet from a climbing frame onto a wood chip floor but had seemed so well after the incident that no medical attention was sought.

However, his parents noticed a new and unusual pattern of behaviour: on running or jumping he would stop suddenly and hold his left temporal region complaining of pain.

He had had no vomiting, visual disturbance or seizures. Neurological examination and fundoscopy were normal. A

non-contrast CT scan demonstrated a left sided arachnoid cyst with evidence of bleeding into the cyst cavity (fig 1).

The child was reviewed that day by a neurosurgeon and listed for craniotomy within a few weeks.

DISCUSSION

In the accident and emergency department a large number of children are seen each day after minor head injury. Some are observed in the department or on a ward but the vast majority are examined, reassured, and discharged with appropriate advice.

The Royal College of Surgeons of England has recently defined indications for skull radiography, admission, and computed tomography in a report on “Management of Patients with Head Injuries”.⁴ Although a CT scan is clearly required to make, or exclude, the diagnosis of haemorrhage within an arachnoid cyst, the symptoms and signs may be very soft and not included within these standard guidelines.

For this reason we looked at a number of cases of arachnoid cysts: 98 from our hospital and a further 74 reported in the literature, to identify the common presenting features.^{2–5,9} The majority of cysts in our series were found incidentally. Three were identified after minor head injury: one cyst had ruptured but none had intracystic haemorrhage.

The most frequently reported presenting symptom was headache, notable because it is often accurately localised (even by very young children). Behavioural problems, a change in personality and reduced mental function were the second most frequently reported signs and occasionally the only presenting features. They are very difficult to elicit and rely on an accurate history from parents or other carers. Ataxia, cerebellar signs, and falls to one side were reported more commonly than nausea, vomiting, and visual disturbance, which are the more familiar indicators of intracranial disorder. Seizures were seen in only one case.

Of additional interest were two cases who presented with solitary ipsilateral cranial nerve lesions associated with arachnoid cysts.^{2,9}

In conclusion, haemorrhage into a pre-existing arachnoid cyst is a rare but important diagnosis after minor head trauma. Symptoms and signs are non-specific and rely on an accurate history and carer observations. With this in mind, the emergency physician should have an index of suspicion and consider computed tomography outside of standard guidelines when presenting features could be consistent with this disorder.

Contributors

With thanks to Dr Helen Alton, consultant radiologist at Birmingham Children's Hospital who interpreted and aided us with the CT scan.

Funding: none.

Conflicts of interest: none.

Authors' affiliations

K De, K Berry, S Denniston, Paediatric Accident and Emergency, Birmingham Children's Hospital NHS Trust, UK

Correspondence to: Dr S Denniston, 52 Farnol Road, Yardley, Birmingham B26 2AF, UK; sarah@denniston.org

Accepted for publication 20 August 2001

REFERENCES

- 1 **Parsch C**, Kraub J, Hofmann E, *et al*. Arachnoid cysts associated with subdural haematomas and hygromas: analysis of 16 cases, long term follow up, and review of the literature. *Neurosurgery* 1997;**40**:483-90.
- 2 **Rodolfo I**, Prabhakar P. Role of MR imaging in the diagnosis of complicated arachnoid cyst. *Pediatr Radiol* 2000;**30**:329-31.
- 3 **Nun R**. Arachnoid cysts associated with post-traumatic and spontaneous rupture into the subdural space. *Comp Med Imag Graph* 1997;**21**:341-4.
- 4 **Royal College of Surgeons**. *Report of the Working Party on the Management of Patients with Head Injuries*. London: The Royal College of Surgeons of England. 1999.
- 5 **Kuhnley EJ**, White DH, Granoff AL. Psychiatric presentation of an arachnoid cyst. *J Clin Psychiatry* 1981;**42**:167-8.
- 6 **Rya H**, Makino A, Hinokuma K. An arachnoid cyst involving only the hypoglossal nerve: case report and review of the literature. *Br J Neurosurg* 1999;**13**:492-5.
- 7 **Jallo GI**, Woo HH, Meshki C, *et al*. Arachnoid cysts of the cerebellopontine angle: diagnosis and surgery. *Neurosurgery* 1997;**40**:31-7.
- 8 **Koch CA**, Voth D, Kraemer G, *et al*. Arachnoid cysts: does surgery improve epileptic seizures and headaches? *Neurosurg Rev* 1995;**18**:173-81.
- 9 **Nadkarni T**, Hande A, Nagpal R. Arachnoid cyst within the fourth ventricle - a case report. *Br J Neurosurg* 1995;**9**:675-8.

Acute appendicitis after a fall from a ladder: a traumatic aetiology?

R Hagger, J Constantinou, S Shrotria

Emerg Med J 2002;**19**:366-367

Acute appendicitis is the commonest emergency condition requiring surgery in the United Kingdom. Its precise aetiology, however, remains unproven: dietary, genetic factors, and infectious agents have been implicated.¹ Trauma has also been proposed as a cause of acute appendicitis, but there are doubts as to whether this is a casual or causal relation. In this case report we produce compelling evidence that trauma can cause acute appendicitis.

CASE REPORT

A previously fit 60 year old man was admitted with abdominal pain three days after a fall from a ladder. The mechanism of injury was that the foot of the ladder slipped away with the patient falling from about six feet to land prone on the rungs of the ladder. The patient presented with increasing right lower quadrant pain, worse on movement. Appetite was reduced; the patient was not vomiting and was passing flatus. He was becoming short of breath with a productive cough. On examination he was feverish, 39.7°C, and tachycardic. Abdominal examination revealed tenderness in the right iliac fossa and right groin. There was a firm swelling in the right groin with overlying bruising extending over the femoral triangle of the right thigh with associated scrotal oedema. Routine blood tests showed a leucocytosis. A chest roentgenogram

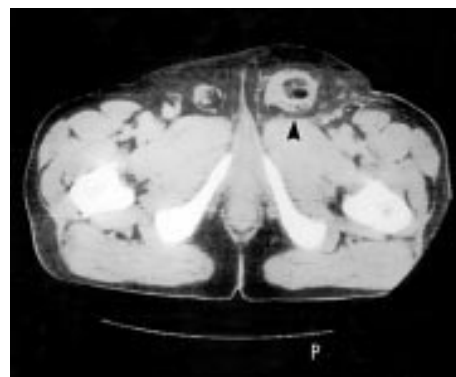


Figure 1 Computed tomogram demonstrating dilated loops of small bowel, and incarceration of oedematous bowel in a right inguinal hernia (arrowed).

gram demonstrated patchy consolidation at the base of the right lung; dilated loops of small bowel were seen on an abdominal roentgenogram. Computed tomography revealed dilated loops of small bowel, incarceration of oedematous bowel in a right inguinal hernia, and oedematous changes in

the right perirenal tissues (fig 1). At operation the right indirect inguinal hernia was found to contain a gangrenous appendix with free pus in the abdominal cavity. Appendicectomy was performed, a tube caecostomy was brought out, and the hernia was repaired with a darn repair. After an initially stormy postoperative course the patient had made a full recovery by follow up at six weeks.

DISCUSSION

Blunt trauma has been proposed as a cause of acute appendicitis: Houdini is said to have died from a rupture appendix after a blow to the abdomen.² Crush injury, a fall on bicycle handlebars, and seat belt compression after a road traffic accident have all been implicated.³⁻⁴ Haematoma or oedema of the appendiceal wall with consequent luminal obstruction proposed as the initiating pathophysiological event in the development of acute appendicitis. The difficulty with the previous reports in explaining whether trauma could cause appendicitis resides in the fact that a free lying or retrocaecal appendix would be unlikely to be injured in isolation, subsequent development of acute appendicitis after trauma being coincidental. In this case though, an appendix lying in an inguinal hernia would be more vulnerable to injury, allowing blunt trauma to compress the appendix against the unyielding pubic bone. We believe this case presents compelling evidence that blunt trauma can be a causative agent in the development of acute appendicitis.

Contributors

R Hagger had main responsibility for writing the manuscript. J Constantinou produced the figure and commented on the manuscript. S Shrotria reviewed and helped write the manuscript.

Authors' affiliations

R Hagger, J Constantinou, S Shrotria, Department of Surgery, Ashford Hospital, Middlesex, UK

Correspondence to: Mr R Hagger, 55 Heythorp Street, Southfields, London, SW18 5BS, UK; roberthag@lineone.net

Accepted for publication 20 August 2001

REFERENCES

- 1 Paterson-Brown S. The peritoneum, the mesentery, the greater omentum and the acute abdomen. In: Burnand K, Young A. *The new Aird's companion in surgical studies*. 2nd edn. London: Churchill Livingstone, 1998:722-3.
- 2 Bender JS. Acute appendicitis following blunt abdominal trauma. Incidence or coincidence? *Ann Surg* 1992;**216**:101.
- 3 Hennington MH, Tinsley EA, Proctor HJ, et al. Acute appendicitis following blunt abdominal trauma. Incidence or coincidence? *Ann Surg* 1991;**214**:61-3.
- 4 Stephenson BM, Shandall AA. Seat-belt compression appendicitis. *Br J Surg* 1995;**82**:324.

Anterior shoulder dislocation: an unusual complication

W Onyeka

Emerg Med J 2002;**19**:367-368

A case of transection of anterior circumference humeral artery, a branch of the 3rd part of the axillary artery is reported, after a simple anterior shoulder dislocation. This complication though rare could potentially result in catastrophic consequences for the patient. It should therefore be recognised early and a coordinated prompt vascular and orthopaedic surgical treatment given for better upper limb functional outcome.

A 91 year old man presented to the emergency department with severe right shoulder pain having tripped and fallen onto the shoulder about 40 minutes earlier.

He has had no previous injuries to this shoulder.

Although he had myocardial infarction nine years previously, he has no other past medical history. He was not on any medication and was fully independent.

He had normal triage observations, which were as follows; pulse rate 55/min; respiration rate 16/min; blood pressure 148/75 mm Hg; oxygen saturation 98%.

His physical examination revealed an obvious anterior dislocation of the right shoulder with normal neurovascular examination.

After administration of intravenous analgesic (10 mg morphine sulphate), radiographs were obtained, which confirmed simple subcoracoid anterior glenohumeral dislocation.

This was easily relocated soon after under Entonox (a mixture of nitrous oxide and oxygen containing 50% of each gas) using Kocher's method and confirmed radiographically.

Within minutes of relocation, the patient began to experience increasing pain in the shoulder. Close observation revealed increasing deltopectoral swelling and bruising, which aroused a suspicion of internal haemorrhage despite having normal ipsilateral brachial and radial pulses. He remained haemodynamically normal and had normal full blood count and clotting screen.

The orthopaedic and vascular surgeons were called and elected to take the patient to theatre for urgent surgical exploration. They found a bleeding transected anterior circumference humeral artery with a massive tissue haematoma of approximately 300 ml within the axillary sheath. The haematoma was evacuated and haemostasis was achieved by ligation of the bleeding artery.

Although he recovered well from anaesthesia, he was left with a brachial plexus deficit and went on to suffer considerable morbidity including: wound infection with MRSA, septicaemia, acute renal failure, and stiff shoulder. Secondary closure of his surgical wound was carried out by plastic surgeons and he was finally discharged from the ward eight weeks later. He is currently making good progress with outpatient physiotherapy.

DISCUSSION

Simple anterior glenohumeral dislocation accounts for approximately 50% of all dislocations seen in emergency departments and tends to be most frequent in healthy men.¹

It is rarely associated with vascular complications but the axillary artery or its branches may be damaged,² often with

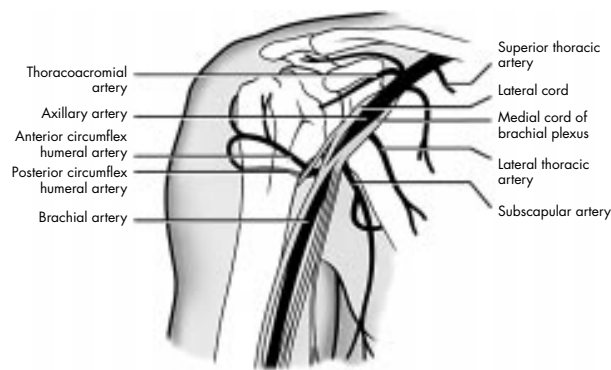


Figure 1 The close relation between the axillary artery and its six branches with the brachial plexus and the shoulder joint is illustrated.

serious consequences, as in this case. With the exception of the popliteal, the axillary artery is perhaps more frequently lacerated by violent movements than any other artery in the body.

The axillary artery is the continuation of the subclavian at the outer border of the first rib and nominally ends at the lower border of the teres major muscle where it becomes the brachial. The pectoralis minor crosses the vessel and divides it into three parts, the first part being proximal, the second posterior, and the third distal to the muscle. The first part is enclosed together with the axillary vein and the brachial plexus in the fibrous axillary sheath, continuous above with the prevertebral layer of the deep cervical fascia. This close relation, illustrated in figure 1 makes the brachial plexus vulnerable in axillary vascular injuries. The anterior circumflex humeral, a branch of the third part, is one of the six branches of the axillary artery.³

Recognised predisposing factors are: recurrent dislocation (27% of cases) and age, (86% occur in patients older than 50)⁴ resulting from adhesion to the joint capsule and atherosclerosis rendering the vessels less compliant. A review of the litera-

ture shows that the third part of the axillary artery and its branches are most commonly damaged however, there has not been a previously reported anterior circumference humeral artery injury, the smallest branch, as in this case.

This vascular injury may happen primarily at the time of dislocation or result directly during relocation. The primary injury may become evident after relocation because of loss of the tamponade effect exerted by the dislocated shoulder.

Because of the potential wide ranging consequences of this injury, which includes a reported fatal haemorrhage,⁵ it should be actively excluded by paying close attention to the injured shoulder and ipsilateral radial pulse in elderly patients who present in the emergency department with recurrent anterior shoulder dislocation.

Once suspected, selective axillary angiography should be performed urgently as delayed recognition of these lesions may lead to permanent neurological deficits despite adequate vascular repair of the affected artery.

A coordinated vascular and orthopaedic approach and prompt surgical treatment may assure full upper limb function.

Author's affiliation

W Onyeka, Accident and Emergency Department, Chelsea and Westminster Hospital, 369 Fulham Road, London SW10 9NH, UK
Correspondence to: Mr W Onyeka; wonyeka@lycos.co.uk

Accepted for publication 14 September 2001

REFERENCES

- 1 **Fitzgerald JF**, Keates J. False aneurysm as a late complication of anterior shoulder dislocation. *Ann Surg* 1975;**6**:785-6.
- 2 **Julia J**, Lozano P, Gomez F, *et al*. Traumatic pseudoaneurysm of the axillary artery following anterior dislocation of the shoulder. Case report. *J Cardiovasc Surg (Torino)* 1998;**39**:167-9.
- 3 **Warwick R**, Williams PL. *Gray's anatomy*. 35th edn. Edinburgh: Longman, 1973:647-9.
- 4 **Gates JD**, Knox JB. Axillary artery injuries secondary to anterior dislocation of the shoulder. *J Trauma* 1995;**39**:581-3.
- 5 **Lodding P**, Angeras U. Fatal axillary artery injury following anterior dislocation of the shoulder. *Ann Chir Gynaecol* 1988;**77**:125-7.

Focal lingual dystonia, urinary incontinence, and sensory deficits secondary to low voltage electrocution: case report and literature review

J R Baskerville, S A McAninch

Emerg Med J 2002;**19**:368-371

Electrocution injuries are well reported in review articles and cases of high voltage electrocution injury are abundant. However, reports of low voltage electrocution injury are few. A case is presented of low voltage shock from a 120 volt AC source with presentation, acute and chronic course, and a five year follow up. The patient experienced several unusual complications of low voltage electrocution: a persistent right tongue deviation, which initially presents as an isolated hypoglossal nerve palsy, but subsequently manifests as a focal lingual dystonia; total body paresthesia with urinary incontinence; and persistent sensory deficits to the face and tongue.

Electric shock is a relatively uncommon form of trauma, but is responsible for 7% of traumatic occupational deaths in the United States.¹ The severity of electric shock injury is dependent upon many variables: type of current (alternating current or direct current), level of applied voltage, duration of shock, body contact surface area, resistance of tissue involved, contact with water or metal conductor, and current pathway through the body.^{2,3} Medical literature typically categorises electrocution according to the level of applied voltage: low voltage (less than 1000 volts) and high voltage (greater than 1000 volts). High voltage shock is responsible for the majority of persistent⁴ and severe⁵ complications of electrocution. Lightning strikes are a special category of high voltage shock (greater than 100 million

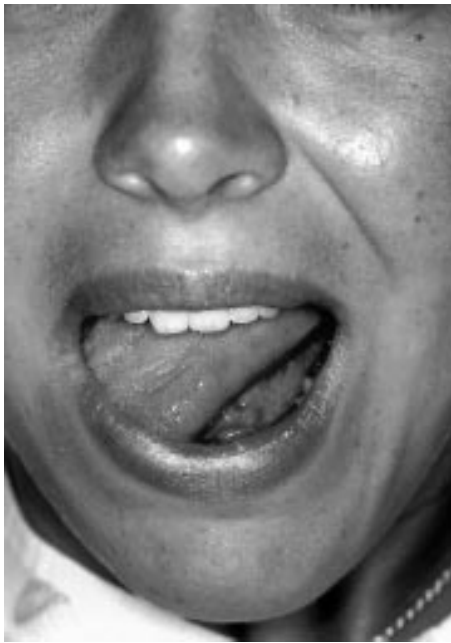

Figure 1 Right deviated tongue after low voltage electrical shock.

volts) and are discussed elsewhere.⁴⁻⁷ Low voltage electric shock accounts for 60% to 70% of reported electrocutions,⁸ and most resultant complications are relatively minor and transient. We describe a case of low voltage electrocution with some common transient complications, and, more notably, a persistent right tongue deviation; three incidences of total body numbness with urinary incontinence; and chronic sensory deficits to both the tongue and face.

CASE REPORT

A 21 year old white woman with no significant past medical history was attempting to change an overhead light bulb at work while standing on a plastic chair. She received a low voltage shock for an unknown duration of time while touching a screw on a 120 volt AC light fixture. Her hands were dry. She was wearing sandals and had dental fillings at the time of shock. Witnesses state she “jerked backwards,” possibly fell, and did have loss of consciousness for several minutes without seizure activity. However, she denied any memory of falling or loss of consciousness. She reported a feeling of confusion and a metallic taste in her mouth after the injury. She then walked into an adjacent office, where a coworker noticed her slurred speech, a right deviated tongue (fig 1), and bleeding from both ears. She was transported to our emergency department (ED), where she developed a headache, which soon resolved with no complications. A 0.5 cm second degree burn to the left second digit was present with no obvious exit location. ED examination confirmed a right tongue deviation, with dysarthria. A slight right deviation of the uvula was present, but the soft palate elevated symmetrically with a positive gag reflex. Cranial nerves II-XI were intact. She demonstrated 5/5 bilateral extremity strength, and deep tendon reflexes were 2+ and symmetric. No significant sensory deficits were noted, but she reported “numbness to right inside of mouth.” Trigeminal sensation was intact bilaterally to fine touch, vibration, and pinprick. No cerebellar deficits were noted. Tympanic membranes were intact bilaterally with no hemotympanum. Minor lesions to bilateral external auditory canals were present, which the patient stated were caused by aggressive q-tip use after the shock. Computed tomography

of the head was negative for haemorrhaging or ischaemia. Magnetic resonance imaging (MRI) was negative for basilar skull fractures or other anomaly. Electrocardiogram showed normal sinus rhythm with no ectopy. Laboratory investigations were as follows: glucose 87, Na 143, K 3.6, Cl 111, CO₂ 26, blood urea 2.5 mmol/l, creatine 0.9. The creatine kinase (total) was increased at 348 (normal 0–225). She was admitted for overnight observation with an impression of cranial nerve XII palsy secondary to electrocution. She was released from the hospital with little change in symptomology, and referred to the neurology clinic.

A neurology consultation four days after injury revealed that the right tongue deviation was still present, although not as prominent, and again assessed to be attributable to electrically induced hypoglossal nerve damage. However, neurological examination noted that the initial MRI revealed her cranial nerve XII to be “visualised and intact.” The uvula deviation and facial numbness were absent on this encounter. Also, the patient’s mother commented on her daughter’s recent memory deficits, such as forgetting previously memorised phone numbers. The patient denied any cognitive or memory impairments. The neurologist was unable to demonstrate significant cognitive deficits, including memory deficits.

The patient complained of dysarthria and dysphasia, which was secondary to decreased tongue mobility.

On neurological examination five weeks after injury, her tongue continued to deviate to the right as before, but she now described a “twitching” of her tongue. The twitching was not a fasciculation-like movement, but rather a “tonic and phasic dystonic movement,” which pulled the tongue to the right. She was re-diagnosed with an isolated lingual dystonia, and then was prescribed carbamazepine. Also, she reported right temporomandibular joint (TMJ) pain and difficulty controlling jaw movements. An oral surgery consultation concluded that her TMJ pain was attributable to fatigue of the right masseter muscle, which she consciously manoeuvred to compensate for the right tongue deviation. Significantly, our patient reports three incidences of feeling “numb all over and blacking out” with urinary incontinence beginning approximately one week after the shock. These incidences ceased concurrently with the initiation of carbamazepine. Interestingly, they did not reoccur after carbamazepine was discontinued.

Twelve weeks after injury, the patient reported little relief of dystonic movements from the carbamazepine; it was discontinued and trihexyphenidyl HCl was prescribed, which was also ineffective in relieving the dystonic movements. The patient was referred to a movement disorder clinic 21 weeks after injury for evaluation of her lingual dystonia, where 15 units of botulinum toxin (Botox) were injected to the submental muscle. A follow up visit with neurology 24 weeks after injury revealed decreased right tongue deviation, and the patient was able to move the tongue midline and to the left side “if she concentrated.” She visited a second movement disorder clinic 32 weeks after injury, noting only moderate tongue dystonia and tongue deviation, with no TMJ pain present. The second 15 unit Botox dose was injected into the mylohyoid region this time, which apparently was ineffective. She was then referred back to the first movement disorder clinic 41 weeks after injury, where she received a third and final Botox injection. In a phone interview five years after the shock, she reported no tongue deviation; however, she still reports an occasional temporary “jerking” of the tongue to the right. She states her tongue and right side of face continue to feel “numb and tingle” daily for about 15 minutes upon awakening. Also, her husband states she has a “drooping right eye lid.” She states she is taking no medication currently, and has no further medical

complaints, including muscle weakness and additional sensory deficits.

DISCUSSION

Witnesses did report loss of consciousness without seizure-like activity for a matter of minutes after the injury. It is unclear whether the loss of consciousness was attributable to the electrocution or secondary to a fall from the chair. Transient loss of consciousness is the most commonly reported complication of electrocution—independent of voltage level.²⁻⁵ Our patient reported a transient headache, which is another common complaint immediately after electrocution.⁵

Interestingly, three very unusual sequelae of low voltage shock are reported here. Firstly, the patient reported some “numbness” to the right side of her face. However, ED examination after injury revealed trigeminal sensation objectively intact. The patient states this numbness continues to this day, and occurs daily upon awakening for approximately 15 minutes. It is significant that most low voltage injuries are temporary. Although temporary decreases in sensation are also reported after shock,³ the persistence of this condition secondary to electric shock is quite unusual. Secondly, she reported three separate incidences of total body “numbness” followed by syncope and urinary incontinence approximately one week after injury. These incidences resolved after taking carbamazepine, and did not resume after carbamazepine was discontinued. Although bladder disturbance is reported in a 34 000 volt shock,⁹ I am unable to locate any reports of urinary incontinence, or total body “numbness associated with low voltage shock.” Thirdly, of notable importance is the isolated right tongue deviation. This non-painful tongue deviation began approximately three minutes after the injury and persisted for nearly one year. Again, it is significant that most complications of low voltage injury resolve quickly. This tongue deviation was initially assessed as an isolated 12th nerve palsy. No reports of electrocution induced 12th nerve palsy are present in reviewed literature. Initially, this tongue deviation was not accompanied by the signs typically associated with cranial nerve XII palsy, such as tongue atrophy, weakness, and fasciculations.¹⁰ However, five weeks after injury, tonic and phasic dystonic tongue movements, which “pulled” the tongue to the right, were noted and instead suggested a dystonia of the lingual musculature. Dystonia is an infrequent consequence of electric shock. However, there are rare reports of torticollis and limb dystonia secondary to low voltage electrocution.¹¹ This is the first known instance of focal lingual dystonia secondary to electrocution reported.¹² Botulinum toxin is known to be a beneficial agent in treating lingual dystonia.¹³⁻¹⁴ Subsequent to re-diagnosis, the patient was treated with three botox injections, which “resolved” the lingual dystonia. Months after botox treatments, the tongue rested at the midline and she could willfully move her tongue to the left. Her dysphasia, dysarthria and TMJ pain ceased with the resolution of the tongue deviation. However, she still complains of occurrences of her tongue “jerking to the right” for about 15 minutes each morning, which resolves on its own.

Other transient complications of low voltage shock are published: homonymous hemianopia¹⁵; seizures,⁵ specifically grand mal¹⁶⁻¹⁷; muteness¹⁸; transient quadriplegia¹⁸; left hemiplegia¹⁵; left hemiparesis and general motor weakness¹⁵; reflex sympathetic dystrophy¹⁹; ventricular fibrillation²⁰; abdominal visceral injuries¹⁶⁻²¹; scapular fracture¹⁶; and carpal tunnel syndrome.¹⁹ Rare occurrences of delayed onset and chronic sequelae secondary to low voltage electrocution, such as amyotrophic lateral sclerosis/motor neurone syndrome and impotence, are documented.²²⁻²³ Fatalities are reported at voltage levels as low as 46 volts and 60 volts,¹⁸ and low voltage

sources are often the chief mechanism of accidental death in the home.⁸

CONCLUSION

Serious complications of electric shock typically result from high voltage shocks such as power lines and lightning strikes. Although most low voltage electrocutions result in minor and ephemeral complications, this case presents three highly unusual sequelae: incidences of total paresthesia, followed by syncope and urinary incontinence; chronic sensory deficits to the face and tongue; and a persistent focal lingual dystonia. This case provides further evidence that low voltage sources can cause unusually debilitating and unremitting complications, and should be considered a greater potential danger than conventionally thought by clinicians. Considering that low voltage electrocutions primarily occur in the household, and account for 1% of accidental deaths in the home,⁸ this case also proves the need for greater emphasis on electrical safety in the home to prevent such potentially dangerous injuries.

ACKNOWLEDGEMENT

I would like to express my appreciation to Richard Lenehan, MD for his assistance and guidance.

Contributors

Jerry R Baskerville, MD, (guarantor and first author) was the treating physician. Dr Baskerville archived the patient data initiated and coordinated the writing of this manuscript. Scott A McAninch (second author) provided patient follow up, performed the literature research, and compilation of the manuscript.

Authors' affiliations

J R Baskerville, S A McAninch, Scott & White Memorial Hospital and Clinic, Scott, Sherwood and Brindley Foundation, Temple, Texas, USA and The Texas A&M University Health Science Center College of Medicine, College Station, Texas, USA

Correspondence to: Dr J R Baskerville, Scott and White Memorial Hospital, 2401 South 31st Street, Temple, Texas 76508, USA

Accepted for publication 26 November 2001

REFERENCES

- Ore T, Casini V. Electrical fatalities among U.S. construction workers. *J Occup Environ Med* 1996;**38**:587-92.
- Leibovici D, Shemer J, Shapira SC. Electrical injuries: current concepts. *Injury* 1995;**26**:623-7.
- Tintinalli. *Textbook of emergency medicine*. 5th edn. 293.
- Wilbourn AJ. Peripheral nerve disorders in electrical and lightning injuries. *Semin Neurol* 1995;**15**:241-55.
- Grube BJ, Heimbach DM, Engrav LH, et al. Neurologic consequences of electrical burns. *J Trauma* 1990;**30**:254-8.
- Patten BM. Lightning and electrical injuries. *Neurol Clin* 1992;**10**:1047-58.
- Critchley M. Neurological effects of lightning and of electricity. *Lancet* 1934;**1**:68-72.
- Fontanarosa PB. Electric shock and lightning strike. *Ann Emerg Med* 1993;**22**:378-87.
- Varghese G, Mani MM, Redford JB. Spinal cord injuries following electrical accidents. *Paraplegia* 1986;**24**:159-66.
- Keane JR. Combined Vllth and Xllth cranial nerve palsies: a clival syndrome. *Neurology* 2000;**54**:1540-1.
- O'Brien CF. Involuntary movement disorders following lightning and electrical injuries. *Semin Neurol* 1995;**15**:263-7.
- Ono W. Lingual dystonia following electrical injury. *Mov Disord* 1997;**12**:253.
- Brin MF, Fahn S, Moskowitz C, Friedman A, et al. Localized injections of botulinum Toxin for the treatment of focal dystonia and hemifacial spasm. *Mov Disord* 1987;**2**:237-54.
- Blitzer A, Brin MF, Fahn S. Botulinum toxin injections for lingual dystonia. *Laryngoscope* 1991;**101**:799.
- Gans M, Glaser JS. Homonymous hemianopia following electrical injury. *J Clin Neuroophthalmol* 1986;**6**:218-23.
- Buniak B, Reedy DW, Caldarella FA, et al. Alteration in gastrointestinal and neurological function after electrical injury: a review of four cases. *Am J Gastroenterol* 1999;**94**:1533-6.

- 17 **Skoog T**. Electrical injuries. *J Trauma* 1970;**10**:816–30.
- 18 **Silversides J**: **The neurologic sequelae of electrical injury**. *J Can Med Assoc* 1964;**91**:195–204.
- 19 **Rosenburg DB**. Neurologic sequelae of minor electric burns. *Arch Phys Med Rehabil* 1989;**70**:914–15.
- 20 **Hartford CE**, Ziffren SE. Electrical injury. *J Trauma* 1971;**11**:331–6.
- 21 **Williams DB**, Karl RC. Intestinal injury associated with low-voltage electrocution. *J Trauma* 1981;**21**:246–50.
- 22 **Sirdofsky MD**, Hawley RJ, Manz H. Progressive motor neuron disease associated with electrical injury. *Muscle Nerve* 1991;**14**:977–80.
- 23 **Gallagher JP**, Talbert OR. Motor neuron syndrome after electric shock. *Acta Neurol Scand* 1991;**83**:79–82.