

## CASE REPORTS

# Non-cardiogenic pulmonary oedema in the course of verapamil intoxication

S Sami Kartı, H Ulusoy, M Yandı, A Gündüz, M Koşucu, K Erol, S Ratip

*Emerg Med J* 2002;**19**:458–459

Only three cases of non-cardiogenic pulmonary oedema secondary to high dose verapamil ingestion have been described in the literature. This report describes two girls, who developed pulmonary oedema in the course of massive dose verapamil ingestion (total of 6000 mg and 7200 mg). Left ventricle size and function was normal on transthoracic echocardiograms in both of these patients. They were treated successfully with mechanical ventilatory support. The report emphasises that this fatal complication may be seen with verapamil overdose and underlying mechanisms and therapeutic approach are discussed.

Verapamil, a potent calcium channel blocker, is a smooth muscle relaxant and a negative inotropic and chronotropic agent.<sup>1,2</sup> It has been used for the treatment of hypertension, ischaemic heart diseases, and supraventricular tachyarrhythmias with side effects such as flushing, constipation, headache, vertigo, oedema, orthostatic hypotension, bradycardia, and exacerbation of heart failure.<sup>3-7</sup> In verapamil overdose hypotension, sinus arrest, atrioventricular block, decreased cardiac output, and hyperglycaemia are reported complications.<sup>6,7</sup> Non-cardiogenic pulmonary oedema has not been reported with therapeutic use of verapamil. There are 30 cases of verapamil overdose reported in the literature, three of whom were described to have non-cardiogenic pulmonary oedema.<sup>8,9</sup> We describe two patients with non-cardiogenic pulmonary oedema attributable to ingestion of a massive dose verapamil and discuss the probable mechanisms and approach to such patients.

### CASE REPORT 1

A 19 year old girl was brought to the casualty five hours after ingesting 25, 240 mg verapamil SR tablets (total of 6000 mg Isoptin SR, Knoll) for suicidal intent. She was alert and orientated; systolic BP was 110 mm Hg; diastolic BP was 70 mm Hg; pulse 56 beats per minute; and respiration rate 18 breaths per minute. The pupils were equal and responsive. Examination of chest, cardiac, and neurological systems were normal. ECG revealed sinus bradycardia with a rate of 54/min. Arterial blood gas measurements and blood glucose values were within normal limits. Despite 2500 ml of 0.9% normal saline and 20 ml of 10% calcium gluconate infusion in a few hours BP decreased gradually to 69/42 mm Hg and with dopamine infusion it rose to 94/61 mm Hg. After 24 hours of steady clinical condition, she developed dyspnoea and arterial blood gases showed pH, 7.48; Pco<sub>2</sub>, 32.5 mm Hg; Po<sub>2</sub>, 47.9 mm Hg despite 5 l/min oxygen therapy. Chest radiograph showed diffuse, bilateral patchy infiltration. Left ventricle size and function were normal on transthoracic echocardiogram. As she had progressive, severe hypoxia she was intubated and mechanical ventilation (MV) instituted on SIMV mode. Arterial blood gas values and chest radiography improved with

continuous ventilatory and other supportive measures and she was extubated on the fifth day of the MV. The chest radiograph was completely normal before discharge.

### CASE REPORT 2

A 19 year old girl was brought to the casualty seven hours after ingesting 30, 240 mg verapamil tablets (total of 7200 mg Isoptin SR, Knoll) and 6, 500 mg paracetamol tablets (total of 3 g Tylo, Nobel) for suicidal intent. On admission, she was conscious and orientated; BP was 70/40 mm Hg; pulse was 45/min; and respiratory rate was 20/min. The pupils were equal and responsive. Physical examination was normal. ECG revealed complete atrioventricular block. Chest radiography was normal. Hypotension and atrioventricular block resolved within a few hours of 2000 ml of 0.9% normal saline, 10 ml of 10% calcium gluconate and dopamine infusion. Repeated blood glucose levels were within normal limits. After about 24 hours of improvement, during the 30th hour of the hospital stay she developed progressive dyspnoea, and arterial blood gases revealed pH, 7.35; Pco<sub>2</sub>, 31 mm Hg; Po<sub>2</sub>, 41 mm Hg despite administration of 5 l/min oxygen by mask. Chest radiography revealed bilateral, diffuse alveolar infiltration. Left heart failure was ruled out with a normal transthoracic echocardiogram. She was intubated and MV was instituted on SIMV mode. Arterial blood gases and chest radiograph improved after ventilatory support and diuretics. She was extubated on the sixth day of MV. Chest radiography was normal at discharge.

### DISCUSSION

Verapamil is the first clinically used calcium channel blocker possessing various effects including peripheral and coronary arterial dilatation, negative inotropism, and chronotropism,<sup>1,2</sup> and in high doses it induces hyperglycaemia because of inhibition of insulin release from pancreatic  $\beta$  cells.<sup>6</sup> Side effects reported attributable to verapamil are flushing, oedema, dizziness, nausea, and constipation.<sup>6,7</sup> The more important complications of verapamil, seen in susceptible patients or with verapamil overdose are congestive heart failure, cardiac arrest, bradycardia, atrioventricular block, and hyperglycaemia.<sup>6</sup>

There are no reports of non-cardiogenic pulmonary oedema with therapeutic use of verapamil. In 1994, Leesar *et al*, and in 1996, Brass *et al* reported one and two cases, respectively, with non-cardiogenic pulmonary oedema supposed to be attributable to massive dose verapamil ingestion and were treated successfully with MV.<sup>8,9</sup> The mechanism of this side effect is not well known.

Several mechanisms may be involved in non-cardiogenic pulmonary oedema seen during the course of verapamil intoxication. Firstly, Leesar *et al* suggested that verapamil may lead to leaky capillary syndrome<sup>8</sup> attributable to inhibition of prostacycline, a cellular membrane protector, release.<sup>10</sup> Some mention that prolonged hypotension and a shock-like state may contribute to the development of pulmonary oedema.<sup>8,11-14</sup> Secondly, calcium channel blockers cause pre-capillary vasodilatation and peripheral oedema,<sup>15</sup> and a

massive dose of verapamil may cause oedema in the lung with the same mechanism.<sup>8</sup> Finally, an interaction between verapamil and inflammatory cytokines may have role in that acute respiratory distress like syndrome can be seen in the course of verapamil overdose. In serum samples of patients with acute respiratory distress syndrome, TNF $\alpha$  and IL1 were shown to be increased.<sup>16,17</sup> There have been studies of calcium channel blockers, including verapamil and cytokine release, but the results have been conflicting, probably because of the verapamil concentration used.<sup>18,19</sup> High concentrations of verapamil significantly increase IL1 induced expression of endothelial leucocyte adhesion molecule-1 (ELAM-1).<sup>18</sup> This mechanism may have a role in the pulmonary oedema seen in verapamil intoxication and needs to be clarified with further studies. Whatever the underlying pathophysiological mechanism is, the important contributory factor is the volume overload because of excessive saline infusion to such patients, especially during the hypotensive period, in emergency units. The mechanisms, mentioned above, probably only makes these patients more prone to the development of pulmonary oedema.

Non-cardiogenic pulmonary oedema occurred in 5 of 32 cases (15.6%) with verapamil intoxication reported in the literature, including our two patients. It seems that non-cardiogenic pulmonary oedema may occur during the course of verapamil overdose and the patients should be observed closely, up to 72 hours with repeated arterial gas analysis. Pressor therapy/inotropic therapy should be started upon hypotension to overcome the effects of profound peripheral vasodilatation and negative chronotropic and inotropic effects. It must be emphasised that excessive saline infusion should be avoided, as this may exacerbate the pulmonary oedema. If respiratory distress is observed together with hypoxia upon arterial gas analysis, the patient should be intubated immediately and mechanical ventilation instituted.

#### Contributors

S Sami Kartı: data collection and drafting of the report. Mustafa Yandı, Kayhan Erol and Abdülkadir Gündüz: treatment and follow up of the patients during their admission and stay in the accident and emergency service. Hülya Ulusoy and Müge Koşucu: treatment and follow up of the patients during their stay in the intensive care unit. Siret Ratıp: critical revision and drafting of the report. Guarantor: S Sami Kartı.

#### Authors' affiliations

S Sami Kartı, Department of Haematology, Farabi Hospital, Karadeniz Technical University, School of Medicine, Trabzon, Turkey  
 H Ulusoy, M Koşucu, Department of Anaesthesiology and Reanimation, Farabi Hospital, Karadeniz Technical University, School of Medicine  
 M Yandı, A Gündüz, K Erol, Department of Emergency, Farabi

Hospital, Karadeniz Technical University, School of Medicine  
 S Ratıp, Department of Haematology, School of Medicine, Marmara University, Istanbul, Turkey

Funding: none.

Conflicts of interest: none.

Correspondence to: Dr S Sami Kartı, Hematoloji Bölümü, Karadeniz Teknik Üniversitesi Tıp Fakültesi Hastanesi, Trabzon, 61080, Turkey; samikarti@yahoo.com

Accepted for publication 12 December 2001

#### REFERENCES

- Dargie H, Rowland E, Krikler D. Role of calcium antagonists in cardiovascular therapy. *Br Heart J* 1981;**46**:8-16.
- Low RI, Takeda P, Mason DT, et al. The effects of calcium channel blocking agents on cardiovascular function. *Am J Cardiol* 1982;**49**:547-53.
- Conti CR, Pepine CJ, Feldman RL, et al. Calcium antagonists. *Cardiology* 1985;**72**:297-321.
- Yedinak KC. Use of calcium channel antagonists for cardiovascular disease. *Am Pharm* 1993;**33**:49-64.
- Lund-Johansen P. Clinical use of calcium antagonists in hypertension: update 1986. *J Cardiovasc Pharmacol* 1987;**10**:29-35.
- Russell RP. Side effects of calcium channel blockers. *Hypertension* 1988;**11**:42-4.
- Dustan HP. Calcium channel blockers. Potential medical benefits and side effects. *Hypertension* 1989;**13**:137-40.
- Leesar MA, Martyn R, Talley JD, et al. Noncardiogenic pulmonary edema complicating massive verapamil overdose. *Chest* 1994;**105**:606-7.
- Brass BJ, Winchester-Penny S, Lipper BL. Massive verapamil overdose complicated by noncardiogenic pulmonary edema. *Am J Emerg Med* 1996;**14**:459-61.
- Nadler JL, McKay M, Campese V, et al. Evidence that prostacycline modulates the vascular action of calcium in man. *J Clin Invest* 1986;**77**:1278-84.
- Henry JN. The effect of shock on pulmonary alveolar surfactant. Its role in refractory respiratory insufficiency of the critically ill or severely injured patient. *J Trauma* 1968;**8**:756-73.
- Herrington DM, Insley BM, Weinmann GG. Nifedipine overdose. *Am J Med* 1986;**81**:344-6.
- Natarajan D, Sharma SC, Sharma VP. Pulmonary edema with diltiazem in hypertrophic obstructive cardiomyopathy. *Am Heart J* 1990;**120**:229-32.
- Rinaldo JE, Rogers RM. Adult respiratory-distress syndrome: changing concepts of lung injury and repair. *N Engl J Med* 1982;**306**:900-9.
- Low RI, Takeda P, Mason DT, et al. The effects of calcium channel blocking agents on cardiovascular function. *Am J Cardiol* 1982;**49**:547-53.
- Shanley TP, Warner RL, Ward PA. The role of cytokines and adhesion molecules in the development of inflammatory injury. *Mol Med Today* 1995;**1**:40-5.
- Headley AS, Tolley E, Meduri GU. Infections and the inflammatory response in acute respiratory distress syndrome. *Chest* 1997;**111**:1306-21.
- Hailer NP, Blaheta RA, Harder S, et al. Modulation of adhesion molecule expression on endothelial cells by verapamil and other Ca++ channel blockers. *Immunobiology* 1994;**191**:38-51.
- Tatakis DN, Schneeberger G, Dziak R. Recombinant interleukin-1 (IL-1) stimulates prostaglandin E2 production by osteoblastic cells: role of calcium, calmodulin, and cAMP. *Lymphokine Cytokine Res* 1991;**10**:95-9.

# An unusual presentation of a lumbar hernia

A Hindmarsh, S Mehta, D A Mariathas

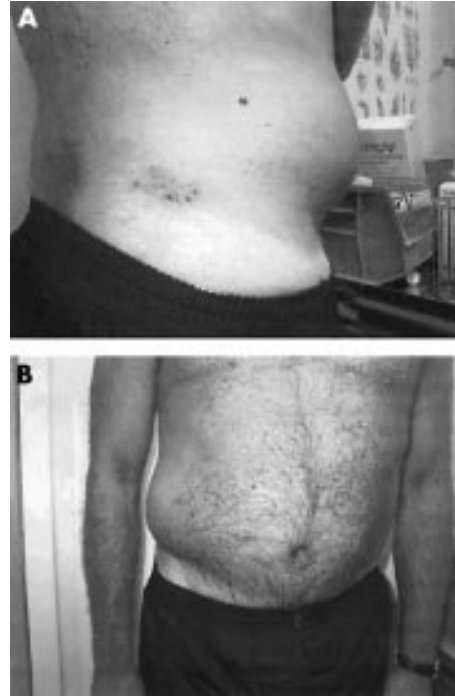
*Emerg Med J* 2002;19:460

A 64 year man walked into the accident and emergency department with a 24 hour history of swelling in his right flank. Approximately two weeks before his presentation he had developed a painful rash over his right loin. There was no history of trauma. He denied any systemic upset and a review of his gastrointestinal and genitourinary systems was unremarkable. He did however give a history of chickenpox as a child. On examination he appeared well, was afebrile, and haemodynamically stable. He had a prominent vesicular rash over his right loin in the distribution of T11-L1 (fig 1A). His abdomen was soft and non-tender with no organomegaly. He had an obvious swelling over his right flank, which became more prominent on standing. This measured approximately 20 cm by 10 cm (fig 1B). The swelling was easily reducible, and a marked cough impulse was demonstrable. A provisional diagnosis of a lumbar hernia secondary to herpes zoster infection was made. He was reassured and sent home with follow up. At clinic review 43 days after his initial presentation there was complete resolution of both the vesicular rash and lumbar hernia.

## COMMENT

A lumbar hernia may occur spontaneously through one of two anatomical weak points in the lumbar region, the lumbar triangle of Petit or the superior quadrilateral lumbar space. They have also been reported secondary to operative procedures in the lumbar region, and as a result of paralysis of the lateral lumbar muscles after poliomyelitis or spina bifida.

The incidence of muscle paresis after herpes zoster infection is estimated at 1%–5%, although this may well be an underestimate. The resulting weakness usually develops in those muscles innervated by the affected cord segment that corresponds to the cutaneous manifestation.<sup>1</sup> Symptoms of focal muscle paresis usually appear within two weeks of the appearance of the rash. Total or almost complete recovery is usual, although in 20% of cases a substantial disability remains.<sup>2</sup> Upper and lower limb, diaphragmatic, and abdominal wall muscle paresis has been described,<sup>3</sup> but in the English literature we could find no previous case reports of a lumbar hernia secondary to abdominal wall muscle weakness after herpes zoster infection.



**Figure 1** (A) Herpes zoster vesicular rash over the right loin; (B) right sided lumbar hernia.

## Authors' affiliations

A Hindmarsh, S Mehta, D A Mariathas, Department of Accident and Emergency, Broomfield Hospital, Chelmsford, CM1 7BU, UK

Correspondence to: Mr S Mehta; samir@doctors.org.uk

Accepted for publication 31 January 2002

## REFERENCES

- 1 Cockerell OC, Ormerod IEC. Focal weakness following herpes zoster. *J Neurol Neurosurg Psychiatry* 1993;56:1001–3.
- 2 Hirschmann JV. Herpes zoster. *Semin Neurol* 1992;12:322–38.
- 3 Flamholz L. Neurological complications in herpes zoster. *Scand J Infect Dis Suppl* 1996;100:35–40.

# Two cases of biceps injury in bodybuilders with initially misleading presentation

F Dunn

*Emerg Med J* 2002;**19**:461–462

Two cases are reported of biceps injuries in body builders. In both cases the mechanism of injury is either unclear or initially misleading. One case went on to develop necrotising fasciitis, requiring extensive debridement after an initial diagnosis of a biceps haematoma. This report emphasises the difficulties inherent in differentiating necrotising and non-necrotising infections in the emergency department setting and highlights a subgroup of patients who may be at particular risk of delayed diagnosis.

Soft tissue injuries form a large portion of the workload in the emergency department setting. Difficulties arise in attempting to differentiate simple soft tissue injuries from other infective causes.

Necrotising fasciitis is a fulminant disease that can present initially as a benign soft tissue injury. Unfortunately the most common cause of mortality is the delay from presentation to definitive treatment because of diagnostic error.<sup>1,2</sup>

By the nature of the sport, bodybuilders are prone to muscle sprains and tears and may present to the emergency department for initial treatment.

Unfortunately soft tissue infections including necrotising fasciitis are well documented in the body building community secondary to drug injection.<sup>5,6</sup> This report reinforces the need for vigilance in assessing these injuries at initial presentation in this specific group of patients.

## CASE REPORT 1

A 26 year old man attended the emergency department complaining of pain in his right biceps. He was a keen bodybuilder and had been training four days before attending. He had awakened the next day with a severe pain in his biceps, which he put down initially to a muscle tear; however, the pain had not eased.

Examination revealed a well developed biceps, with a hot tender mass overlying the belly of the muscle. The patient was systemically well. The diagnosis was of a tear to the belly of the biceps with haematoma formation; treatment was with ice packs, pain relief, and a referral to physiotherapy.

The patient re-presented as a self referral four days later with what now was an obviously infected biceps with necrotic overlying skin and brawny erythema tracking to the axilla and pectoral area. He had experienced increasing pain in the arm and only presented again when the skin changes became obvious. He felt cold, shivery, and nauseated. His temperature was 37.9°C and the pulse rate 100/min. The white cell count was  $19 \times 10^9$ . A diagnosis of soft tissue infection with abscess formation was made, the patient was given intravenous cefuroxime and metronidazole. At this point the patient was asked specifically about corticosteroid use or the possibility of penetrating injury or injection in the infected area. However, this was denied.

Incision and drainage the same evening by the on call surgical team revealed necrotic overlying skin, fascia, and biceps muscle, all of which was debrided down to healthy tissue. Pus

from the wound grew  $\beta$  haemolytic streptococcus group F, and bacteroides. On the advice of the resident bacteriologist, the patient was given intravenous benzylpenicillin, clindamycin, ciproxin, and metronidazole.

After the initial debridement the patients condition continued to deteriorate with infection advancing to the axilla and anterior chest wall. At this point the patient was transferred for tertiary care at the regional plastic surgery service.

There, he underwent extensive debridement of the biceps and pectoralis muscles, the infective process extended down onto the axillary vessels and the brachial plexus. After successful control of the infection a large skin defect was grafted.

Ongoing problems include neurogenic forearm pain for which the patient attends the pain clinic and scar contractures for which further procedures are planned.

## CASE REPORT 2

A 35 year old man presented to the emergency department complaining of pain and swelling in his right biceps for two weeks, which had gradually got worse; he complained of feeling unwell and felt shivery. He was an enthusiastic body builder and initially the pain had started after weight training.

On examination he had a tense, red tender swelling over the belly of his biceps, which was painful to move. Axillary lymphadenopathy was present ipsilaterally. The temperature was raised at 38.4°C and the pulse rate was 90/min. Investigations included a raised white blood cell count at  $12.89 \times 10^6$  and an erythrocyte sedimentation rate of 50 mm 1st h. The provisional diagnosis was of soft tissue infection and the patient was admitted for intravenous antibiotics.

Further discussion led to the admission that he had actually injected a mixture of fatty acids intramuscularly into his biceps in the belief that this would stimulate muscle growth. He also admitted that he was a regular user of anabolic steroids, both orally and intramuscularly. His wish was to keep these revelations confidential as he feared for the possible repercussions both professionally and from his sports governing body.

He was admitted under the care of the surgical team, and given intravenous flucloxacillin and benzylpenicillin. Ultrasound examination did not reveal any collection in the biceps and confirmed the patency of the axillary vein. Blood cultures performed on admission revealed no growth. The infection settled uneventfully and he was discharged after seven days, without complications.

## DISCUSSION

Simple soft tissue injuries account for a large proportion of the day to day workload of an emergency department. Nevertheless the above cases highlight the diagnostic pitfalls for the unwary. Mortality for necrotising fasciitis has been observed to be 26%–29%. Delay in definitive treatment because of failure to recognise and diagnose the condition at first presentation is the most common cause of mortality.<sup>1,2</sup> Where there is a history of trauma (often non-penetrating) the initial diagnosis is often that of muscle strain/tear.<sup>1,2</sup>

There is a paucity of signs distinguishing necrotising fasciitis from non-necrotising soft tissue infection or inflammation.

Patients complain of pain, erythema, and swelling in both cases, but tense oedema and/or bullae or skin necrosis is reported as diagnostic for necrotising fasciitis.<sup>1,2</sup> Causes of acute biceps pain and swelling include muscle tear with haematoma formation and axillary vein thrombosis, however, distinguishing these conditions from soft tissue infection is difficult and in some cases may be impossible.<sup>2</sup> It is obvious that a high index of suspicion must be maintained at all times.

If necrotising fasciitis is suspected clinically in the emergency department, investigation should be secondary to urgent surgical referral with a view to debridement along with appropriate antibiotic cover.

Although a literature search produced few cases arising spontaneously, soft tissue infection, including necrotising fasciitis, is well documented in body builders using intramuscular injections.<sup>3,4</sup>

For the following reasons, the above cases highlight bodybuilders as a subgroup of the population vulnerable to soft tissue infections.

Evidence exists that corticosteroid use is widespread and is significantly under reported,<sup>9,10</sup> but over one million people in the United States are estimated to be current or past users of anabolic steroids with 50% of these injecting intramuscularly.<sup>5,6</sup> Other substances injected include insulin, growth hormone, diuretics, and fatty acid preparations.<sup>9</sup>

The sharing of needles, combined with poor and unhygienic injection techniques creates the ideal circumstances for infecting organisms to flourish and pass from user to user.<sup>6</sup>

Corticosteroid use in both the general population and bodybuilders has been shown to alter the immune response and could therefore contribute to the development of soft tissue infections including necrotising fasciitis.<sup>7,8</sup>

Finally, compounding the problem is the culture of illicit drug misuse among bodybuilders. Fear of sanction from such sources as the police, work, or sporting governing bodies results in under reporting of the use of performance enhancing drugs, and leads to attempts to disguise the true mechanism of injury.<sup>9,10</sup>

Inevitably this can lead to both delay in presentation and subsequent diagnostic confusion, resulting in serious long term complications, particularly highlighted in case 1.

## SUMMARY

Soft tissue infections from self injecting corticosteroids have been well documented in the body building community, as have necrotising fasciitis resulting from intramuscular and intravenous injections.

The above cases illustrate the pitfalls in the diagnosis and treatment of a very select group of patients and emphasises the need for a high index of suspicion for an infective process in what seem, initially, to be simple muscle tears.

The cases also highlight the need for a frank (and confidential) discussion with the patient about his training habits and methods; doing so may avoid delay in the detection and treatment of potentially life threatening soft tissue infections.

## Contributors

Fergal Dunn was the author of the paper. Dr E L Dowey advised in the writing of the paper. Dr E L Dowey, Consultant in A&E medicine, Belfast City Hospital is the guarantor of the paper.

## Author's affiliations

F Dunn, Emergency Department, Belfast City Hospital, Belfast BT9 7AB, UK Correspondence to: Dr Dunn; fdunn@doctors.org.uk

Accepted for publication 31 January 2002

## REFERENCES

- 1 Wall DB, de Virgilio C, Black S, *et al*. Objective criteria may assist in distinguishing necrotizing fasciitis from non-necrotizing soft tissue infection. *Am J Surg* 2000;**179**:15–20.
- 2 Bisno AL, Cockerill FR, Bermudez CT. The initial outpatient-physician encounter in group A streptococcal necrotizing fasciitis. *Clin Infect Dis* 2000;**31**:607–8.
- 3 Callahan TE, William MD, Schechter P, *et al*. Necrotizing soft tissue infection masquerading as cutaneous abscess following illicit drug injection. *Arch Surg* 1998;**133**:812–18.
- 4 Pillans PJ, O'Connor N. Tissue necrosis and necrotizing fasciitis after intramuscular injection of diclofenac. *Ann Pharmacother* 1995;**20**:264–6.
- 5 Rich JD, Dickinson BP, Flanagan TP, *et al*. Abscess related to anabolic-androgenic steroid injection. *Med Sci Sports Exerc* 1999;**31**:207–9.
- 6 Rich JD, Dickinson BP, Feeler A, *et al*. The infectious complications of anabolic-androgenic steroid injection. *Int J Sports Med* 1999;**20**:563–6.
- 7 Akita S. Necrotizing fasciitis after underlying illness and steroid intake. *Ann Plast Surg* 2000;**44**:112–13.
- 8 Calabrese LH, Kleiner SM, Barna BP, *et al*. The effects of anabolic steroids and strength training on the human immune response. *Med Sci Sports Exerc* 1989;**21**:386–92.
- 9 Wayne K, Auge MD, Augue SM. Naturalistic observation of athletic drug-use patterns and behaviour in professional-caliber bodybuilders. *Sport and Substance Use and Misuse* 1999;**34**:17–24.
- 10 Ferenchick GS. Validity of self reporting in identifying anabolic steroid use among weightlifters. *J Gen Intern Med* 1996;**11**:554–55.

# Flagellation: a rare cause of pneumothorax

A Akhtar, C Bhattacharjee, S Khan, P A Bradley, A F Shenton

*Emerg Med J* 2002;19:463

**W**e report an unusual case of self inflicted pneumothorax caused by self flagellation with a chain laden with knives during a religious Muslim festival. Despite many cases of pneumothorax having been described in the literature,<sup>1</sup> we have been unable to find any of this nature.

## CASE REPORT

A 27 year old Pakistani Muslim man was brought to our department by ambulance after complaining of pain in the right side of his chest. He belonged to the Shi'ite branch of the Islamic faith and had been practising religious self flagellation on the same afternoon.

He reported the symptoms to have started three hours after the religious practice of self flagellation. The patient had flayed himself on the back with a chain laden with small curved knives.

On examination he was distressed and mild dyspnoeic. His pulse rate was 83 and blood pressure was 138/81. He maintained his oxygen saturations at 96% on air all throughout.

Examination of the chest revealed multiple scars from previous wounds and two new deep wounds to the skin on the right side of the posterior chest wall. There was also a large haematoma under the wound.

On auscultation there was decreased air entry on the right side of the chest.

A chest radiograph (fig 1) shows the presence of a large right sided pneumothorax.

A chest drain was inserted in the accident and emergency department and the patient was admitted to the hospital under the care of the thoracic surgeons.

Initial blood investigations revealed a raised white cell count of 20.1 with a neutrophilia of 17.0.

He made an uneventful recovery and the chest drain was removed the following day. He was discharged two days later.

## DISCUSSION

The practice of self flagellation is common among the adherents of the Shi'ite group of Islam on important religious occasions, particularly on the 10th day of the Islamic month of Moharram.<sup>2</sup> This day commemorates the martyrdom of Imam

Hussain, the grandson of the Prophet Mohammed, at the Battle of Kerbala, which took place in 680 AD.<sup>3</sup> On this day large processions are carried out, by the Shi'ite communities throughout the world. During the processions scenes from the battle of Kerbala are re-enacted and self flagellation is carried out. Such processions are becoming increasingly common in cities of the United Kingdom with large Muslim, particularly Pakistani communities.

The practice of self flagellation usually entails the participant flaying themselves on the upper back with chains and multiple short, blunt and either curved or straight knives attached to chains (fig 2). In our department we have frequently seen patients with multiple superficial lacerations to many areas of the body after self flagellation but we can find no report in the literature of a pneumothorax caused by self flagellation. Surprisingly, though the patient developed a large pneumothorax, he was clinically stable all throughout.



**Figure 2** Typical self flagellation implement.

## CONTRIBUTORS

Ahmed Akhtar was involved in the management of the patient, thought and discussed the case, collected the pictures, and wrote the paper. Chanchal Bhattacharjee has discussed ideas and designs of this paper, participated in writing and editing the case report. Saima Khan has analysed the case and discussed the ideas and carried out the literature search. Peter Bradley and Anthony Shenton were actively involved in the primary management of the patient, provided the idea and discussed the core idea of the case report. Ahmed Akhtar and Chanchal Bhattacharjee will act as guarantors of the paper.

## Authors' affiliations

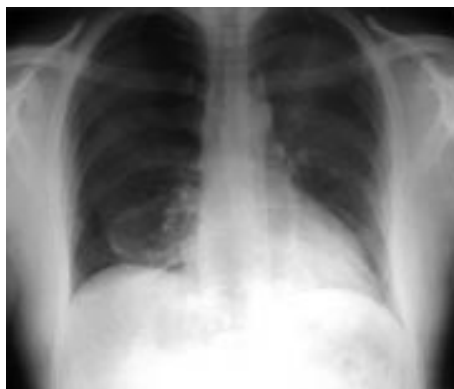**A Akhtar, C Bhattacharjee, S Khan, P A Bradley, A F Shenton,** Accident and Emergency Department, Bradford Royal Infirmary, Duckworth Lane, Bradford BD9 6RJ, UK

Correspondence to: Mr A Akhtar

Accepted for publication 31 January 2002

## REFERENCES

- 1 **Berger D.** A fish induced pneumothorax: dilemmas in the remote management of a sucking chest wound. *BMJ* 1996;313:1617-18.
- 2 *Encyclopaedia Britannica.* 15th edn. USA: Encyclopaedia Britannica Incorporation, 1990:591.
- 3 **Kennedy H.** *The prophet and the age of the caliphates.* London: Longman Publication, 1986:89-90.



**Figure 1** Posteroanterior chest radiograph.

# The externally rotated leg: a trap for the unwary

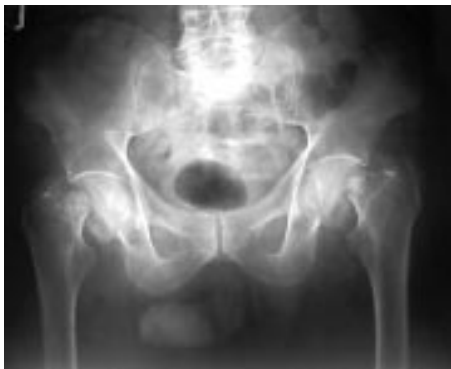F Lam, S Hussain

*Emerg Med J* 2002;19:464

A 91 year old man with known epilepsy was brought into the emergency department after a grand mal seizure. During the fit, he fell down two steps landing on his back. After the seizure, he complained of severe back pain and inability to move his legs. He was previously independently mobile but after the fall, was unable to weight bear.

On examination, both legs were held symmetrically in an externally rotated position. He was unable to actively straight leg raise and passive movements of his legs were painful in all directions. Pronounced motor weakness was noted proximally around the pelvic girdle. Otherwise, he was neurologically intact with normal reflexes, sensation, and anal tone.

Spinal abnormality was suspected and a radiograph of the lumbar spine showed marked osteoarthritic changes with no evidence of a fracture. Subsequently, a pelvic radiograph showed a bilateral subcapital fractured neck of femur (fig 1). The patient was later treated with bilateral hemiarthroplasties and was independently mobile on discharge.



**Figure 1** Bilateral displaced sub-capital fracture neck of the femur is shown.

## DISCUSSION

About 15% of epileptic seizures result in trauma with head injury being the most common.<sup>1</sup> The occurrence of a bilateral fractured neck of femur after a seizure is a rare occurrence. The most commonly reported cause for this fracture pattern is electric shock, whether accidental or controlled (electroconvulsive therapy).<sup>2</sup>

Our case reinforces that a thorough physical examination is important in the assessment of elderly patients after a fall. The classic signs of a shortened and externally rotated leg occurring in a displaced fractured neck of femur, can be easily missed as in this case, where there was referred back pain.<sup>3</sup> Careful assessment and constant awareness of an abnormal limb position will help reduce the incidence of missing this important fracture.

## Contributors

Both Mr F Lam and Miss S Hussain contributed to the writing of this case report and Mr F Lam will act as guarantor for this paper.

## Authors' affiliations

**F Lam**, Department of Trauma and Orthopaedic Surgery, William Harvey Hospital, Ashford, Kent TN24 0LZ, UK

**S Hussain**, Department of Trauma and Orthopaedic Surgery, Royal Sussex County Hospital, UK

Correspondence to: Mr F Lam

Accepted for publication 21 January 2002

## REFERENCES

- 1 Kirby S, Sadler RM. Injury and death as a result of seizures. *Epilepsia* 1995;36:25-8.
- 2 Vanderhooft E, Swiontkowski M. Bilateral fracture neck fractures following a grand mal seizure. *Ann Emerg Med* 1994;24:1188-91.
- 3 Slipman CW, Rogers DP, Lipetz JS, et al. An unusual extraspinal cause of bilateral leg pain. *Arch Phys Med Rehabil* 1999;80:721-4.

# Subcutaneous emphysema of the neck and colonic perforation

I Hunt, F Van Gelderen, R Irwin

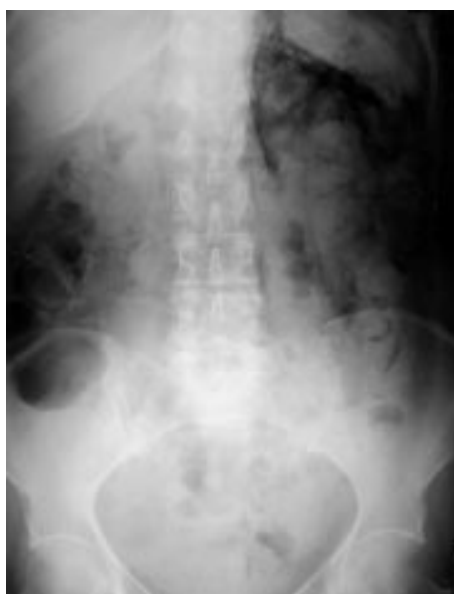*Emerg Med J* 2002;19:465

Subcutaneous emphysema may result from pathological changes in the thorax or lung, as a result of localised infection with gas producing organisms, after abdominal procedures, or herald an intestinal perforation. The location and spread of extraperitoneal gas is determined by the anatomical barriers and fixed fascial layers surrounding the region of pathological change. The case highlights the extent of extraperitoneal gas after colonic perforation despite minimal clinical features and the importance of intra-abdominal causes of cervical subcutaneous emphysema.

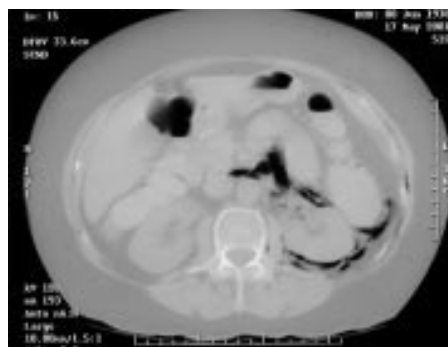
A 62 year old woman presented to the accident and emergency department with a three day history of progressive abdominal pain in the left iliac fossa. This followed several weeks of constipation. She had one episode of fresh red blood per rectum and nausea on the day she presented. She had a past history of diverticulitis. Clinically she looked well, afebrile with mild tenderness in her left iliac fossa. Subcutaneous emphysema was present in her neck. Blood tests revealed a neutrophilia of 24.6. Diverticulitis was suspected and abdominal radiographs requested. The supine film demonstrated retroperitoneal gas outlining psoas, the left kidney and adrenal (fig 1).

Contrast enhanced computed tomography confirmed retroperitoneum, with gas extending between internal and external oblique abdominal musculature (fig 2). Gas also extended into the mediastinum outlining the aorta circumferentially and the oesophagus to its right.

Laparotomy was performed and a large cavity found behind the proximal sigmoid colon along the pelvic brim. It contained free faeces and pus. A Hartmann's procedure was completed



**Figure 1** Supine abdominal radiograph clearly showing retroperitoneal gas outlining psoas, left kidney, and adrenal.



**Figure 2** Contrast enhanced computed tomography showing retroperitoneum, with gas extending between internal and external oblique abdominal musculature.

with oversewing of the rectosigmoid junction and fashioning of an end colostomy. A reversal is planned later.

## DISCUSSION

Perforation of a colonic diverticulum from infection and inflammation typically causes faecal or purulent peritonitis. Usually the inflammatory process involves surrounding tissues such as mesentery, gut, and posterior abdominal wall. The localised abscess may rarely rupture into retroperitoneal tissues with gas tracking upwards, most often localising to the left side.<sup>1</sup> The psoas muscle typically limits posterior pararenal retroperitoneal gas medially, laterally gas may extend into the flank, and superiorly gas may outline the suprarenal area, medial crus of the diaphragm, and posterior aspect of the liver and spleen. Extension above the diaphragm through diaphragmatic hiatus can lead to the development of cervical and thoracic subcutaneous emphysema.<sup>1</sup>

Subcutaneous emphysema of the neck, chest wall, abdomen or thigh may be the first manifestation of an occult perforation, either from sigmoid diverticulitis or from other retroperitoneal processes.<sup>2</sup> In particular, infradiaphragmatic causes of pneumomediastinum and subcutaneous gas in the neck and chest should always be considered.<sup>3</sup>

## Authors' affiliations

**I Hunt**, Department of Surgery, Wellington Hospital, Wellington, New Zealand

**F Van Gelderen**, Department of Radiology, Masterton Hospital, Wairarapa, New Zealand

**R Irwin**, Department of Surgery, Masterton Hospital, Wairarapa, New Zealand

Correspondence to: Mr I Hunt, 1 Church Lane, Kislbury, Northampton NN7 4AD, UK; ianjhunt@hotmail.com

Accepted for publication 31 January 2002

## REFERENCES

- 1 Meyer MD. Radiological features of the spread and localization of extraperitoneal gas and their relationship to its source. *Radiology* 1974;111:17-26.
- 2 Stahlgren LH, Thabit G. Subcutaneous emphysema: an important sign of intra-abdominal abscess. *Ann Surg* 1961;153:126-33.
- 3 Moses LC, Glauser FL. A subtle chest radiographic finding. Where is the pathology? *Chest* 1992;102:935-6.



# Traumatic pneumomammothorax

D Walker, C D Deakin, G Smith

*Emerg Med J* 2002;19:466–467

A 57 year old woman was a restrained front seat passenger, involved in a high speed, head on, motor vehicle accident. She was trapped for 30 minutes, during which time she was reported as being conscious but complaining of difficulty in breathing. On arrival in the emergency room, primary survey showed her airway to be intact. There was reduced air entry in the right chest, and dullness to percussion at both bases, with a respiratory rate of 40 breaths/min. Her initial blood pressure was 95/70 with a regular pulse of 120/min. Neurologically, she was conscious with a GCS of 15. Secondary survey showed extensive bruising in a seat belt pattern over her chest and abdomen. Abdominal skin over her lower abdomen was disrupted by a degloving injury. The soft tissues of her right breast were noted to be grossly distended.

Radiological examination showed an unstable fracture of the C2 vertebra, a large right haemothorax with multiple rib fractures (T2–T7), and a small left haemothorax and fractured left first rib. Chest radiograph showed widened mediastinum. Other injuries included a compound fracture of the left tibia and right ulna.

A right chest drain was inserted without complication and drained 200 ml of blood in addition to air. She began to deteriorate haemodynamically and computed tomography of the chest was performed. This showed a large pocket of air in the right breast that was in communication with a large pneumothorax, which developed as a result of her initial trauma. The mediastinum was noted to be widened due to haematoma (fig 1A and B). She continued to deteriorate and was taken to theatre for an urgent laparotomy where she was

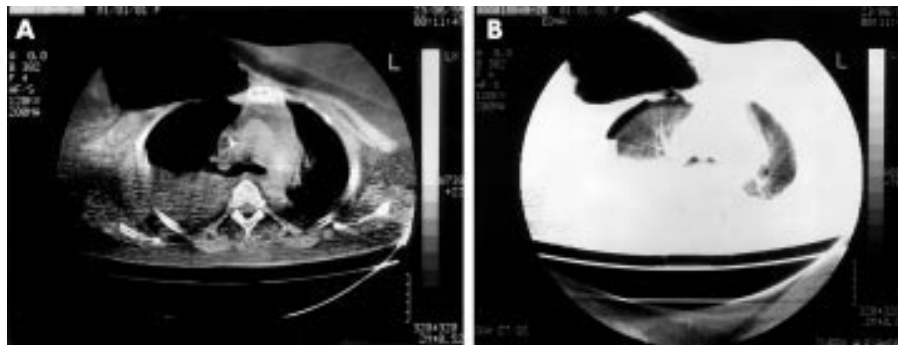
found to have a ruptured large bowel with mesenteric avulsion. A halo frame was fitted to stabilise her cervical spine.

Postoperatively she was admitted to the intensive care unit (ICU). Repeat chest radiography showed resolution of the right haemo-pneumothorax but the right breast remained grossly distended by the large air pocket (fig 2A and B). The chest drain was removed on day 6 and the right breast returned to normal size over the following month as the air was resorbed. She made a remarkable and slow recovery from her injuries, complicated by pseudomonas septicaemia, and further abdominal surgery. She spent 30 days in ICU and a further three months on the ward before being discharged home.

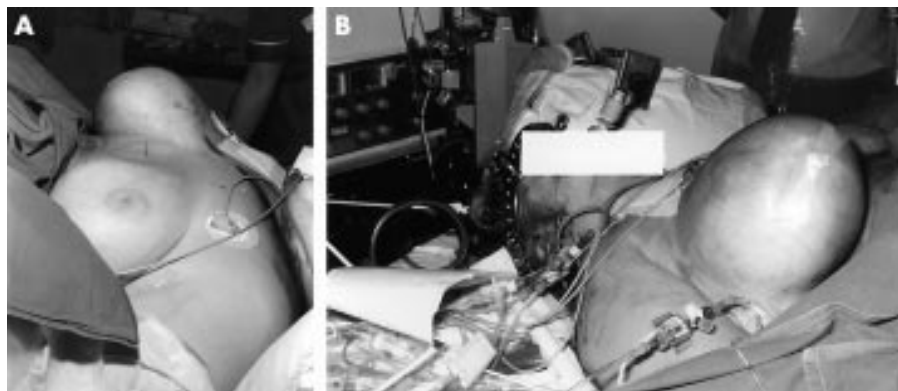
## DISCUSSION

The female breast comprises mostly of adipose tissue, lying within the superficial fascia of the anterior chest wall. Its base is a thin layer of retromammary fat extending from the second to sixth rib, which lies anterior to deep fascia covering pectoralis major and serratus anterior muscles. The breast itself is divided into numerous fibrous septae radiating out from the nipple to form 15–20 lobules of glandular and adipose tissue.

Breast injury after motor vehicle accidents usually results from compression on the breast tissue by the shoulder restraint of the seat belt to cause a wide band of contusion. In cases of severe injury, bruising and oedema cause fat necrosis, which progresses over one to two months to form lipid cysts. As the lipid cysts and contusion resolve, a line of fibrosis develops, which may become calcified after three to four



**Figure 1** (A) and (B) CT scan showing right pneumothorax, disrupted anterior chest wall, and large air collection in right breast.



**Figure 2** (A) and (B) Grossly distended breast approximately 24 hours after admission to the intensive care unit.

years.<sup>1</sup> Surgical emphysema in subcutaneous tissues around the breast is relatively common after rib fractures, but in these cases air lies in superficial tissue planes and does not extend through the fibrous covering of the breast. Although surgical emphysema was present in tissues of the lateral chest wall, a large air pocket within the breast tissue is not a pattern of injury previously reported. The CT scan shows division of the right pectoralis major and minor muscles with communication of the right pneumothorax with a large air pocket within the breast tissue.

We believe that this is the first reported case of a traumatic pneumothorax communicating with soft tissue of the breast. The multiple rib fractures and ensuing pneumomammothorax reflect the severity of the mechanism of injury in this case. There were no specific clinical complications caused by the pneumomammothorax. This case report shows that air in the breast after trauma may indicate significant thoracic injury.

#### Contributors

Dr Gary Smith was the consultant in charge of this patients care. It was Dr Smith who identified this as a unique case with

a useful learning point if published. Professor Deakin completed a literature review, formulated the discussion, and helped produce the final draft. Dr Walker wrote up the case history, contributed to the discussion, and produced the final manuscript. Professor Deakin will act as guarantor.

.....

#### Authors' affiliations

**D Walker, C D Deakin, G Smith**, Department of Intensive Care Medicine, Queen Alexandra Hospital, Cosham, Portsmouth PO6 3LY, UK

Correspondence to: Dr G Smith

Accepted for publication 31 January 2001

#### REFERENCE

- 1 **DiPiro PJ**, Meyer JE, Frenna TH, *et al*. Seat belt injuries of the breast: findings on mammography and sonography. *Am J Roentgenol* 1995;**164**:317–20.

# Failure of detection of pneumothorax on initial chest radiograph

T P C Kane, M C Nuttall, R C Bowyer, V Patel

*Emerg Med J* 2002;19:468–469

Failure to detect a pneumothorax may have serious complications. A case of a pneumothorax, which may have been overlooked if thoracic computed tomography had not been performed, is discussed.

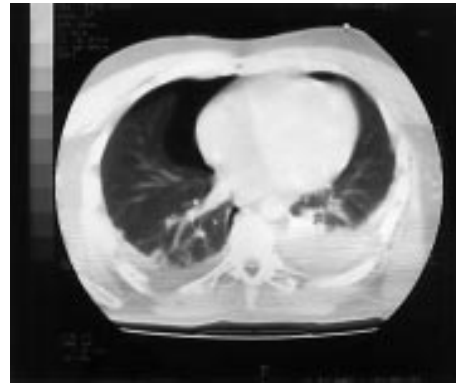A 35 year old man was ejected from a sports car while racing at the UK Goodwood Revival Meeting 2000 (fig 1). At the scene, the patient was maintaining his own airway with normal bilateral air entry. He was tachycardic (110 beats per minute), blood pressure 130/80, with normal capillary refill time, and a Glasgow coma score of 15/15. The only obvious injury was bruising to the left thoracic-scapular area. Intravenous access was established and high flow oxygen was administered. The patient was immobilised on a spinal board and transferred to the local hospital.

On arrival, the primary survey remained unchanged. Secondary survey confirmed a painful right hemithorax and bruising of the left thoracic-scapular region with some overlying abrasions. The abdomen was soft and non-tender and no signs of injury were evident in the upper and lower limbs with no neurovascular deficit. Spinal examination was unremarkable. Chest radiographs revealed an intra-articular fracture of the left glenoid and left scapula and fractures of the right fifth, sixth, and seventh ribs. Radiographs of the cervical spine, pelvis, and thoracic and lumbar spines were normal. However, because of the markers of severe injury present and the possibility of an underlying pneumothorax, the chest radiograph was repeated. This did not reveal any new changes. The patient remained haemodynamically stable but in view of the high energy mechanism of injury, computed tomography of the chest and abdomen was undertaken.

The CT scan showed a right anterior pneumothorax and small left haemopneumothorax (fig 2), which in retrospect was not visible on the chest radiographs. Bilateral chest drains



**Figure 1** Subject being ejected from his car.



**Figure 2** CT scan showing haemopneumothoraces.

were inserted in the fifth intercostal space in the mid-axillary line and the patient transferred to the intensive therapy unit for 24 hours of close observation. The scapular injury was assessed by shoulder arthroscopy and treated expectantly. The patient remained stable and was discharged from hospital five days later.

## DISCUSSION

The risk of serious injury is increased by more than 300% if the occupant is ejected from a vehicle.<sup>1</sup> The incidence of significant chest injury is also increased in the presence of scapula fracture, reflecting the severity of trauma required to cause this injury.<sup>2</sup>

Thoracic injuries are the cause of death in 25% of trauma fatalities and a major contributor in 50%.<sup>3</sup> Despite this, pneumothorax may often be initially overlooked and not always be detected on plain chest radiography. In one study of 103 severely injured patients with blunt chest trauma, 67 had major chest injuries that had been missed on chest radiograph and of these 27 had pneumothoraces and 21 had haemopneumothoraces. The thoracic CT scan was significantly more sensitive than routine chest radiography in detecting pneumothoraces.<sup>4</sup> In another study of 90 trauma patients initial supine chest radiography failed to detect a pneumothorax in 35 patients<sup>5</sup>; the diagnosis being made on thoracic CT scans within 24 hours of admission. A further study reported four cases of occult pneumothorax not visible on chest radiograph, which were later diagnosed on spiral CT scan.<sup>5</sup>

Mechanical ventilation of a pneumothorax may cause tensioning and respiratory and cardiovascular deterioration. The use of nitrous oxide during anaesthesia may cause further expansion of pneumothoraces.<sup>6</sup> This case reiterates the need for a high index of suspicion relating mechanism of injury to possible underlying occult chest injuries such as a pneumothorax. While routine thoracic computed tomography may not be advocated in all cases of blunt chest trauma, it should be undertaken whenever markers of severe injury or high energy mechanisms of injury are present or if the patient requires mechanical ventilation, in which case it may significantly change management.<sup>6</sup> Early thoracic computed tomography is

superior to routine chest radiography in diagnosing pneumothorax and haemothorax.<sup>4,7</sup> If left undiagnosed, the consequences of mechanical ventilation, in the presence of a pneumothorax may be fatal. Blunt injury to the chest may also be associated with injury to abdominal viscera and a CT scan of the abdomen should be performed at the same time as the thoracic CT scan. With the advent of spiral computed tomography, the time spent in the CT scanner is not significantly increased, which otherwise would obviously have an inherent danger.

#### Contributors

T P C Kane initiated the case report. M C Nuttall performed the literature search and wrote the report in conjunction with T P C Kane. R C Bowyer was the consultant surgeon responsible for the care of the patient and V Patel was the consultant orthopaedic surgeon who performed the shoulder arthroscopy. M C Nuttall acts as guarantor for the case report.

#### Authors' affiliations

T P C Kane, M C Nuttall, R C Bowyer, Department of Surgery, St Richard's Hospital, Chichester, UK  
V Patel, Department of Orthopaedic Surgery, St Richard's Hospital

Correspondence to: Dr M C Nuttall, 8 Senator Gardens, Fishbourne, Chichester PO19 3RL, UK; mcnutall@mail.com

Accepted for publication 31 January 2002

#### REFERENCES

- 1 **Advanced Trauma Life Support Group.** *Advanced Trauma Life Support Manual* 1997: appendix 2, page 352.
- 2 **Rockwood CA, Green DP.** *Fractures in adults*. 4th edn. Philadelphia: Lippincott-Raven, 1996:1166.
- 3 **Bridges KG, Welch G, Silver M, et al.** CT detection of occult pneumothorax in multiple trauma patients. *J Emerg Med* 1993;**11**:179–86.
- 4 **Trupka A, Waydhas C, Hallfeldt KKJ, et al.** Value of thoracic computed tomography in the first assessment of severely injured patients with blunt chest trauma: results of a prospective study. *J Trauma* 1997;**43**:405–11.
- 5 **Collins JA, Samra GS.** Failure of chest x-rays to diagnose pneumothoraces after blunt trauma. *Anaesthesia* 1998;**53**:74–8.
- 6 **Eger EI, Saidman LJ.** Hazards of nitrous oxide anaesthesia in bowel obstruction and pneumothorax. *Anesthesiology* 1965;**26**:61–6.
- 7 **Mirvis SE, Shanmuganathan K.** Trauma radiology: Part II. Diagnostic imaging of thoracic trauma: review and update. *Journal of Intensive Care Medicine* 1994;**9**:179–90.

# A strange case of a tension pneumothorax

D Boon, T Llewellyn, P Rushton

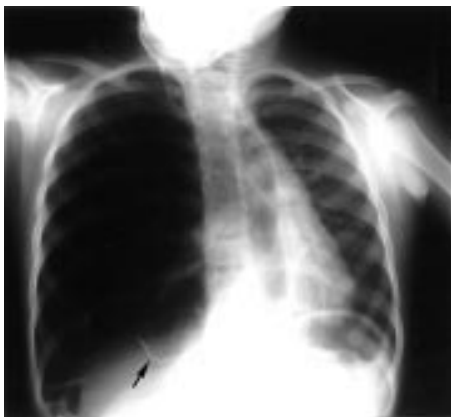*Emerg Med J* 2002;19:470-471

A 5 year old boy attended the emergency department with a tension pneumothorax secondary to congenital cystic adenomatous malformation of the lung. Management problems are discussed and congenital cystic adenomatous malformation reviewed.

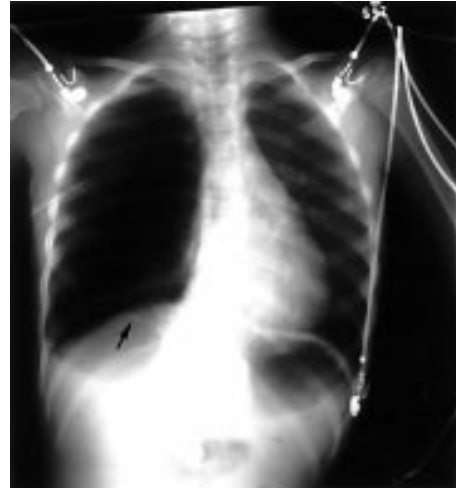A 5 year old boy presented to the emergency department with central chest pain and dyspnoea, which had developed during the morning before admission. He complained of two recent minor falls from which he had sustained no apparent injuries. He had no significant immediate past medical history and had a normal exercise tolerance. The patient had been born at term and had no neonatal problems. As an infant he had had a cough that had been treated as asthma with inhalers and that settled spontaneously by the age of 1 year. There was no relevant family history.

On examination the respiratory rate was increased, the trachea was deviated to the left, and there was decreased air entry on the right. Other than an increased respiratory rate the child displayed no other signs of cardiovascular compromise. An urgent chest radiograph was performed (fig 1), which showed a right sided pneumothorax with mediastinal shift. A chest drain was inserted under sedation. On insertion air was heard to escape from the chest and once secured the drain was swinging satisfactorily. The procedure relieved the child's symptoms. On repeat radiography while the mediastinum was now central a large air collection appeared to remain on the right hand side (fig 2). On closer examination of the radiograph thin walled bullae were identified filling the right chest cavity.

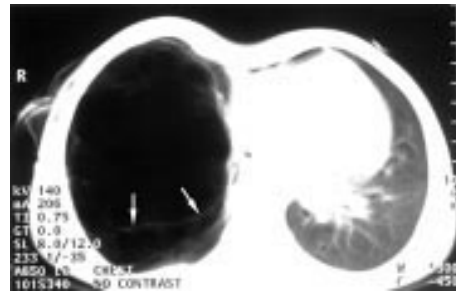
The child was referred to the Regional Children's Cardiothoracic Centre. Computed tomography (fig 3) showed the right hemithorax to be slightly larger than the left suggesting a longstanding abnormality. There was a small amount of mediastinal air anteriorly but no significant residual pneumothorax. The left lung appeared normal. A complex cystic entity replaced virtually all of the right lung with the appearance of a congenital cystic adenomatous malformation (CCAM). Two days later he underwent a right pneumonectomy. He made an uneventful recovery and was discharged



**Figure 1** Chest radiograph showing a pneumothorax with shift of the mediastinum (arrow indicates the wall of one of the cysts).



**Figure 2** Chest radiograph after insertion of chest drain (arrow indicates the wall of one of the cysts).



**Figure 3** Computed tomography of the chest showing cystic lesions filling the right hemithorax (arrow indicates cyst wall).

four days later. A histological report confirmed the diagnosis of CCAM.

## DISCUSSION

CCAM is rare and usually presents before the age of 3 years.<sup>1,2</sup> The exact incidence is now known. It is more common in boys than girls, and it is usually unilateral. Patients can present with life threatening respiratory distress or a history of recurrent chest infections.<sup>1-3</sup> Some cases are asymptomatic and are discovered as an incidental finding on radiography. CCAM is best diagnosed with computed tomography and is treated with lobectomy.<sup>1,3,4,6</sup> This may have to be done as an emergency depending on clinical state, and some cases have been operated on prenatally. Treatment can be postponed if the patient is asymptomatic and the cyst is resolving.<sup>2</sup> Long term outcome is very good, affected children leading normal lives with only slight decrease in lung volume.<sup>1,5,6</sup> Congenital emphysema can present in a similar way and should be considered in the differential diagnosis.<sup>1,2,3,4,6</sup>

This case presented an acute management problem to the staff dealing with it. The child had the classic respiratory signs and symptoms of a tension pneumothorax, but was cardiovascularly stable. There was no obvious cause for the child to have

this condition and spontaneous tension pneumothorax is extremely rare in children. Rather than following standard treatment guidelines for management of a tension pneumothorax staff opted for a “look before you leap” approach and performed a chest radiograph before performing thoracocentesis or chest drain insertion.

Once the diagnosis of tension pneumothorax had been made a decision was made to insert a chest drain as a single procedure rather than to perform a needle decompression followed by chest drainage. This decision was made to cut down the number of invasive procedures performed, and in the knowledge that the child remained cardiovascularly stable. In retrospect, it was felt that the best treatment option had been taken as, in the presence of large air filled cysts, the insertion of a chest drain using blunt dissection and an open technique run less chance of puncturing a cyst than inserting a needle into the chest.

#### Contributors

Dr Daranee Boon wrote the first draft of the paper and performed the literature search, and collated the illustrations. Dr Peter Rushton was involved in the initial management of the clinical case and identified the case as being worthy of a case report. Dr Thomas Llewellyn re-wrote the first draft of the paper and is guarantor of the paper.

.....

#### Authors' affiliations

**D Boon, T Llewellyn, P Rushton**, Emergency Department, Cheltenham General Hospital, Sandford Road, Cheltenham GL53 7AN, UK

Correspondence to: Dr T Llewellyn; tom.llewellyn@egnhst.org.uk

Accepted for publication 31 January 2002

#### REFERENCES

- 1 **Coran AG**, *et al.* Congenital cystic disease of the tracheobronchial tree in infants and children. Experience with 44 consecutive cases. *Arch Surg* 1994;**12**:521–7.
- 2 **Evrard V**, *et al.* Congenital parenchymatous malformations of the lung. *World J Surg* 1999;**23**:1123–32.
- 3 **Schwartz MZ**, Ramachandran P. Congenital malformations of the lung and mediastinum—a quarter century of experience from a single institution. *J Pediatr Surg* 1997;**32**:44–7.
- 4 **Al-Bassam**, *et al.* Congenital cystic disease of the lung in infants and children. (Experience with 57 cases). *Eur J Pediatr Surg* 1999;**9**:364–8.
- 5 **Pinter A**, *et al.* Long-term outcome of congenital cystic adenomatoid malformation. *Paediatric Surgery International* 1999;**15**:332–5.
- 6 **Frenckner**, *et al.* Pulmonary function after lobectomy for congenital lobar emphysema and congenital cystic adenomatoid malformation. A follow-up study. *Scand J Thorac Cardiovasc Surg* 1982;**16**:293–8.

# A hemlock water dropwort curry: a case of multiple poisoning

C Downs, J Phillips, A Ranger, L Farrell

Emerg Med J 2002;19:472-473

**H**emlock water dropwort (*Oenanthe crocata*) is perhaps the most poisonous indigenous plant in Britain.<sup>1</sup> It is a member of the Umbellifer family and is found in ditches, damp meadows, in steams, by riverbanks, and in marshes. It is a large, stout plant between three and five feet high that flowers in July. The lower stem is usually thick and joins to clusters of fleshy tubers that gives rise to the popular name "dead man's fingers".

The entire plant is poisonous. The tubers, stems, and leaves contain oenanthotoxin, a highly unsaturated higher alcohol, which is known to be poisonous and a powerful convulsant.<sup>2</sup>

The majority of the umbellifer family are harmless. These include species of celery, parsley, parsnip, and carrots. The poisonous members are hemlock (*Conium maculatum*), cowbane (*Cicuta virosa*), and hemlock water dropwort.<sup>3</sup>

Poisoning by hemlock water droplet is an infrequent event. A number of human fatalities have occurred over the years, although animals are its usual victims.

## CASE HISTORY

A group of eight young adults who were on holiday in Argyll collected what they thought were water parsnips from a small stream. The roots were cleaned, chopped, and added to a curry. All consumed the curry, but the majority of the group only had a small amount of the root, which was easily identifiable in the curry, partly because there was some doubt regarding its nature and partly because of its bitter taste.

Early the next morning, 10 hours after ingestion one of the group had a witnessed grand mal seizure lasting about five minutes. He was taken to the community hospital and was in a post-ictal state. No connection at this point was made with the ingestion of the plant root the night before.

Gradually over the course of the next four hours a number of the group became unwell and nauseated. During this time four of the group consumed the left overs for lunch. One of these individuals, subsequently become increasingly unwell, nauseated, and began to vomit. He had a witnessed grand mal seizures lasting about three minutes. On arrival at the emergency department this person was conscious but vomiting and experiencing visual hallucinations. The patient was agitated, tachycardic, but blood pressure and oxygen saturation were within normal limits. He was hyper-reflexive with dilated pupils, but there were no focal neurological signs. He had one further subsequent grand mal seizure controlled with intravenous diazemuls.

The other patients all had varying degrees of nausea, vomiting, lethargy, sweating, and low grade fever.

Initially it was uncertain from the description as to the identity of the poisonous plant. The community hospital that they were admitted to serves a rural area of Argyll. The police were able to take an asymptomatic member of the group to the stream to recover a further plant. The police knew of a local botanist in the area who was able to positively identify the specimen (fig 1).

Four of the group required admission to the hospital. The person who had required intravenous diazemules, was observed over the next 48 hours. Biochemical and haematological parameters were all within normal limits, and his symptoms settled rapidly. The other three were discharged after 24 hours.



Figure 1 Digital image of the plant recovered from the stream.

## DISCUSSION

Hemlock water dropwort poisoning is rare in humans and the number of people in this case report is very unusual. The main toxic constituent of hemlock water dropwort is oenanthotoxin. The concentration of this poison in the plant roots is highest in winter and spring and ingestion of very small amounts may prove fatal.<sup>2</sup> These events occurred in April when the concentration of toxin is still high. Oenanthotoxin is, however unstable,<sup>4</sup> and the boiling involved in making the curry resulted in an amelioration of the toxic effects, both in the severity of symptoms, and in the time delay until presentation.

Accidental ingestion of water hemlock most commonly occurs by mistaken identification, particularly differentiation from water parsnip as in this case. The majority of cases reported have involved children and young adults.<sup>4-8</sup> The mortality rate is quantity dependent, but has been reported as between 30%–70%.<sup>2, 8</sup>

The clinical features that have been previously reported include nausea, increased salivation, and vomiting. There may be tremor, abdominal cramps, and diarrhoea. Grand mal seizures and opisthotonus can rapidly develop, which may be attributable to antagonism of an inhibitory transmitter in the brain stem. Blood pressure falls, pupils normally dilate, and electrolyte imbalances occur. The latter includes high sodium and potassium and creatinine, a lymphocytosis and very low sodium bicarbonate levels. Increased muscular activity and damage results in a metabolic acidosis.<sup>6, 8</sup> Acute renal failure secondary to rhabdomyolysis has been reported.<sup>8, 9</sup>

Treatment is symptomatic. If vomiting has not occurred before seeking medical advice, which is unlikely, then the stomach should be emptied. Control of seizures is best performed using intravenous diazemules.<sup>10, 11</sup> Phenytoin would be the second line drug of choice. Thiopentone sodium has been recommended for seizure control because of its faster action. Treatment for resistant seizures may necessitate intubation and ventilation.

This episode highlighted some difficulties that can relate to plant poisoning. In this case the cause of the poisoning was not readily apparent, but with the assistance of the local police we were able to locate a plant specimen, and use a local botanist to aid identification. This facilitated an appropriate management strategy, although in this case the treatment was

supportive. As a result of this the hospital has now invested in specific resources that relate to plant poisoning, and people in the community who have expertise in plant identification have been identified, and have agreed to be contacted in the event of suspected poisoning. A copy of this list has been distributed to local general practitioners and the police.

It is possible that with increasing interest in “natural” foods accidental poisoning of this nature may become more frequent. These cases illustrate the potential dangers of this, but highlight the fact that even in small communities expertise is available and if accessed appropriately can be invaluable.

.....  
**Authors' affiliations**

**C Downs, J Phillips, A Ranger**, The Mid Argyll Hospital, Lochgilphead, Argyll PA31 8LU, UK

**L Farrell**, Scottish Natural Heritage, Lochgilphead, Argyll

Correspondence to: Dr C Downs; chrisdowns69@hotmail.com

Accepted for publication 31 January 2002

## REFERENCES

- 1 **Cooper MR**, Johnson AW. *Poisonous plants and fungi. An illustrated guide*. Ministry of Agriculture, Fisheries and Food. London: The Stationery Office, 1998.
- 2 **Ball MJ**, Flather ML, Forfar JC. Hemlock water dropwort poisoning. *Postgrad Med J* 1987;**63**:363–5.
- 3 **Tutin TG**. *Umbellifers of the British Isles*. Handbook Number 2. London: Botanical Society of the British Isles, 1980.
- 4 **O'Mahony S**, Fitzgerald P, Whelton MJ. Poisoning by hemlock water dropwort. *Ir J Med Sci* 1987;**156**:241.
- 5 **Lavar M**, Cole FR, Nelson RB. Water-hemlock poisoning. [Letter]. *N Engl J Med* 1969;**281**:566–7.
- 6 **Heath KB**. A fatal case of apparent water hemlock poisoning. *Yet Human Toxicol* 2001;**43**:35–6.
- 7 **Mitchell MI**, Routledge PA. Poisoning by hemlock water dropwort. [Letter]. *Lancet* 1977;**1**:423–4.
- 8 **Knutsen OH**, Paszkowski P. New aspects in the treatment of water hemlock poisoning. *Clin Toxicol* 1984;**22**:157–66.
- 9 **Carlton BE**, Tufts E, Girard DE. Water hemlock poisoning complicated by rhabdomyolysis and renal failure. *Clin Toxicol* 1979;**14**:87–92.
- 10 **Mack RB**. Keats, Socrates and fool's parsley—water hemlock poisoning. *N Carolina Med J* 1985;**3**:163–4.
- 11 **National Poisons Information Service**. The primary clinical toxicology database of the National Poisons Information Service.



# Histamine fish poisoning: a common but frequently misdiagnosed condition

R R Attaran, F Probst

Emerg Med J 2002;19:474-475

Scombrototoxic or histamine fish poisoning is a common condition normally associated with consuming spoiled tuna, mackerel, bonito, or skipjack. Typical symptoms like flushing, urticaria, and palpitations mimic those of allergy so histamine fish poisoning can easily be misdiagnosed. Diagnosis is often clinical and the mainstay of treatment is antihistamines.

## Key points

- Common though frequently missed.
- Normally associated with tuna.
- Not an allergic reaction but features similar to allergy.
- No prior or subsequent reaction to the fish.
- Treated with antihistamines.
- Notifiable.

## CASE REPORT 1

A 37 year old woman presented to accident and emergency (A&E) having consumed yellow-fin tuna. Within 20 minutes she had developed an urticarial rash on her face, neck, and trunk with chest tightness. She had no history of hypersensitivity and normally consumed tuna on a weekly basis.

On arrival she was tachycardic and tachypnoeic, had mild facial angio-oedema but no wheeze. She was seen immediately by a registrar who diagnosed a hypersensitivity reaction and administered intramuscular adrenaline (epinephrine), intravenous hydrocortisone, and chlorpheniramine.

The patient's symptoms improved within 30 minutes and after a further six hour observation period, was discharged home on a short course of oral corticosteroids.

The patient subsequently underwent a RAST (Radio Allergic Sorbet Test) to various potential culprits including tuna, all of which were negative.

## CASE REPORT 2

Four men and one woman (mean age 32; range 25 to 42) arrived together at A&E having all consumed tuna at a restaurant. About 15 minutes after ingestion all had begun to experience generalised urticaria, palpitations, and felt hot. None had a history of urticaria or hypersensitivity.

On arrival three of five patients were tachycardic and tachypnoeic. Erythema was noted over all their faces and trunk. The concurrent presentation of five such cases to A&E roused the suspicion of the attending registrar who diagnosed histamine fish poisoning.

All were treated with the antihistamine chlorpheniramine orally with symptoms resolving within two hours. One required nebulised bronchodilators.

## CASE REPORT 3

A 27 year old woman presented an hour after consuming tuna at home. She had eaten from the same batch two days previously, when she had developed some urticaria and flushing but they had resolved within three hours. On the second occasion her symptoms had been more pronounced and included chest tightness and angio-oedema of the lower lip.

The patient was treated for hypersensitivity. Intravenous hydrocortisone, chlorpheniramine, and fluids were administered. The patient was discharged later the same day after resolution of symptoms. Again this patient had no history of hypersensitivity to tuna or any other seafood.

## DISCUSSION

Scombrototoxic or histamine fish poisoning (HFP) is a common seafood-borne disease. Between 1992 and 1999, 10% of the

infectious intestinal disease outbreaks reported to the Communicable Disease Surveillance Centre were associated with fish, about half of those to HFP.<sup>1</sup> It is the most common cause of seafood poisoning in the USA.<sup>2</sup> A variety of factors, including misdiagnosis, result in its underreporting.<sup>3</sup>

Spoiled oily fish of the families *Scombridae* and *Scomberesocidae* (especially tuna, mackerel, bonito, and skipjack) are common but not the only culprits.<sup>4</sup> In these fish, bacterial histidine decarboxylase converts muscle histidine into histamine.<sup>5,6</sup> Bacterial activity is increased at raised temperatures so poor storage conditions exacerbate the problem.<sup>7</sup> Cooking can destroy the bacteria but not the histamine.<sup>8</sup> The gradual build up in toxicity of spoiled fish could be demonstrated by case 3 where a 48 hour period separated a mild from a severe reaction.

Whether HFP is purely a result of histamine effect is unclear.<sup>4,9-11</sup> None the less, signs and symptoms are essentially those of histamine toxicity: flushing, urticaria, abdominal cramps, headache, palpitations, diarrhoea, nausea, and vomiting.<sup>12-15</sup> These can begin within minutes of ingestion and typically last several hours.<sup>12,16</sup>

Diagnosis is often clinical, though the fish specimen can be assayed for histamine levels. The patient will typically have not had a reaction to that fish before. In a group of people consuming the contaminated fish, more than one person will probably be affected, perhaps all.<sup>15</sup> Skin allergy testing using fresh samples from the same fish can help exclude hypersensitivity.

The treatment of HFP is not too different from that of a hypersensitivity reaction. Symptomatic relief can be achieved by the use of antihistamines such as H<sub>1</sub> and H<sub>2</sub> histamine receptor antagonists.<sup>4,16,17</sup> Occasionally salbutamol and adrenalin may also be warranted. Corticosteroids are generally not indicated.<sup>18</sup>

In October 2001 alone, four such episodes of HFP were seen in the St Thomas' Hospital A&E Department, three of which have been reported here. In all but one (case 2) the diagnosis was missed.

HFP is a common self limiting condition sharing features with that of allergy, such as flushing, urticaria, and palpitations. Physicians must be aware of HFP as it is notifiable to the local Communicable Disease Centre and patients can be reassured that they have probably not had an allergic reaction.

## Authors' affiliations

R R Attaran, F Probst, Accident and Emergency Department, Guy's and St Thomas' NHS Trust, London, UK

Correspondence to: Dr F Probst, Accident and Emergency Department, St Thomas' Hospital, London SE1 7EH, UK

## REFERENCES

- 1 Gillespie IA, Adak GK, O'Brien SJ, *et al.* General outbreaks of infectious intestinal disease associated with fish and shellfish, England and Wales, 1992–1999. *Commun Dis Public Health* 2001;**4**:117–23.
- 2 Lipp EK, Rose JB. The role of seafood in foodborne diseases in the United States of America. *Rev Sci Tech* 1997;**16**:620–40.
- 3 Wu ML, Yang CC, Yang GY, *et al.* Scombroid fish poisoning: an overlooked marine food poisoning. *Vet Hum Toxicol* 1997;**39**:236–41.
- 4 Taylor SL. Histamine food poisoning: toxicology and clinical aspects. *CRC Crit Rev Toxicol* 1986;**17**:91–128.
- 5 Ferencik M. Formation of histamine during bacterial decarboxylation of histidine in the flesh of some marine fishes. *J Hygiene Epidemiol Microbiol Immunol* 1970;**14**:52–60.
- 6 Lopez-Sabater EI, Rodriguez-Jerez JJ, Hernandez-Herrero M, *et al.* Incidence of histamine-forming bacteria and histamine content in scombroid fish species from retail markets in the Barcelona area. *Int J Food Microbiol* 1996;**28**:411–18.
- 7 Behling AR, Taylor SL. Bacterial histamine production as a function of temperature and time of incubation. *J Food Sci* 1982;**47**:1311–14.
- 8 Etkind P, Wilson ME, Gallagher K, *et al.* Bluefish-associated scombroid poisoning. An example of the expanding spectrum of food poisoning from seafood. *JAMA* 1987;**258**:3409–10.
- 9 Taylor SL, Sumner SS. Determination of histamine, putrescine, and cadaverine. In: Kramer DE, Liston J, eds. *Seafood quality determination*. Amsterdam: Elsevier, 1986:235–45.
- 10 Bjeldanes LF, Schutz DE, Morris MM. On the aetiology of scombroid poisoning: cadaverine potentiation of histamine toxicity in the guinea pig. *Food Cosmetic Toxicol* 1978;**16**:157–9.
- 11 Lyons DE, Beery JT, Lyons SA, *et al.* Cadaverine and aminoguanidine potentiate the uptake of histamine *in vitro* in perfused intestinal segments of rats. *Toxicol Appl Pharmacol* 1983;**70**:445–58.
- 12 Gilbert RJ, Hobbs G, Murray CK, *et al.* Scombrototoxic fish poisoning: features of the first 50 incidents to be reported in Britain. *BMJ* 1980;iii:71–2.
- 13 Morrow JD, Margolies GR, Rowland J, *et al.* Evidence that histamine is the causative toxin of scombroid-fish poisoning. *N Engl J Med* 1991;**324**:716–20.
- 14 Cruickshank JG, Williams HR. Scombrototoxic fish poisoning. *BMJ* 1978;iii:739–40.
- 15 Arnold SH, Brown WD. Histamine toxicity from fish products. *Adv Food Res* 1978;**34**:113–54.
- 16 Blakesley ML. Scombroid poisoning: prompt resolution of symptoms with cimetidine. *Ann Emerg Med* 1983;**12**:104–6.
- 17 Brown C. Scombroid poisoning. [Letter]. *Med J Aust* 1993;**158**:435–6.
- 18 Smart D. Scombroid poisoning. *Med J Austral* 1992;**157**:748–51.

# Sudden visual loss after closed head injury

S Brady

*Emerg Med J* 2002;**19**:475–476

This is a report of a case of traumatic optic neuropathy after minor head injury: a rare cause of sudden visual loss after trauma. The aetiology and management are discussed.

A 35 year old man presented to the emergency department after a fall of approximately six feet from a ladder. A witness confirmed loss of consciousness for a period of one to two minutes. He had no past medical history of note and had no visual problems before the fall.

On arrival in the emergency department the patient was complaining of severe headache, nausea, and poor vision in his right eye.

On examination the primary survey was normal and his GCS was 15. Secondary survey revealed a small occipital haematoma, but no evidence of injury to the face. Eye movements and fundi were normal. Visual acuity in the left eye was 6/6 with a normal pupillary response to light, but visual acuity in the right eye was 6/60 with a right afferent pupillary defect. The remainder of the secondary survey was normal.

Computed tomography of brain and orbits showed an undisplaced fracture through the floor of the right optic canal with no narrowing of the canal itself. It also showed an undisplaced fracture involving the greater wing of the right sphenoid extending into the lateral wall of the sphenoid sinus. There was no haematoma of the soft tissues of the right orbit.

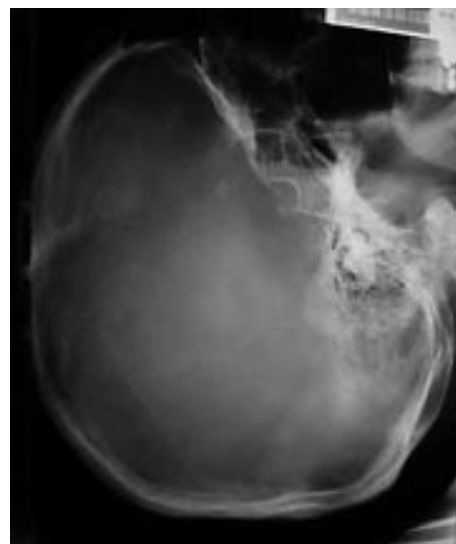The skull radiograph (fig 1) and relevant CT scan (fig 2) are shown.

He was referred to ophthalmology and a diagnosis of traumatic optic neuropathy was made. He was treated with high dose methylprednisolone using the National Spinal Cord Injury Study protocol.<sup>1</sup> On discharge visual acuity in the right eye remained 6/60 and follow up at one month showed no improvement.

## DISCUSSION

This phenomenon was first described by Hippocrates over 2000 years ago. It was defined by Walsh and Hoyt as “traumatic loss of vision without external or initial ophthalmoscopic evidence of injury to the eye or its nerve”.<sup>2</sup> In closed head injury the incidence is approx. 0.5% to 5% and is more common with frontal impact.<sup>3</sup> Spontaneous recovery of vision occurs in less than 50%.<sup>3</sup>

The optic nerve can be divided into the intraocular portion and the intraorbital/intracranial portion. Direct impact to the eye affects the intraocular portion and immediate loss of vision suggests laceration, avulsion, or severe contusion of the



**Figure 1** Skull radiograph showing the fluid level in the sphenoid sinus.

nerve, which normally results in ischaemic necrosis and permanent blindness. Indirect impact, as in this case, affects the nerve proximal to the intraocular portion. The force is transmitted to the optic nerve and vascular supply and there are three potential mechanisms of visual loss:

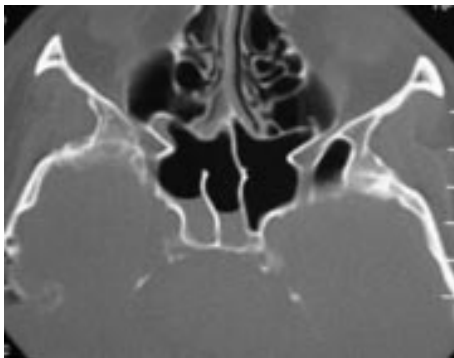
- Nerve injury: direct or indirect
- Vascular supply can be occluded, severed, or compromised by spasm
- Compression of the vascular supply or nerve

Immediate visual loss tends to occur with the first two mechanisms and is normally irreversible. However, focal concussive injury of the optic nerve may result in immediate visual loss and this may improve. Compression of the nerve or vascular supply more commonly presents as delayed and progressive visual loss and this is potentially reversible.<sup>4</sup> These mechanisms may overlap and it is therefore important to search for potentially reversible causes.

There are three management options:

- No intervention
- Intravenous methylprednisolone
- Surgical decompression

The use of methylprednisolone is based on the results of the second National Acute Spinal Cord Injury Study.<sup>1</sup> Methylprednisolone is thought to have antioxidant properties, thus limiting free radical damage. It also believed to reduce traumatic oedema and limit vasospasm. However, there is no conclusive



**Figure 2** Computed tomography of the brain showing fluid in sphenoid and ethmoid sinuses and the fracture of the sphenoid wing.

evidence of significant benefit in cases of traumatic optic neuropathy.<sup>5,6</sup>

Surgical decompression is believed to reduce oedematous compression of the optic nerve and vascular supply within the optic canal. Again, there is no conclusive evidence of benefit in the empirical treatment of traumatic optic neuropathy by surgical decompression.<sup>5,6</sup>

The main problem in management seems to be the diversity of aetiologies, which precludes one definitive treatment for all cases. Unfortunately the International Optic Nerve Trauma Study failed to recruit enough patients to continue as a randomised controlled trial and thus the debate on treatment continues.

As prognosis is poor, each case should be judged individually and the management discussed with a specialist.

Emergency department management:

- Recognition of the problem
- Prompt discussion with an ophthalmology specialist
- Early computed tomography to define the exact nature of the injury and identification of those patients who may benefit from surgical intervention, for example, optic canal fractures with bony impingement and/or severe swelling.
- Commencement of intravenous methylprednisolone in the emergency department if recommended by a specialist.

#### Author's affiliations

**S Brady**, Accident and Emergency Department, Poole General Hospital, Longfleet Road, Poole, Dorset BH15 2JB, UK

Correspondence to: Miss S Brady; [suzannebrady@ukonline.co.uk](mailto:suzannebrady@ukonline.co.uk)

Accepted for publication 31 January 2002

#### REFERENCES

- 1 **Braken MB**, Shepard MJ, Collins WF, *et al.* A randomised controlled trial of methylprednisolone or naloxone in the treatment of acute spinal cord injury. Results of the second national acute spinal cord injury study. *N Engl J Med* 1990;**322**:1405–11.
- 2 **Walsh FB**, Hoyt WF. In: Miller NR, Newman NJ, eds. *Clinical neuro-ophthalmology*. 3rd edn. Baltimore: Williams and Wilkins, 1998:715–39.
- 3 **Steinsapir KD**, Goldberg RA. Traumatic optic neuropathy. *Surv Ophthalmol* 1994;**38**:487–518.
- 4 **Frenkel RE**, Spoor TC. Diagnosis and management of traumatic optic neuropathies. *Adv Ophthalmic Plast Reconstruct Surg* 1987;**6**:71–90.
- 5 **Levin LA**, Beck RW, Joseph MP, *et al.* The treatment of traumatic optic neuropathy. The international optic nerve trauma study. *Ophthalmology* 1999;**106**:1268–77.
- 6 **Steinsapir KD**. Traumatic optic neuropathy. *Curr Opin Ophthalmol* 1999;**10**:340–2.

# Fascicular tachycardia: uncommon or just unrecognised?

C A Eynon, L Howe, S Firoozan

*Emerg Med J* 2002;19:477-478

**B**road complex tachycardias present a diagnostic and therapeutic challenge to the emergency physician. The majority of cases are ventricular tachycardias (VT) resulting from underlying ischaemic heart disease.<sup>1,2</sup> Broad complex tachycardias may also occur as a result of a supraventricular tachycardia (SVT) in the presence of aberrant conduction. Differentiation has important implications in terms of management and prognosis. If VT is mistakenly diagnosed as SVT with aberrant conduction and treated with calcium channel blockers, the patient is likely to become haemodynamically unstable.<sup>3</sup> Some clinicians therefore advocate assumption that all cases of broad complex tachycardia are VT.<sup>4</sup>

Fascicular tachycardia is a distinct subgroup of idiopathic VT that may be confused with either typical VT or SVT.<sup>5,6</sup> Although well recognised by cardiologists, there is only a single report in the emergency medicine literature.<sup>7</sup> It is characterised by the absence of structural heart disease and classic electrocardiographic and electrophysiological features.<sup>5,8,9</sup> Vagal manoeuvres and adenosine are ineffective in suppressing fascicular tachycardia.<sup>5,8,10</sup> It is also unresponsive to the standard pharmacological treatments, such as lignocaine (lidocaine), used for VT associated with coronary artery disease.<sup>5,8</sup> In contrast, it is terminated or suppressed by calcium antagonists.<sup>5,6,8,9,11</sup>

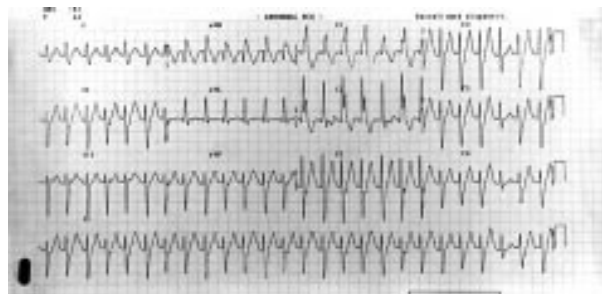
## CASE REPORT

A 29 year old man presented to the emergency department for evaluation of rapid palpitations and pre-syncope. This had started two hours before presentation. He had experienced one similar episode 18 months previously that had responded to medical treatment. No old notes were available and he could not recall which drugs he had been given. He had no other medical history and was on no regular medication. He was a non-smoker, drank less than 10 units of alcohol per week, and denied illicit drug use. Consumption of tea, coffee, or caffeinated drinks was minimal.

On examination he was afebrile, heart rate 140 bpm, blood pressure 110/80 mm Hg. The remaining physical examination was unremarkable.

A lead II rhythm strip showed a broad complex tachycardia with a QRS duration of 140 ms. A lead III rhythm strip showed an apparent narrow complex tachycardia with a QRS duration of 90 ms. A 12 lead ECG revealed a wide QRS complex tachycardia with a right bundle branch block morphology and left axis deviation (fig 1). Capture beats were present. Immediate cardiology consultation was sought and a diagnosis of fascicular tachycardia was made. Intravenous verapamil 5 mg was administered with slowing and then cessation of the tachycardia. A 12 lead ECG performed immediately after cessation of the tachycardia showed reversion to a normal pattern.

Transthoracic echocardiography revealed no structural abnormality and good ventricular function. Subsequent review of the patient's old notes, showed that on his previous admission he had been treated with adenosine and lignocaine prior to the correct diagnosis being made. The patient was discharged from the emergency department with cardiology follow up.



**Figure 1** A 12 lead ECG showing broad complex tachycardia with right bundle branch block morphology and left axis deviation. The QRS duration is 140 ms in lead II and 90 ms in lead III. A capture beat is present.

## DISCUSSION

The diagnosis of fascicular tachycardia is difficult in the setting of the emergency department. Patients are generally young with no evidence of structural heart disease. The arrhythmia may mimic both SVT and VT. Capture beats and fusion beats may be present on the 12 lead ECG suggesting the diagnosis of VT rather than SVT. In this patient, the lead III rhythm strip was consistent with SVT while the lead II rhythm strip pointed towards VT. The width of the QRS complex should be determined by examining the lead where it appears broadest on the 12 lead ECG. The correct diagnosis was suggested by the presence of a broad complex tachycardia with a right bundle branch block morphology and left axis deviation.<sup>5,6,8,9</sup> The QRS duration in fascicular tachycardia can vary from 100 to 140 ms.<sup>6,9</sup> The RS interval is uniformly <80 ms in contrast with VT associated with structural heart disease where the RS interval is generally >100 ms.<sup>9</sup> After reversion to sinus rhythm, non-specific ST segment and T wave changes may be seen, most commonly in the inferior or lateral chest leads.<sup>5,6</sup>

The tachycardia is thought to originate as a re-entrant mechanism located in the posterior fascicle of the left bundle branch.<sup>5,6,9-11</sup> This theory is supported by the ease with which the tachycardia can be initiated and terminated by pacing.<sup>6</sup> In some patients a false tendon has been found extending from the posterior-inferior free wall of the left ventricle to the left ventricular septum.<sup>12</sup> Conduction via the free tendon or stretching of the Purkinje fibres in the inter-ventricular septum may induce the tachycardia in these patients.

The pharmacological treatment of choice for fascicular tachycardia is intravenous verapamil.<sup>5,6,8,9,11,13</sup> The dramatic response to calcium channel block can again lead to misdiagnosis of SVT.<sup>6</sup> Sotalol and amiodarone have also been reported to be effective.<sup>14</sup> Vagal manoeuvres, adenosine, lignocaine, and propranolol have no effect.<sup>5,8,10</sup> Recurrences may be prevented by long term, oral verapamil.<sup>8,11</sup> Radiofrequency ablation has been reported to be successful in selected patients.<sup>15</sup>

In the emergency department, a broad complex tachycardia should be presumed to be VT in association with ischaemic or structural heart disease. If standard methods fail to convert the arrhythmia and the 12 lead ECG shows a right bundle branch block picture with left axis deviation, a diagnosis of fascicular tachycardia should be considered. If the diagnosis is confirmed, intravenous verapamil is the treatment of choice.

### Contributors

All three authors saw the patient and contributed to his management in the emergency department. Laura Howe and Soroosh Firoozan collected related material and edited the paper. Andrew Eynon wrote the paper and will act as guarantor.

### Authors' affiliations

**C A Eynon, L Howe**, Department of Accident and Emergency, John Radcliffe Hospital, Oxford, UK

**S Firoozan**, Department of Cardiological Science, John Radcliffe Hospital

Correspondence to: Dr C A Eynon, Wexham Park Hospital, Slough SL2 4HL, UK; AndyEynon@aol.com

Accepted for publication 21 January 2002

### REFERENCES

- 1 **Akhtar M**, Shenasa M, Jazayeri M, et al. Wide QRS complex tachycardia: reappraisal of a common clinical problem. *Ann Intern Med* 1988;**109**:905–12.
- 2 **Steinmann RT**, Herrera C, Schuger CD, et al. Wide QRS tachycardia in the conscious adult: ventricular tachycardia is the most frequent cause. *JAMA* 1989;**261**:1013–16.
- 3 **Stewart RB**, Bardy GH, Greene HL. Wide complex tachycardia: misdiagnosis and outcome after emergent therapy. *Ann Intern Med* 1986;**104**:766–71.
- 4 **Griffith MJ**, Garratt CJ, Mounsey P, et al. Ventricular tachycardia as default diagnosis in broad complex tachycardia. *Lancet* 1994;**343**:386–8.
- 5 **Lin FC**, Finley CD, Rahimtoola SH, et al. Idiopathic paroxysmal ventricular tachycardia with a QRS pattern of right bundle branch block and left axis deviation: a unique clinical entity with specific properties. *Am J Cardiol* 1983;**52**:95–100.
- 6 **Ward DE**, Nathan AW, Camm AJ. Fascicular tachycardia sensitive to calcium antagonists. *Eur Heart J* 1984;**5**:896–905.
- 7 **Elswick BD**, Niemann JT. Fascicular ventricular tachycardia: an uncommon but distinct ventricular tachycardia. *Ann Emerg Med* 1998;**31**:406–9.
- 8 **Ohe T**, Shimomura K, Aihara N, et al. Idiopathic sustained left ventricular tachycardia: clinical and electrophysiologic characteristics. *Circulation* 1988;**77**:550–68.
- 9 **Andrade FR**, Eslami M, Elias J, et al. Diagnostic clues from the surface ECG to identify idiopathic (fascicular) ventricular tachycardia: correlation with electrophysiologic findings. *J Cardiovasc Electrophysiol* 1996;**7**:2–8.
- 10 **Griffith MJ**, Garratt CJ, Rowland E, et al. Effects of intravenous adenosine on verapamil-sensitive "idiopathic" ventricular tachycardia. *Am J Cardiol* 1994;**73**:759–64.
- 11 **Ohe T**. Idiopathic verapamil-sensitive sustained left ventricular tachycardia. *Clin Cardiol* 1993;**16**:139–41.
- 12 **Thakur RK**, Klein GJ, Sivaram CA, et al. Anatomic substrate for idiopathic left ventricular tachycardia. *Circulation* 1996;**93**:497–501.
- 13 **Belhassen B**, Shapira I, Pellg A, et al. Termination of idiopathic recurrent sustained ventricular tachycardia with a right bundle branch block pattern and left axis deviation by verapamil. Report of three cases. In: Levy S, Gerard R, eds. *Recent advances in cardiac arrhythmias*. London: John Libbey, 1983:349–53.
- 14 **Akhtar M**. Clinical spectrum of ventricular tachycardia. *Circulation* 1990;**82**:1561–73.
- 15 **Gonzalez RP**, Scheinmann MM, Lesh MD, et al. Clinical and electrophysiologic spectrum of fascicular tachycardias. *Am Heart J* 1994;**128**:147–56.

# Dead? Or just cold: profoundly hypothermic patient with no signs of life

C S Ko, J Alex, S Jeffries, J M Parmar

*Emerg Med J* 2002;**19**:478–479

A 37 year old man was found in his garden cold with no signs of life. Pupils were fixed and dilated. Electrocardiography showed asystole initially. The paramedic crew started cardiopulmonary resuscitation and transferred him to the accident and emergency department. His temperature was 17.0°C. Cardiopulmonary resuscitation was continued for three hours before rewarming using partial cardiopulmonary bypass. He eventually regained spontaneous cardiac output and made a full neurological recovery. Hypothermic patients with no evidence of life cannot be assumed to be dead as there is a chance of full recovery when fully warmed.

The chance discovery of a hypothermic patient with no signs of life poses the question whether the patient got cold after death or is just cold but potentially salvageable. The decision taken can lead to either unnecessary prolonged and expensive resuscitation or loss of a life with potential to a full recovery. This is especially difficult when the ambient temperature is not near freezing. The cooling process is much slower with greater risk of neurological damage. We report a case of profound hypothermia secondary to accidental exposure successfully resuscitated with femoro-femoral partial bypass.

Late one evening in March at 2100 hours, a 37 year old man was found in his garden cold and unresponsive with no signs

of life. The ambient temperature was 6°C ([www.weatheronline.co.uk](http://www.weatheronline.co.uk)). The paramedic crew arrived at 2106 hours. The patient's tympanic temperature was 17.0°C and electrocardiography showed asystole. The patient was intubated, ventilated, and external cardiac massage was started. He was given 1 mg of adrenaline (epinephrine) and developed pulseless electrical activity, which degenerated into ventricular fibrillation five minutes later. Two 200 J cardioversions had no effect.

In the accident and emergency department the patient was recognised as one with a history of schizophrenia, substance misuse, and previous admissions with overdose and alcohol intoxication. Further cardioversion with 360 J was unsuccessful. Pupils were fixed and dilated. Arterial blood gases showed pH of 6.9, Po<sub>2</sub> of 4.7 and Pco<sub>2</sub> of 9.9.

The prevailing feeling at the time was that he had been dead for some time before being discovered, but it was not possible to rule out potential recovery. External cardiac massage was continued and he was transferred to the operating theatre for rewarming on cardiopulmonary bypass.

The patient was anaesthetised and heparinised (3 mg/kg). The right femoral artery and vein were cannulated using a 17 French gauge arterial cannula and a 21 French gauge venous cannula (Medtronic Cardiac Surgical, Grand Rapids, MI, USA). Partial bypass with flow rates of between 2.2–2.8 l/min and mean perfusion pressure of 54–60 mm Hg was achieved. Full bypass with sternotomy was felt to be excessive.

With the nasopharyngeal temperature at 30°C, cardioversion with 200 J resulted in sinus rhythm for a few seconds before reverting to ventricular fibrillation. Eight further

attempts with up to 360 J were also unsuccessful despite administration of amiodarone as per the Advanced Life Support protocol, intravenous lignocaine (lidocaine), and intravenous bretylium. After having been on bypass for an hour his nasopharyngeal temperature was 37°C. The heart regained sinus rhythm spontaneously and started ejecting achieving mean blood pressure of 80–100 mm Hg. He was maintained on partial bypass for another hour until his peripheries had warmed up before weaning off cardiopulmonary bypass on low dose adrenaline infusion.

The initial recovery was marred by adult respiratory distress syndrome. He was extubated a week later and was treated for alcohol withdrawal syndrome. He discharged himself against medical advice after another week.

## COMMENT

Accidental hypothermia from immersion or exposure is a well recognised cause of cardiorespiratory arrest in regions with icy winters. Resuscitation with cardiopulmonary bypass with full recovery is possible but mortality remains high at 53% to 80%.<sup>1,2</sup> In Hauty's report, no patients with absence of signs of life initially survived.<sup>2</sup> The two survivors had core temperatures of 22.0°C and 23.4°C with some consciousness when discovered. In such cases immediate resuscitation ensures that organ perfusion, especially to the brain, is maintained.

Only two cases of hypothermia treated successfully with cardiopulmonary bypass have been reported from the United Kingdom.<sup>3,4</sup> Both were responsive to stimuli initially with subsequent cardiorespiratory arrest. Rewarming was with extracorporeal circulation. The first patient made a full recovery and the second died of a cerebrovascular accident 48 hours after admission.

Our patient had no signs of life on discovery. The ambient temperature was far from freezing. It would have taken him longer to cool to 17°C. He could have been severely brain damaged if revived. We had no toxicological record but he could have been under the influence of alcohol or drugs that increased the cooling process. We were faced with a patient who could have been dead from intracranial catastrophe, fatal overdose, or asphyxiation. The  $P_{O_2}$  was 4.7 with severe acidosis. Altogether he had five poor prognostic indicators.<sup>2</sup> The decision to proceed to rewarm him was based on the adage

that "Not dead until warm and dead" and the fact that with resuscitation the heart showed pulseless electrical activity followed by ventricular fibrillation rather than persistent asystole. The patient's apparent full recovery lends support to the rationale.

We are aware that this patient may be an exception. Many patients discovered cold with no signs of life are presumed dead. In a small number of patients, the decision to proceed to resource intensive rewarming with cardiopulmonary bypass is probably worth taking if there is evidence of cardiac electrical activity. Partial femoro-femoral bypass is preferred in such circumstances.

## Contributors

Chung Ko did the literature review and wrote the paper. Joseph Alex helped with the literature review and contributed to the paper. Stephen Jeffries helped with the perfusion related aspect of the paper. Jitendra Parmar discussed the core idea, revised the drafts and will act as guarantor for the paper.

## Authors' affiliations

**C S Ko, J Alex, J M Parmar**, Department of Cardiothoracic Surgery, North Staffordshire Hospitals, Royal Infirmary, Princes Road, Stoke on Trent ST4 7LN, UK

**S Jeffries**, Department of Clinical Perfusion, North Staffordshire Hospitals, Royal Infirmary, Stoke on Trent

Correspondence to: Mr J M Parmar;  
Jitendra.Parmar@nstaffsh.wmids.nhs.uk

Accepted for publication 31 January 2002

## REFERENCES

- 1 Walpoth BH, Walpoth-Aslan BN, Mattle HP, *et al.* Outcome of survivors of accidental deep hypothermia and circulatory arrest treated with extracorporeal blood warming. *N Engl J Med* 1997;**337**:1500–5.
- 2 Hauty MG, Esrig BC, Hill JG, *et al.* Prognostic factors in severe accidental hypothermia: experience from the Mt. Hood tragedy. *J Trauma* 1987;**27**:1107–12.
- 3 Jones AI, Swann IJ. Prolonged resuscitation in accidental hypothermia: use of mechanical cardio-pulmonary resuscitation and partial cardio-pulmonary by-pass. *Eur J Emerg Med* 1994;**1**:34–6.
- 4 Steedman DJ, Rainer T, Campanella C. Cardiopulmonary resuscitation following profound immersion hypothermia. *J Accid Emerg Med* 1997;**14**:170–2.

# Urgent contrast enhanced computed tomography in the diagnosis of acute bowel infarction

L R Gellett, S R Harries, C A Roobottom

*Emerg Med J* 2002;19:480-481

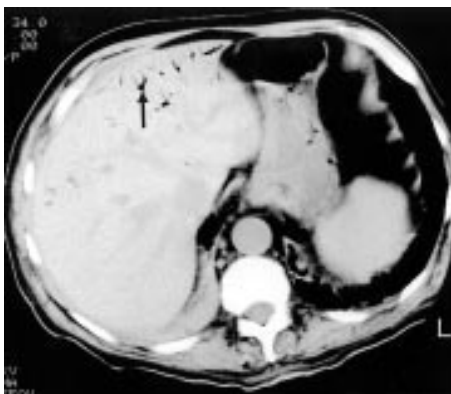
Bowel infarction commonly presents as an acute abdomen that rapidly progresses to severe shock. The diagnosis is often not clinically suspected. Three cases are described where the diagnosis was made during dynamic contrast enhanced computed tomography (CT), when gas was demonstrated in the portal venous system and liver. Two patients died during surgery, the third survived because of the prompt diagnosis made on CT, and subsequent surgical treatment. The radiological findings are reviewed.

## CASE 1

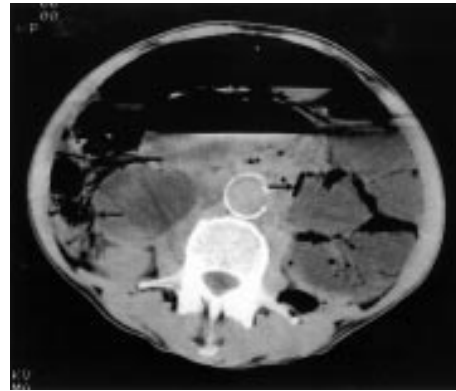
A 72 year old man presented with a three week history of anorexia and worsening epigastric pain. Over the next five days the severity of his abdominal pain increased and was associated with rebound tenderness and active bowel sounds. Plain abdominal radiography, amylase and white cell count (WCC) were normal. Computed tomography (CT) was eventually performed and this showed extensive gas within the portal venous system (fig 1). At operation the distal small bowel was found to be ischaemic. The patient died shortly after surgery.

## CASE 2

A 52 year old female patient was admitted with sudden onset generalised abdominal pain and diarrhoea. On examination she was hypotensive and tachycardic, with abdominal peritonism. Laboratory investigation revealed a raised WCC, and abdominal radiography demonstrated multiple gas filled loops of bowel. CT 24 hours after admission demonstrated gas within the portal venous system, superior mesenteric vein (SMV) and throughout the walls of the large bowel and terminal ileum (fig 2). The patient died during surgery and a postmortem examination revealed luminal thrombus within the superior mesenteric artery (SMA) and associated small bowel and right colonic infarction.



**Figure 1** Contrast enhanced CT through the upper abdomen shows peripheral branching gas densities in the distribution of the left portal vein (black arrow).



**Figure 2** CT demonstrating extensive gas throughout the walls of the large bowel and terminal ileum (black arrows).

## CASE 3

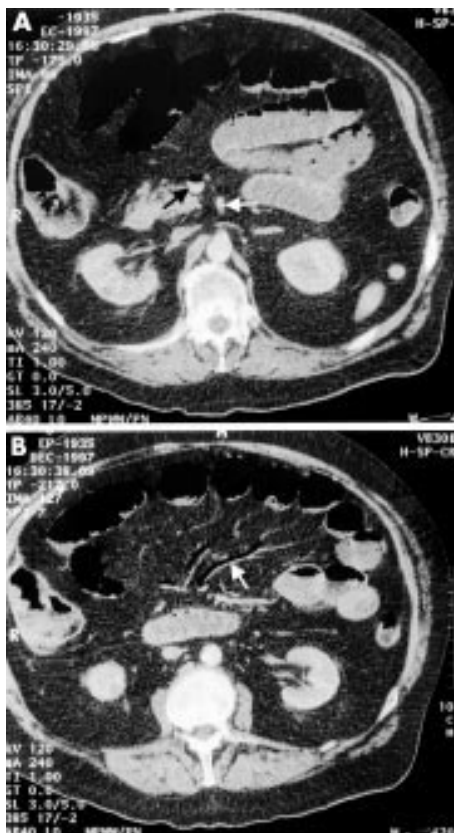
A 62 year old man was admitted to hospital for control of his warfarinisation, with an INR >10. He developed sudden onset lower abdominal pain and bright red blood per rectum five days after admission, with tenderness in his right iliac fossa and absent bowel sounds. Investigation revealed a raised WCC. Abdominal radiography demonstrated small bowel dilatation with separation of the loops. CT was performed immediately for a suspected retroperitoneal bleed. This demonstrated air in the small bowel wall and SMV (figs 3A and 3B). At operation infarction of the upper jejunum was found. The patient made a full recovery.

## DISCUSSION

Bowel infarction is a common disorder that continues to be associated with a high mortality rate because of difficulties in making the diagnosis both clinically and radiologically. Plain abdominal film findings are usually normal or non-specific.<sup>1</sup> The demonstration of portal vein gas or intramural gas on plain film are highly specific but late findings seen in a small minority of patients. The demonstration of portal vein gas on plain film is associated with an overall mortality rate of 75% because of its association with bowel infarction.<sup>2</sup> Plain films in patients with suspected mesenteric infarction are therefore performed to exclude other causes for abdominal pain.

Contrast enhanced CT is increasingly being used in the examination of patients with severe abdominal pain of unknown aetiology, and bowel infarction is only one of a number of potential diagnoses. Non-specific CT findings in acute mesenteric ischaemia include bowel distension, bowel wall thickening, mesenteric oedema, and ascites. These findings are unfortunately also seen in a wide variety of other inflammatory, infective, and neoplastic conditions. Findings with a specificity of >95% on contrast enhanced CT include

**Abbreviations:** CT, computed tomography; WCC, white cell count; SMV, superior mesenteric vein; SMA, superior mesenteric artery



**Figure 3** (A) Post contrast CT demonstrating air fluid level within the SMV (black arrow) but no filling defect in the SMA (white arrow). (B) CT showing air within the mesenteric veins (white arrow).

SMA or SMV thrombus, intramural bowel gas, portal vein gas, focal lack of bowel wall enhancement and ischaemia of other organs.<sup>3</sup> The detection of at least one of these signs on contrast enhanced CT results in a sensitivity of 64% for the diagnosis of acute mesenteric ischaemia.<sup>3</sup>

Contrast enhanced CT is of value in clinical practice as bowel infarction is only one of a number of potential diagnoses. Careful evaluation of patient history and clinical examination in the emergency room should lead to a suspicion of mesenteric ischaemia. If the patient is to have any chance of survival, as was shown by the third case in our series, early referral for contrast enhanced CT is mandatory.

#### Contributors

Simon Harries and Carl Roobottom initiated the original idea for the paper and provided the index cases. Laura Gellett carried out the literature search and wrote the paper. Carl Roobottom made amendments to the original draft of the paper. All authors proof read the paper before submitting the manuscript for publication. Laura Gellett is the guarantor of the paper.

#### Authors' affiliations

**L R Gellett, S R Harries, C A Roobottom**, Department of Clinical Imaging, Derriford Hospital, Plymouth, Devon, UK

Correspondence to: Dr L R Gellett, Department of Radiology, Abdominal Division, Vancouver General Hospital, 899 West 12th Avenue, Vancouver, Canada V5Z 1M9; lauragellett@hotmail.com

Accepted for publication 29 October 2001

#### REFERENCES

- 1 **Smerud MJ**, Johnson CD, Stephens DH. Diagnosis of bowel infarction: a comparison of plain films and CT scans in 23 cases. *AJR* 1990;**154**:99–103.
- 2 **Liebman PR**, Patten MT, Manny J, *et al*. Hepatic-portal venous gas in adults: etiology, pathophysiology and clinical significance. *Ann Surg* 1978;**187**:281–7.
- 3 **Taourel PG**, Deneuille M, Pradel JA, *et al*. Acute mesenteric ischemia: diagnosis with contrast-enhanced CT. *Radiology* 1996;**199**:632–6.

## Pseudomyocardial infarction associated with a retrocaecal gangrenous appendix

**C Dewar, A Siddiqi, J Kayani**

*Emerg Med J* 2002;**19**:481–482

The case is presented of a 54 year old man who attended the emergency department with a history of central abdominal pain and electrocardiographic changes consistent with an anteroseptal myocardial infarction. Myocardial infarction was not confirmed with serial cardiac enzymes and a subsequent laparotomy revealed a gangrenous retrocaecal appendix. This case highlights the rare but recognised association between an acute surgical abdomen and pseudomyocardial infarction. It is, to the authors' knowledge, the first reported case of pseudomyocardial infarction complicating a retrocaecal appendicitis.

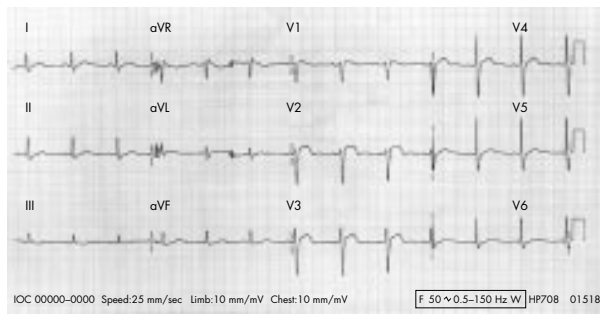
**A** 54 year old man self presented to the emergency department with a 12 hour history of central abdominal pain. The pain was described as dull in nature with no radiation; there was associated nausea but no vomiting. The patient

denied any previous similar episodes of pain. His only medical history of note was tinnitus and sciatica.

Physical examination revealed a mild fever (37.8°C) with epigastric and central abdominal tenderness; there was no evidence of rebound or guarding. Examination of the cardiovascular and respiratory systems was entirely normal. The patient was normotensive with no clinical evidence of shock. A subsequent electrocardiogram revealed anteroseptal ST segment elevation consistent with an acute myocardial infarction (fig 1). The patient was treated as for an acute myocardial infarction with aspirin and thrombolytic therapy. Initial routine blood tests were normal apart from a mildly increased white blood count of 14.4 and a C reactive protein of 152.

After admission the patient continued to complain of lower abdominal pain. Further examination at this stage revealed tenderness in the right lower quadrant. Over the course of the next 24 hours serial abdominal examinations did not reveal





**Figure 1** Electrocardiogram presentation.

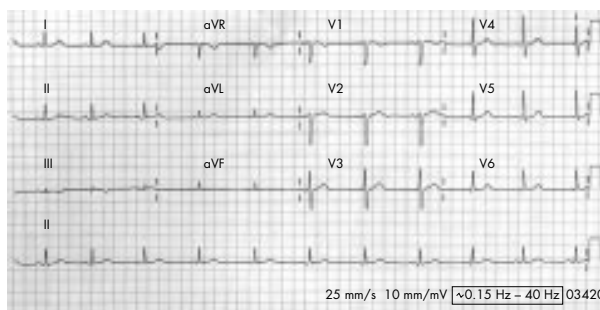
any evidence of rebound or guarding. Serial cardiac enzymes (creatine kinase) and two separate amylase results were normal.

In view of the persistent abdominal tenderness an appendectomy was performed, which revealed pus in the pelvis and a retrocaecal gangrenous appendix. The patient subsequently made an uneventful recovery and was discharged home nine days after initial admission. A total of four electrocardiograms were performed, three on the day of admission (including one after thrombolysis), all of which showed persistent ST segment elevation as shown in figure 1. The fourth electrocardiogram was performed before discharge, which showed the ST segment elevation to have resolved (fig 2).

## DISCUSSION

Electrocardiogram changes resembling acute myocardial infarction can rarely occur in association with an acute surgical abdomen. Pseudomyocardial infarction has been reported in association with acute pancreatitis,<sup>1,2</sup> perforated duodenal ulcer,<sup>3</sup> and acute abdominal conditions associated with shock and severe metabolic stress.<sup>4</sup> ST segment elevation has also been reported in an episode of variant angina induced by biliary colic.<sup>5</sup>

It has been postulated that the electrocardiogram changes that occur in acute abdominal conditions are related to episodes of electrical silence in the myocardium. Electrical silence is not synonymous with myocardial death; if the causative abnormality can be corrected the electrocardiogram changes will return to normal.<sup>6</sup> Several mechanisms have been postulated for this phenomenon including hypotension



**Figure 2** Electrocardiogram at discharge.

leading to decreased coronary perfusion, coronary artery spasm, systemic or local electrolyte disturbance, vagal stimulation, and circulating proteolytic enzymes. Electrolyte abnormalities such as hyponatraemia, hypokalaemia, and hypocalcaemia can modify the repolarisation phase on the electrocardiogram, but ST segment elevation in such cases is rarely seen. Profound hypotension may diminish coronary perfusion and cause ischaemia leading to electrocardiogram changes, especially in patients with coronary artery disease. Vagal reflexes can cause cardiac damage by acting directly on the myocardium, indirectly altering coronary blood flow or through increased secretion of pancreatic proteolytic enzymes. The membrane of the myocyte may be directly damaged by pancreatic proteolytic enzymes with subsequent changes of cell permeability and possible cellular necrosis, as well as secondary electrical disturbance.

Acute myocarditis has been associated with pseudomyocardial infarction electrocardiogram changes. This is typically related to viral myocarditis, however there is one reported case of pseudomyocardial infarction occurring in association with staphylococcal myocarditis.<sup>7</sup> It is of interest that in the previously documented case of pseudomyocardial infarction complicating a perforated duodenal ulcer, postmortem examination showed necrotic tissue in the lesser sac scattered focal changes of acute myocarditis. It is unlikely that the ST segment changes occurring in our case were related to bacterial myocarditis in view of the normal serial cardiac enzymes.

This particular case emphasises the rare but recognised association between ST segment changes that may mimic acute myocardial infarction and acute surgical pathology. Emergency physicians should be aware of this association and consider this possibility when a patient presents with atypical symptoms or signs.

## Contributors

C Dewar wrote the paper and acts as guarantor. A Siddiqi assisted with the literature search. J Kayani reviewed and edited the manuscript.

## Authors' affiliations

C Dewar, A Siddiqi, J Kayani, Sell Oak Hospital, Birmingham, UK

Correspondence to: Dr C Dewar, Accident and Emergency, New Cross Hospital, Wednesfield, Wolverhampton, West Midlands WV0 0QP, UK; suzanne@brannan43.fsnet.co.uk

Accepted for publication 21 January 2002

## REFERENCES

- 1 Mautner RK, Siegel LA, Giles TD, *et al.* Electrocardiographic changes in acute pancreatitis. *South Med J* 1982;**75**:317-20.
- 2 Hung SC, Chiang CE, Chen JD, *et al.* Images in cardiovascular medicine: pseudo-myocardial infarction. *Circulation* 2000;**101**:2989-90.
- 3 Thomas I, Mathew J, Kumar VP, *et al.* Electrocardiographic changes in catastrophic abdominal illness mimicking acute myocardial infarction. *Am J Cardiol* 1986;**59**:1224-5.
- 4 Shugoll GI. Transient QRS changes simulating myocardial infarction associated with shock and severe metabolic stress. *Am Heart J* 1967;**74**:402-9.
- 5 Antonelli D, Rosenfeld T. Variant angina induced by biliary colic. *Br Heart J* 1987;**58**:417-19.
- 6 De Pasquale NP, Burch GE, Phillips JH. Electrocardiographic alterations associated with electrically 'silent' areas of myocardium. *Am Heart J* 1964;**68**:697-709.
- 7 Raev D. Acute staphylococcal myocarditis masquerading as an acute myocardial infarction. *Int J Cardiol* 1997;**60**:95-8.

# Urinary schistosomiasis

J F Paul, S Verma, K Berry

Emerg Med J 2002;19:483-484

Schistosomiasis, although the commonest cause of haematuria worldwide, often remains undiagnosed and is yet easily treated. An 8 year old boy with macroscopic, end stream haematuria is presented in whom the diagnosis was made only after some delay.

An 8.5 year old boy presented to his general practitioner with a five week history of macroscopic, end stream haematuria preceded by a vague history of mild trauma to the penis. Subsequent renal ultrasound, full blood count, clotting, renal function tests were all within normal limits. He was then seen by a paediatric nephrologist two months later. At that time his mother reported that she had closely monitored the episodes and found that the haematuria was always at the end of micturition, associated with mild dysuria, and lasted for several weeks at a time, with her son remaining well in between episodes. The haematuria was always preceded by febrile episodes lasting for four to five days with temperatures occasionally exceeding 39°C.

Of note, the family had spent a three month period visiting Africa one year prior to presentation but had not resided there previously. During that visit, the patient was entirely asymptomatic and the family had adhered to the regimen for malaria prophylaxis. The only relevant family history of note was that mother had had a renal biopsy in the past, for investigation of proteinuria, which showed minor focal sclerotic glomerulonephritis.

Clinical examination was unremarkable apart from port wine stains, one visible on his left forearm and the other on the left anterior chest wall. A plan was made to dipstick the urine for a three month period and then review in clinic.

The patient then represented to the accident and emergency (A&E) department two months later with a recurrence of the haematuria. At this stage his mother was concerned the patient was no longer gaining weight with loss of appetite. There was dysuria but no associated abdominal or loin pain. His mother incidentally mentioned that another child who was on the same African holiday had recently been diagnosed with schistosomiasis and that all the children had played in a stream together.

Clinical examination in A&E was unremarkable and subsequent urine microscopy was positive for schistosomiasis. The patient was given praziquantel and was reviewed again in the outpatient department a month later and reported no further episodes of haematuria.

## DISCUSSION

Schistosomiasis is a chronic infection of the circulatory system caused by trematodes that inflame mainly the intestines, bladder, and liver. There are five types that affect humans.<sup>1</sup> *S haematobium*, which migrates to the perivesical and periureteral vessels, *S mansoni* to the inferior mesenteric, *S japonicum* to the superior mesenteric and the two others, *S intercalatum* and *S mekongi* to both mesenteric vessels. *S haematobium* is found mainly in Africa and the eastern Mediterranean region.

A person can become infected by prolonged contact (like bathing or swimming) with fresh water containing free swimming cercariae, the infective stage of the parasite that then enters the subcutaneous tissues, then the blood stream,

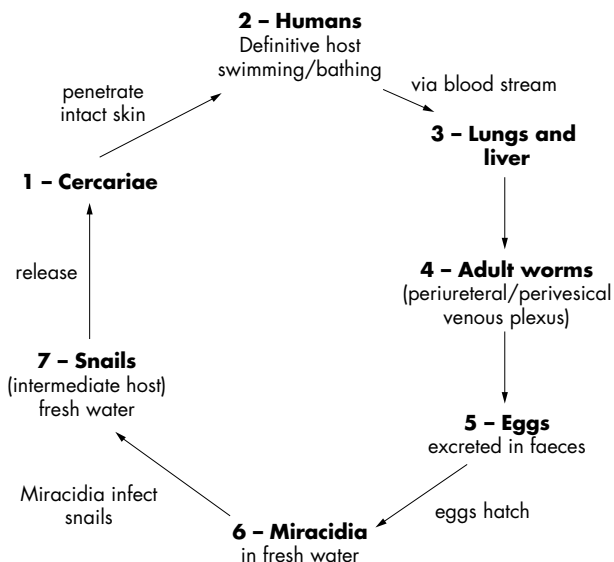


Figure 1 Life cycle of schistosomes.

migrates to the lungs, then to the liver, and finally to the mesenteric and perivesical venous plexuses. The parasite is excreted from the body via urine and faeces into fresh water and the miracidia eventually infects its intermediate hosts, the fresh water snails, where they develop into cercariae and the unfortunate cycle restarts again (fig 1).

The main effect of the parasite is chronic granulomatous injury in response to the eggs that are shed. The first sign of infection can be a reactive dermatitis syndrome with pruritis, inflammation, and the presence of a small erythematous macule, at the site of entry of the cercariae in the first few minutes after invasion, which may disappear within a few hours. Up to two weeks later there maybe a small papule at the same site, also associated with pruritis. Approximately two months after infection the person can present with katayama fever, lasting for up to two weeks or several months, with temperatures reaching as high as 40°C with rigors, diarrhoea, lethargy, myalgia, headache, nausea, and vomiting.

Urinary schistosomiasis is caused by *S haematobium* and deposition of eggs in the bladder and ureters. The subsequent granulomatous inflammation causes nodules, polypoid lesions, and ulcerations in the lumens of the ureter and bladder, which in turn causes urinary frequency, dysuria, and end stream haematuria. Chronic renal failure and carcinoma of the bladder occur with increased frequency in *S haematobium* infected patients. When schistosomiasis affects the intestines, the patient can present with colicky abdominal pain, bloody diarrhoea, and hepatosplenomegaly. In the lungs the effects can be pulmonary hypertension and cor pulmonale. In rare cases it can infect the brain causing seizures.

## DIAGNOSIS

The diagnosis strongly depends on the physician's awareness of this as a possible differential diagnosis, especially if there is a history of bathing in fresh water in endemic areas of Asia, South Africa, and Africa, a history of a pruritic reaction on an

exposed area of skin after bathing, or an unexplained febrile illness several weeks later. Urinary schistosomiasis is found mainly in patients between the ages of 10–30 years,<sup>2</sup> with children 11–13 years having the highest incidence.<sup>3</sup> The infection may recur in adults living in endemic areas as chronic reinfection produces incomplete immunity.

A definitive diagnosis can only be made with evidence of viable eggs in the urine, stool, or biopsy specimens. A urine sample best taken at midday after exercise, when most eggs are being shed, is ideal and microscopy often reveals eggs and parasites. In some cases a renal ultrasound, cystoscopy, and biopsy of the bladder mucosa is recommended if the urine microscopy is not conclusive or if the extent of infection and damage to the urinary tract needs further investigation. Identification of the schistosome eggs in stool with a thick smear method of Kato is very sensitive. Methods of immunoassay like ELISA and RIA are sensitive but not specific and can be considered in early schistosomiasis when there is a strong suspicion. In some cases the serological immunofluorescence antibody test for the presence of specific antibodies has been found to be a sensitive marker of acute and chronic infection.<sup>4</sup> Evaluation of the eosinophil cationic protein in urine has been used as a sensitive method for detecting early urinary tract pathology.<sup>5</sup> There has been some early work on the vaccine rSh28GST and results are encouraging.<sup>6</sup> The treatment of urinary schistosomiasis is praziquantel, given orally as a single or divided dose of 40–60 mg/kg. General efforts to control schistosomiasis are focused on interruption of the life cycle at snail-human and human-snail transmission.

## CONCLUSION

There is no doubt that if a high index of suspicion exists, early and prompt diagnosis and subsequent treatment is possible. A travel history is often beneficial in difficult diagnostic cases even when the presenting symptoms do not immediately suggest a tropical aetiology.

.....

### Authors' affiliations

**J F Paul, S Verma, K Berry**, Birmingham Children's Hospital, Birmingham, UK

Correspondence to: Dr S Verma, Birmingham Children's Hospital, Steelhouse Lane, Birmingham, B4 6NH, UK

Accepted for publication 26 November 2001

## REFERENCES

- 1 **Goldsmid J**, Kibel MA, Mills AE. *Forfar and Arneil's textbook of paediatrics*. 5th edn. Edinburgh: Churchill Livingstone, 1998:1507–11.
- 2 **Gabr NS**, Hammad TA, Obriby A, *et al*. The epidemiology of schistosomiasis in Egypt. *Am J Trop Med Hyg* 2000;**62**:65–72.
- 3 **Bello AB**, Edungbola LD. S. haematobium, a neglected common parasitic disease of childhood in Nigeria—study of incidence and intensity of infection; *Acta Paediatr* 1992;**81**:601–4.
- 4 **Tarp B**, Black FT, Peterson E. The immunofluorescence antibody test (IFAT) for the diagnosis of schistosomiasis used in a non-endemic area. *Trop Med Int Health* 2000;**5**:185–91.
- 5 **Leutscher PD**, Reimert CM, Vennervald BJ, *et al*. Morbidity assessment in urinary schistosomiasis infection through ultrasonography and measurement of eosinophil cationic protein (ECP) in urine. *Trop Med Int Health* 2000;**5**:88–93.
- 6 **Lane A**, Boulanger D, Riveau G, *et al*. Murine immune responses to schistosoma haematobium and the vaccine candidate rSh28GST. *Parasite Immunol* 1998;**20**:359–67.

# Torsade de pointes

P T Munro, C A Graham

*Emerg Med J* 2002;19:485-486

A case is described of torsade de pointes in a 41 year old woman with pre-existing QTc prolongation, potentially exacerbated by treatment with sotalol. Previous cardiac investigations had been normal and after a second episode of ventricular fibrillation the patient was referred for electrophysiological studies. The authors review the physiology, causes, and treatment of QTc prolongation and torsade de pointes.

A 41 year old woman was admitted to the accident and emergency (A&E) department with a short history of lethargy and malaise followed by a witnessed, generalised seizure. Two months previously she had been admitted with abdominal pain, vomiting, and a possible haematemesis. Shortly after admission on that occasion she sustained an unheralded ventricular fibrillation arrest, successfully treated with a single 200 J defibrillation. After arrest, her serum magnesium was 0.6 mmol/l (normal range 0.7 mmol/l to 1.0 mmol/l) and the QTc interval was 589 ms (upper limit of normal is 440 ms). There was no past or family history of cardiac disease and no admission of excess alcohol intake. Serum cardiac enzymes, echocardiography, exercise ECG, and coronary angiography were all found to be normal. She was discharged and prescribed sotalol for arrhythmia prophylaxis.

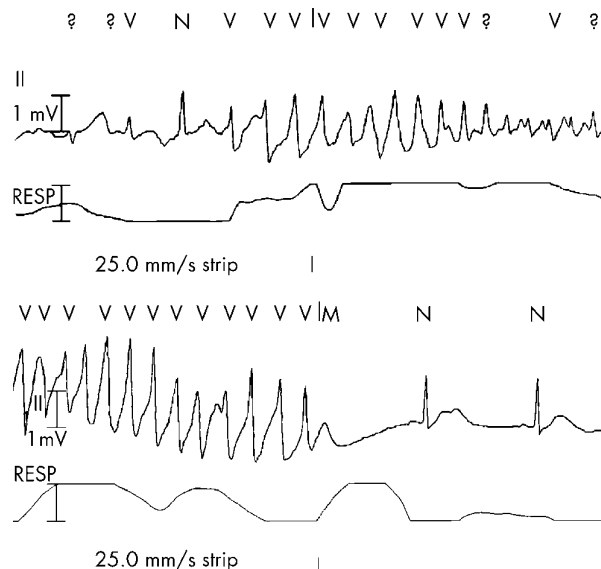
On this (second) admission she was alert and normotensive on arrival at A&E. She sustained a further generalised seizure during which ECG monitoring demonstrated self terminating bursts of torsade de pointes (fig 1). Each of these episodes was followed by rapid recovery until one episode degenerated into ventricular fibrillation requiring a single 200 J shock. Serum magnesium and potassium were found to be 0.59 mmol/l and 3.1 mmol/l respectively. A 12 lead ECG confirmed extreme QTc prolongation of 591 ms (fig 2), which rose to 676 ms the next day. She was treated with intravenous magnesium sulphate and potassium supplementation.

She had no further significant arrhythmias and was discharged two days later with atenolol substituted for sotalol and plans for subsequent electrophysiological studies.

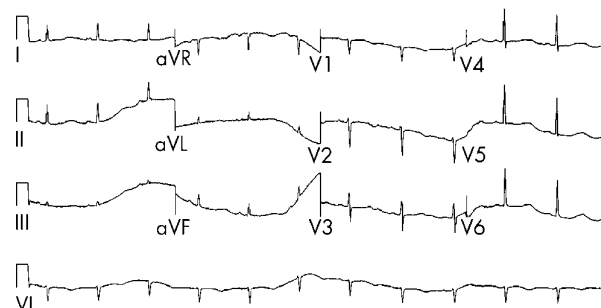
## DISCUSSION

Torsade de pointes is a form of polymorphic ventricular tachycardia in which the QRS complexes appear to twist around the isoelectric line. It is universally associated with congenital or acquired long QTc syndrome (LQTS).<sup>1</sup> Although it is often self limiting and associated with dizziness or syncope, ventricular tachycardia or ventricular fibrillation can occur resulting in sudden cardiac death. Congenital LQTS has been found to be associated with one of six identified mutations in genes coding for cardiac ion channels.<sup>1</sup> Patients with incomplete penetrance for these mutations may remain clinically silent for many years until exposed to drugs that further impair repolarisation.<sup>1</sup> Other known associations include female sex, recent heart rate slowing, pauses, extrasystoles, hypokalaemia, and hypomagnesaemia.<sup>1</sup>

Normal cardiac depolarisation results from the rapid inflow of sodium and calcium into cells and repolarisation results from the outflow of potassium from the cell exceeding the declining inflow of sodium and calcium. In LQTS an



**Figure 1** Rhythm strip showing initiation and spontaneous termination of torsade de pointes.



**Figure 2** ECG showing extreme QT prolongation.

intracellular excess of cations delays ventricular repolarisation; this prolongation of the QT interval results in early after depolarisations (EADs). This prolongation of repolarisation reduces the rate of inactivation of calcium channels, resulting in a late inflow of calcium, which increases the formation of EADs. These can be seen on the ECG as pathologically large U waves and can trigger ventricular arrhythmias.<sup>2</sup> The deep sub-endocardium is most prone to EADs and the differences in repolarisation throughout the myocardium can precipitate torsade de pointes.<sup>3</sup>

The QT interval varies with heart rate and so a corrected measure, the QTc interval, is usually used. QTc was calculated with Bazett's equation;  $QTc = QT \text{ interval (ms)} / \sqrt{60/\text{heart rate}}$ .<sup>4</sup> A QTc interval of greater than 500 ms is considered high risk for development of malignant arrhythmias. Many drugs are known to cause QTc prolongation including chlorpromazine, thioridazine, tricyclic antidepressants, macrolide antibiotics, lithium, and sotalol. Amiodarone is associated with QTc prolongation but for reasons that are poorly understood, it is rarely associated with significant arrhythmias.

Emergency treatment of torsade de pointes consists of removal of any torsadogenic stimulus and suppression of EADs, which may include acceleration of heart rate to reduce the QT interval. Magnesium sulphate suppresses torsade by decreasing the influx of calcium ions, which in turn results in decreased amplitude of EADs.<sup>5</sup> The initial dose is 2 g (20 ml of 10% solution), given intravenously over one to two minutes. This can be repeated up to a total of 6 g, with 5–15 minutes between doses; care should be taken to avoid magnesium toxicity.<sup>1</sup>

Initial treatment should also include the rapid correction of serum potassium concentrations, aiming for a target serum concentration of 4.5 mmol/l.<sup>6</sup> In some circumstances urgent transvenous pacing may be necessary to suppress arrhythmias by increasing the baseline heart rate to 100 to 150 beats per minute.<sup>1</sup> Temporary transcutaneous pacing has also been successfully used to treat torsade de pointes.<sup>7</sup> As in this case, degeneration to ventricular fibrillation or pulseless ventricular tachycardia can occur, which should be treated along conventional lines along with simultaneous administration of intravenous magnesium sulphate. ECG monitoring is required for patients presenting with seizures. We would also suggest that a 12 lead ECG is mandatory where seizures are of new onset or are associated with any atypical features.

#### Contributors

P Munro and C Graham jointly conceived and wrote the paper and both contributed to the literature review. P Munro revised the manuscript and will act as guarantor.

.....

#### Authors' affiliations

**P T Munro, C A Graham**, Department of Accident and Emergency Medicine, Southern General Hospital, 1345 Govan Road, Glasgow G51 4TF, UK

Correspondence to: Dr P T Munro; PHIL.MUNRO@sgh.scot.nhs.uk

Accepted for publication 6 November 2001

#### REFERENCES

- 1 **Viskin S**. Long QT syndromes and Torsade de Pointes. *Lancet* 1999;**354**:1625–33.
- 2 **Tan HL**, Hou CJ, Lauer MR, *et al*. Electrophysiologic mechanisms of the long QT interval syndromes and Torsade de pointes. *Ann Intern Med* 1995;**122**:701–14.
- 3 **Antzelevitch C**, Sicouri S. Clinical relevance of cardiac arrhythmias generated by afterdepolarisations: role of M cells in the generation of U waves, triggered activity and Torsade de pointes. *J Am Coll Cardiol* 1994;**23**:259–77.
- 4 **Bazett HC**. An analysis of time-relations of electrocardiograms. *Heart* 1920;**7**:353–70.
- 5 **Tzivoni D**, Banai S, Schuger C, *et al*. Treatment of Torsade de pointes with magnesium sulfate. *Circulation* 1988;**77**:392–7.
- 6 **Choy A**, Lang C, Chomsky D, *et al*. Normalization of acquired QT prolongation in humans by intravenous potassium. *Circulation* 1997;**97**:2149–54.
- 7 **Monraba R**, Sala C, Cortes E, *et al*. Percutaneous overdrive pacing in the out-of-hospital treatment of Torsade de Pointes. *Ann Emerg Med* 1999;**33**:356–7.