

CASE REPORTS

Cardiac tamponade: a case of kitchen floor thoracotomy

K D Wright, K Murphy

Emerg Med J 2002;**19**:587–588

Successful thoracotomy in the prehospital environment is becoming more widely accepted.^{1,2} Here we present the case of cardiac arrest secondary to penetrating chest injury and the successful prehospital thoracotomy that followed. The resuscitation was associated with the spontaneous return of motor activity and later, hospital discharge. The implication for the immediate need for anaesthesia and paralysis is discussed together with a description of the surgical technique.

CASE REPORT

A teenage male youth sustained a stab wound to the left chest, in the third intercostal space at the junction of the medial and middle thirds of the clavicle. This wound was part of a deliberate self harm attempt. On arrival of the medical team—15 minutes from 999 call—he was thrashing and taking a few agonal breaths, this rapidly deteriorated to cardiac arrest within the first few seconds of assessment.

The patient was placed on the floor of his first floor flat and endotracheal intubation was undertaken by the medical team paramedic; cannulation was achieved by a first responder paramedic and the medical team doctor undertook bilateral thoracostomies in the right and left 4th intercostal space, midaxillary line. This revealed a small haemothorax on the left side. The thoracostomies were joined by a skin incision using a 22 blade scalpel through skin and subcutaneous fat. Heavy duty shears were placed through the thoracotomy and used to cut through muscle and sternum thus making a large clamshell thoracotomy.

With the chest open the pericardium was visualised as a blue, tense sac. Mosquito forceps were used to tent the pericardium and it was incised with scissors and widely opened. A large clot was removed and the operator's right index finger used to occlude a hole in the posterior aspect of the left upper heart. As the hole was occluded the heart began to fill and beat, restoring a carotid pulse. There was no anterior wound.

The patient attempted to breathe and then localised both upper limbs towards the chest incision. He was rapidly sedated and paralysed with midazolam 10 mg and pancuronium 8 mg. The patient was then lifted down two flights of stairs and taken to the nearest accident and emergency/cardiothoracic centre still with digital occlusion of the hole. Treatment at scene lasted 18 minutes. Bleeding from the internal mammary vessels was controlled with mosquito forceps.

On arrival, (journey time four minutes) he was maintaining a heart rate of 100 beats per minute and a systolic blood pressure of between 60 and 90 mm Hg. A cardiothoracic response enabled haemostatic sutures to be placed while in the resuscitation room before transfer to theatre for definitive closure. He was then transferred to the intensive care unit.

The postoperative course was initially difficult requiring a second thoracotomy for intrathoracic bleeding. Sepsis caused a syndrome of renal failure requiring haemofiltration. However by day eight he was alert and appropriate neurologically, requiring no cardiovascular support and doing well. Subsequently he made a full recovery and was discharged from hospital with no neurological deficit.

DISCUSSION

Prehospital thoracotomy aims to treat one specific group of patients—those with penetrating chest injury leading to cardiac tamponade. The procedure aims to release that tamponade and restore cardiac output permitting the patient to be evacuated to hospital. It is extremely unlikely that prehospital thoracotomy would be undertaken by a cardiothoracic surgeon and most accident and emergency departments would be hard pressed to mount a cardiothoracic response as part of their trauma team. The technique therefore needs to be simple and easily learned, with the limited aims of release of tamponade, haemostasis from cardiac wounds, and perhaps aortic occlusion.

Advanced medical care at the scene is becoming increasingly available. The advent in the United Kingdom of physicians working in conjunction with the ambulance service as prehospital care providers and with medical/trauma systems such as the London Helicopter Emergency Medical Service and physician ride-alongs in the United States mean that there has been some experience with prehospital thoracotomy.

Battistella *et al*³ conducted a retrospective analysis of trauma patients who were pulseless at scene. Altogether 604 patients with traumatic cardiac arrest were studied, (304 from blunt injury and 300 from penetrating injury). Some 304 of the patients underwent EDT, 160 went to the operating room. Only 16 patients left hospital—seven with severe neurological impairment. There were no survivors among those whose initial rhythm was asystole. No patient survived to leave hospital if their initial cardiac electrical rate was less than 40 beats per minute. The study concluded those pulseless trauma patients in asystole or with an electrical activity rate of less than 40 beats per minute should be pronounced dead at the scene.

In the face of such adverse statistics it becomes important to justify undertaking such a procedure. In the past 10 years the author is aware of six successful on scene thoracotomies. In all cases the patient left hospital neurologically intact. Only endotracheal intubation has been validated to improve outcome in patients in extremis, if transport time is to be delayed then advanced surgical care at the scene can restore cardiac activity. This is supported by Freezza and Mezghebe⁴ who determined that 30 minutes is the optimum period from injury to EDT. Thus if transport is delayed then onscene thoracotomy is both reasonable and perhaps a standard of care when applied to a set patient condition. This is penetrating chest injury associated with cardiac arrest. Penetrating injury can be thought of as high, medium, or low energy transfer—rifles, handguns, and knives respectively. High and medium energy transfer injuries are associated with the phenomenon of temporary and permanent cavitation thus the damage pattern may be much more severe than outward signs suggest. This means that the limited range of surgical options available in the field could be insufficient to cope with the injuries found and rapid transfer to the emergency department may be more appropriate.

Ivatury⁵ and his colleagues studied a series of 100 patients in extremis and requiring EDT. Patients were in two groups. Group I received stabilisation and group II underwent rapid

transfer to the emergency department. A higher proportion of group II patients reached the emergency room with signs of life than group I and overall survival was higher in the rapid transfer group. The anatomical injury severity and mode of injury was similar in the two groups. Prehospital thoracotomy was not available to these groups as a prehospital stabilisation method. Thus in a non-surgical option setting rapid transfer seems to confer a better outcome. This message was echoed by Honigan and colleagues.⁶ Seventy consecutive patients with cardiac injury were studied. On scene time by paramedics averaged 10.7 minutes and these patients were intubated and cannulated. It was concluded that paramedics can perform these interventions without prolonging the time spent in the prehospital phase thus delivering them to hospital for advanced surgical care. Early thoracotomy seems to be fundamental to the survival of these patients. Delayed thoracotomy significantly raised the mortality from injury in 228 patients studied.⁷ Thoracotomy on scene must therefore be the standard of care that is applicable to these patients.

The restoration of a circulation may well lead to an improvement in the patients conscious level with dramatic effect. As the arrested patient will have been intubated without anaesthesia then rapid paralysis and sedation must be available. Previous reported cases have improved neurologically at hospital but not in the immediate resuscitative phase. The choice of sedating agents and the use of paralyzing drugs will depend on the operator's own experience. Many physicians will be familiar with agents such as the benzodiazepines and opioids for sedation. Most sedating drugs will tend to lower blood pressure. It would be prudent for the physician to use the lowest dose that achieves clinical effect. The danger for the non-anaesthetist using paralyzing drugs normally lies in the failed intubation scenario. Under the circumstances described advanced airway management should be undertaken before thoracotomy. Failure to intubate may represent an indication for immediate transfer to hospital rather than undertake thoracotomy. The implication is that use of these drugs facilitates the transfer of the resuscitated patient. Those who envisage using this procedure should familiarise themselves with the available agents.

The technique chosen for the thoracotomy is simple and uses only instruments that are familiar to all emergency physicians. No specific cardiothoracic instruments are used. If the operator is familiar with the technique of chest drain insertion and thoracotomy then they will be able to extend this to perform a "clamshell thoracotomy". As the procedure is being undertaken in far from ideal circumstances, this familiarity will boost confidence in the operator. Complex cardiothoracic repair should not be attempted. Haemostasis either by digital occlusion or suture is all that is required. Digital occlusion should be placed over but not in cardiac wounds to avoid enlarging the defect. The "clamshell" technique permits good visualisation of structures and allows for aortic occlusion is required. This technique has been shown to be effective when used by anaesthetists and emergency physicians in a recent

series.⁸ If the operator is not able to carry out thoracotomy then needle pericardiocentesis may be life saving. However, traumatic tamponade is often clotted and pericardiocentesis fails yet thoracotomy allows for clot removal. If the skills are available then thoracotomy should be used as this is the definitive end point and avoids using precious time in a procedure likely to fail.

CONCLUSIONS

Prehospital thoracotomy is an aggressive treatment that should be reserved for those patients likely to have cardiac tamponade. If applied promptly and judiciously it can be successful and lead to a neurologically intact survivor. If a prehospital provider is not familiar with the technique then rapid transfer to the nearest institution capable of providing resuscitative thoracotomy should be undertaken. Practitioners should become familiar with sedative and paralyzing agents for use in the event of a recovery of spontaneous circulation and awareness. Patients in asystole or with a downtime of greater than 30 minutes should not undergo thoracotomy.

Contributors

Both Kelvin Wright and Ken Murphy attended the patient. Kelvin Wright performed the surgical procedure while Ken Murphy undertook airway management. The paper was written by Kelvin Wright who also acts as guarantor for the content.

Authors' affiliations

K D Wright, London Helicopter Emergency Medical Service, Helicopter Emergency Medical Service (HEMS) London, Royal London Hospital, London, UK

K Murphy, London Ambulance Service, Helicopter Emergency Medical Service (HEMS) London

Correspondence to: Mr K D Wright, Emergency Department, John Radcliffe Hospital, Headley Way, Oxford, UK; kwright@doctors.org.uk

Accepted for publication 6 November 2001

REFERENCES

- 1 **Craig R**, Clarke K, Coats TJ. On scene thoracotomy: a case report. *Resuscitation* 1999;**40**:45–7.
- 2 **Wall MJ**, Pepe PE, Mattox KL. Successful roadside resuscitative thoracotomy: a case report and literature review. *J Trauma* 1994;**36**:131–4.
- 3 **Battistella FD**, Nugent W, Owings JT, *et al*. Field triage of the pulseless trauma patient. *Arch Surg* 1999;**134**:742–5.
- 4 **Freezza EE**, Mezgebe H. Is 30 minutes the golden period to perform emergency room thoracotomy in penetrating chest injuries? *J Cardiovasc Surg* 1999;**40**:147–51.
- 5 **Ivatury RR**, Nallathambi M, Roberge RJ, *et al*. Penetrating thoracic injuries: in-field stabilisation vs. prompt transport. *J Trauma* 1987;**27**:1066–73.
- 6 **Honigan B**, Rohweder K, Moore EE, *et al*. Prehospital advanced trauma life support for penetrating cardiac wounds. *Ann. Emerg Med* 1990;**19**:145–50.
- 7 **Ivatury RR**, Rohman M, Steichen FM, *et al*. Penetrating cardiac injuries: twenty year experience. *Am Surg* 1987;**53**:310–17.
- 8 **Coats TJ**, Keogh S, Clark H, *et al*. Prehospital resuscitative thoracotomy for cardiac arrest after penetrating trauma: rationale and case series. *J Trauma* 2001;**50**:670–3.

Disruption of the iliocolic artery after blunt trauma

C Dewar, D F Gorman

Emerg Med J 2002;19:589–590

Injury to the superior mesenteric artery and branches is an uncommon event, which is typically associated with penetrating injury and high mortality. A case is presented of rupture of a branch of the superior mesenteric artery (iliocolic artery) after blunt trauma. The case illustrates the more occult presentation and better overall prognosis associated with this type of injury as compared with injury to the proximal superior mesenteric artery. In addition this case highlights the importance of vigilance in patients who deteriorate after initial resuscitation.

Abdominal vascular injury and specifically injury to the visceral arteries occurs uncommonly after blunt trauma.¹ Injury to the superior mesenteric artery and resultant haemorrhage is associated with high mortality rates.^{2,3} This is a report of disruption to the iliocolic artery, a branch of the superior mesenteric artery, after blunt trauma.

CASE REPORT

A 29 year old man was the restrained driver of a car, which collided at approximately 60 mph with a stationary car. He was trapped in the car for one hour. The patient was alert and orientated; he had not exhibited any signs or symptoms consistent with concussion. He was transported from the accident scene by helicopter. On arrival his blood pressure was 100/70 mm Hg with a pulse of 110, within 20 minutes the systolic blood pressure had decreased to 70 mm Hg. He initially complained of right sided abdominal and leg pain. Examination revealed right sided abdominal tenderness that was maximal in the right iliac fossa with associated guarding and rebound.

He was subsequently resuscitated over the following two hours with three units of O negative blood and three litres of crystalloid solution. A standard trauma series of radiographs revealed a fracture of the right hemi-pelvis, through the iliac wing and down towards the sciatic notch, together with fractures of all four pubic rami. In addition radiographs of the right femur showed an intertrochanteric and subtrochanteric fracture.

After initial resuscitation the patient's blood pressure stabilised at between 110 mm Hg and 120 mm Hg systolic with a pulse of between 80 and 100. Abdominal ultrasound showed a small amount of free fluid around the liver but no definite liver laceration. At this stage the patient was diagnosed as having had a retroperitoneal bleed secondary to the above mentioned pelvic fractures.

After two hours, in which the patient remained stable, his blood pressure decreased 80/60 mm Hg. In view of this a laparotomy was performed, a ruptured iliocolic artery and associated tears to the mesentery of the terminal ileum were found. There was an estimated three litres of intraperitoneal blood. The injured artery was resected and repaired with an end to end anastomosis using interrupted sutures.

The patient's postoperative course was unremarkable and the patient was discharged 24 days after injury.

DISCUSSION

Blunt abdominal trauma rarely causes isolated vascular injuries. It is estimated that the superior mesenteric artery branch is affected in 9% of cases of abdominal vascular trauma.¹

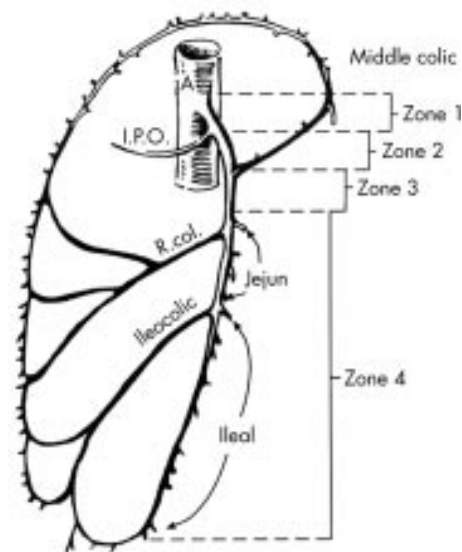


Figure 1 Subdivision of superior mesenteric artery into Fullen's zones.

The small studies available indicate that the mortality rate for injury to the superior mesenteric artery is between 33% and 68%.^{2,3} Blunt trauma is the mechanism of injury in 23% of cases.⁴ With blunt trauma, the abdominal viscera are forced into the pelvis and subsequently pull on their vascular attachment. This combined with unequal deceleration can result in rupture of the mesenteric vessels.⁵ The injury observed in this patient was probably attributable to the abrupt deceleration resulting from impact with a stationary vehicle at 60 mph and the restraining action of the seat belt.

In 1972 Fullen *et al.*⁶ subdivided the superior mesenteric artery circulation into four zones (fig 1).

Mortality rates vary from 100% in zone 1 to 25% in zone 3 and 4, however there were no isolated cases of zone 4 trauma.⁴ Patients sustaining proximal superior mesenteric artery injuries usually present with a systolic blood pressure of less than 90 mm Hg (68%–93%).^{2,3}

This case is consistent with the assumption that zone 4 injuries may have a more occult presentation and carry a better overall prognosis. The occult presentation illustrates the difficulties inherent in making an accurate clinical diagnosis when haemorrhage is from a small intra-abdominal artery. This was further compounded by the erroneous assumption that the cause of the patient's initial hypotension was a retroperitoneal bleed secondary to pelvic fractures. It is possible that further investigation when the patient was haemodynamically stable might have resulted in earlier diagnosis of the underlying problem. Computed tomography has been shown to be both sensitive and specific in the diagnosis of intra-abdominal injury in the blunt trauma patient.⁷ Successful treatment of patients with injury to the visceral arteries continues to include volume replacement and rapid exposure of injuries.

Contributors

C Dewar searched the literature and wrote the paper. C.Dewar is the guarantor for the paper. D Gorman reviewed and advised on the paper.

.....
Authors' affiliations

C Dewar, DF Gorman, Selly Oak Hospital, Birmingham, UK

Correspondence to: Dr C Dewar, Fife Acute Hospitals Trust, Queen Margaret Hospital, Whitefield Road, Dumfermline, Fife KY12 0SU, UK; suzanne@brannan43.fsnet.co.uk

Accepted for publication 29 October 2001

REFERENCES

1 **Jackson MR**, Olson DW, Beckett WC, *et al.* Abdominal vascular trauma: a review of 106 injuries. *Am Surg* 1992;**58**:622-6.

- 2 **Lucas AE**, Richardson JD, Flint LM, *et al.* Traumatic injury of the proximal superior mesenteric artery. *Ann Surg* 1981;**193**:30-4.
 3 **Accola KD**, Feliciano DV, Mattox KL, *et al.* Management of injuries to the superior mesenteric artery. *J Trauma* 1986;**26**:313-19.
 4 **Asensio JA**, Berne JD, Chahwan S, *et al.* Traumatic injury to the superior mesenteric artery. *Am J Surg* 1999;**178**:235-9.
 5 **Lassonde J**, Laurendeau F. Blunt injury of the abdominal aorta. *Ann Surg* 1981;**194**:745-8.
 6 **Fullen WD**, Hunt J, Altenmeier WA, *et al.* The clinical spectrum of penetrating injury to the superior mesenteric arterial circulation. *J Trauma* 1972;**12**:656-64.
 7 **Richards JR**, Derlet RW. Computed tomography for blunt abdominal trauma in the ED: a prospective study. *Am J Emerg Med* 1998;**16**:338-42.

Use of the Asherman chest seal as a stabilisation device for needle thoracostomy

K Allison, K M Porter, A M Mason

Emerg Med J 2002;**19**:590-591

We report the use of the Asherman chest seal as a stabilisation device for needle thoracostomy in the prehospital environment. Although this piece of equipment has been available for five years, primarily for the prehospital treatment of chest wounds,¹ this novel modification of its purpose increases its application to prehospital care. This work was prepared on behalf of the research and developments committee of the Faculty of Pre-hospital Care, Royal College of Surgeons of Edinburgh.

CASE 1

The driver of an articulated lorry was heavily trapped in wreckage after his vehicle was involved in a collision with the rear end of a lorry laying out cones. Examination at scene revealed a left sided chest injury, possible intra-abdominal injury, and probable fractured pelvis. After extrication, the patient's condition suddenly deteriorated and his level of consciousness decreased (Glasgow Coma Score (GCS) 14 to 3). He was found to have paradoxical movements of his chest, absent radial pulse, no pulse oximetry reading, and the ECG tracing showed a sinus tachycardia of 124 beats per minute. Diagnoses of tension pneumothorax or cardiac tamponade leading to the pulseless electrical activity (PEA) were suspected and a Cook emergency pneumothorax drain was inserted with the release of air and dramatic improvement in the patient's condition. The immediate care doctor placed an Asherman seal onto the chest wall with the body of the plastic cannula stabilised within the flutter valve mechanism of

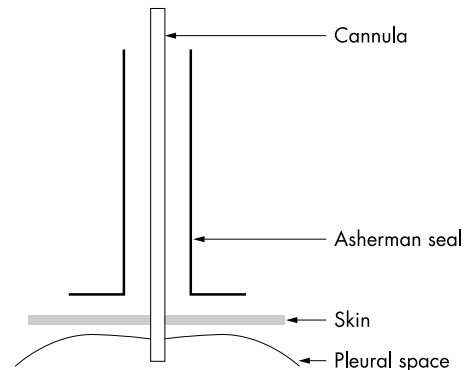


Figure 2 Schematic of needle thoracostomy cannula secured by placement within an Asherman chest seal.

the seal. The patient was transferred to hospital with a GCS of 14, radial pulse 120 beats per minute, blood pressure 110/70 mm Hg, and pulse oximetry 95%.

The patient subsequently had a chest drain in the accident and emergency (A&E) department, before computed tomography and laparotomy for a hepatic injury. The Cook drain and Asherman seal were kept in place throughout these procedures and transfer to intensive care.

CASE 2

A 17 year old man was a non-restrained front seat passenger, trapped in a car after a collision with another vehicle. His airway was clear. He appeared to have decreased breath sounds and an increased percussion note on one side of his chest although this assessment was difficult in a noisy environment. He had a GCS of 12 at scene. During extrication he deteriorated and required bag-valve-mask assisted ventilation. He developed increasing respiratory distress and he had clear signs of a left sided tension pneumothorax. A needle thoracostomy was performed but was subsequently dislodged and needed replacing during the extrication. After this the venflon was stabilised in position using an Asherman chest seal, which then maintained the position until the completion of extrication and during the 10 minute transfer to hospital. In the A&E department a chest drain was performed and the patient subsequently made a full recovery.

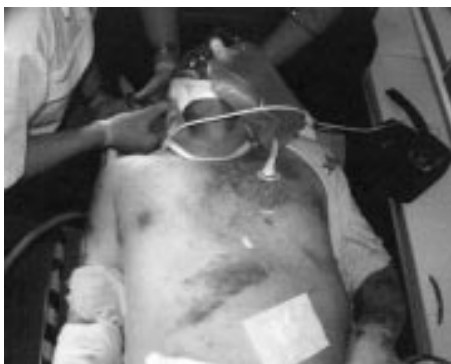

Figure 1 Asherman chest seal in place on patient's left chest wall.

DISCUSSION

Chest trauma is one of the leading causes of trauma deaths²⁻⁵ and tension pneumothorax is one of the immediately life threatening conditions amenable to prehospital treatment.⁶ Needle thoracocentesis, entailing the insertion of a large bore cannula into the second intercostals space in the mid-clavicular line, is an established treatment for this condition and buys time before definitive chest drain insertion in hospital.⁷ It is recognised that cannula length can be a problem in the thoracocentesis technique.^{8,9} Chest drain insertion outside of hospital can prolong scene time and is rarely immediately necessary in most trauma scenarios.

During extrication, patient packaging, and transfer, the needle thoracocentesis can easily be dislodged as the second case identifies. The Asherman chest seal can easily be placed over the barrel of the thoracocentesis cannula and permits a more robust, easy, and readily available stabilisation device for the thoracocentesis cannula than tapes, gallipots, and syringe barrels, which are currently suggested (fig 1 and 2).

Authors' affiliations

K Allison, George Eliot Hospital, Nuneaton, UK
K M Porter, University Hospital Birmingham NHS Trust-SellyOak, Birmingham, UK

A M Mason, Suffolk Accident Rescue Service (SARS), Bury St Edmunds, Suffolk, UK

Correspondence to: Mr K P Allison, 271 Blossomfield Road, Solihull, West Midlands B91 1TA, UK; kallison@ukonline.co.uk

Accepted for publication 1 May 2002

REFERENCES

- Hodgetts TJ**, Hanlan CG, Newey CG. Battlefield first aid: a simple, systematic approach for every soldier. *J R Army Med Corps* 1999;**145**:55-9.
- Bielecki K**. Trauma care for the year 2000. *Przegl Lek* 2000;**57** (suppl 5):127-8.
- Golden PA**. Thoracic trauma. *Orthopaedic Nursing* 2000;**19**:37-45.
- American College of Surgeons**. Thoracic Trauma. In: ACS committee on trauma, ed. *Advanced Trauma Life Support for Doctors (ATLS)*. Chicago: ACS, 1997:125-56.
- National Association of Emergency Medical Technicians**. Thoracic trauma. In: NAEMT, ed. *Pre-hospital trauma life support*. Akron, OH: NAEMT, 1990:124-46.
- Sanson G**, Di Bartolomeo S, Nardi G, et al. Road traffic accidents with vehicular entrapment: incidence of major injuries and need for advanced life support. *Eur J Emerg Med* 1999;**6**:285-91.
- Trauma Care**. Thoracic trauma. In: Greaves I, Porter K, Ryan J, eds. *Trauma Care Manual*. London: Arnold, 2001:54-70.
- Patison GT**. Needle thoracocentesis in tension pneumothorax: insufficient cannula length and potential failure. *Injury* 1996;**27**:758.
- Britten S**, Palmer SH, Snow TM. Needle thoracocentesis in tension pneumothorax: insufficient cannula length and potential failure. *Injury* 1996;**27**:321-2.

Cervical spine control; bending the rules

N S S Maskery, N Burrows

Emerg Med J 2002;19:592–593

Cervical spine fractures associated with diffuse idiopathic hyperostosis (DISH) are less common than those associated with ankylosing spondylitis and can occur after minor trauma in patients asymptomatic of the disease process. This case report describes a hyperextension injury of the neck in a patient unknown to have DISH, which resulted in an angulated C3/C4 fracture. The position of the fracture was improved by placing the neck in flexion with immediate improvement in the patient's neurological deficit.

ATLS guidelines¹ for the management of a suspected cervical spine injury state that the neck should be immobilised at all times until a fracture or spinal cord injury has been excluded. Usually this entails immobilisation with a hard cervical collar, sand bags or bolsters, and tapes. Here we describe a situation where an exception was made for unusual reasons.

CASE REPORT

A 77 year old man was transferred to the emergency department (ED) after a fall on a dry ski slope. He was complaining of neck pain and an inability to feel or move his arms and legs from the time of the fall. He was transferred immobilised in a hard cervical collar on a spinal board. The board was removed on arrival in the ED, cervical spine control being maintained with triple immobilisation as per ATLS guidelines. On assessment he was found to have left sided facial abrasions with no evidence of significant head injury. Peripherally neurological examination revealed a sensory level at C5 and slight movement in the left arm only grade 1–2 power, as well as diaphragmatic breathing and some anal tone. A trauma series of radiographs were performed that showed an angulated fracture at C3/C4 (see fig 1) with bony bridging of the cervical vertebra anteriorly suggestive of diffuse idiopathic skeletal hyperostosis (DISH). After review of the radiograph the hard cervical collar was immediately removed and the head placed on a pillow to flex the neck. Further radiographs showed reduction of the fracture (see fig 2). Subjectively an immediate improvement in his neurology was noted and on further assessment he was found to have regained bilateral

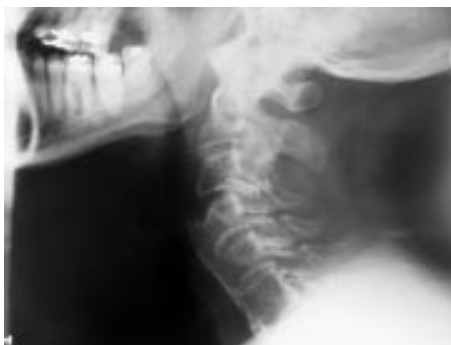

Figure 1 Lateral C spine radiograph showing an angulated fracture at C3/C4 with bony bridging anterior to C4–C6.

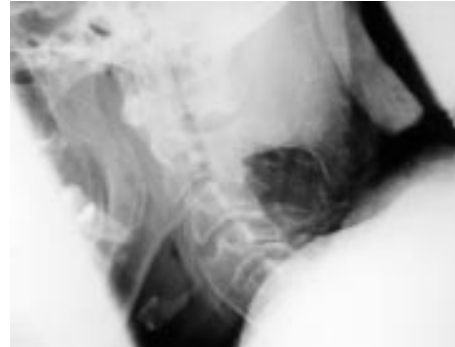

Figure 2 Lateral C spine radiograph showing reduction of C3/C4 fracture.

hip flexion grade 4 and some knee flexion and ankle plantar and dorsiflexion. His sensory level was unchanged. His neck was maintained in flexion and he was transferred to the spinal treatment centre where two days later he was noted to have almost normal power in his right lower leg, grade 2–4 in the left leg, grade 1–3 in his left arm, but grade 0 in his right arm. A diagnosis of an incomplete spinal cord injury was made with features of a central and posterior cord syndrome as well as a Brown-Sequard syndrome.

DISCUSSION

DISH is a common condition affecting between 2.5% to 10% of people over the age of 70 years and is more common in men than women.² It is a non-inflammatory condition with flowing calcification and ossification along the anterolateral borders of varying numbers of contiguous vertebral bodies with preservation of the disc spaces. It is similar but not identical in pathology to the disease processes ankylosing spondylitis (AS) and ossification of the posterior longitudinal ligament, and all three can lead to unexpected and grossly unstable fractures of the spine with similar management problems.^{3,4}

Quite often DISH is asymptomatic but may cause stiffness and loss of motion of the spine that is usually mild to moderate. Whereas in AS loss of movement and kyphosis of the cervical spine can be pronounced it is generally less of a feature in DISH, and indeed in this patient there was no history of such a problem. A degree of spinal osteopenia is also associated with DISH though to a lesser extent than with AS.

In all three processes the combination of osteopenia, loss of elasticity, and ossified ligaments produces a rigid brittle structure, which is prone to fracture, and which is recognised to act more like a long bone in fracture with the fulcrum of movement centred around the fracture site.⁵ This rod-like nature also tends to produce transverse fractures that pass all the way across the vertebral level, as compared with the compressive fractures normally seen in flexible spines.⁶ These features generally make the fractures markedly unstable.

Abbreviations: DISH, diffuse idiopathic skeletal hyperostosis; AS, ankylosing spondylitis; ED, emergency department

While fractures of the cervical spine associated with DISH have been described in the past, this is the first report in which the neurological injury associated with the fracture has been shown to improve by immobilising the neck in the line of the kyphosis. There have been reports of neurological deterioration after placement in a cervical collar in patients with a combination of cervical spine fracture and AS,^{7,8} but in both these cases the patients complained of increasing pain and neurological dysfunction as the collar was applied and there was little improvement on subsequent removal of the hard collar. There was no such history in this case and this could be because the degree of kyphotic deformity and spinal rigidity tends to be not so marked in DISH patients. A learning point to be gained from this case is that in some exceptional circumstances one must not be afraid to remove all conventional cervical spine protection and immobilise the neck in the line of the pre-existing kyphosis. Normally triple immobilisation of the neck places the cervical spine in a neutral position—that is, in neither flexion nor extension. In this patient's case neutrality could only be achieved by flexing the neck to bring the upper cervical vertebra in alignment with the rigid fused lower vertebra. Also in all these disease processes significant fractures and spinal cord injuries can occur after minor trauma and a common cause of secondary neurological deterioration is delayed diagnosis.^{5,9} As symptoms associated with DISH may well be at most minor and overlooked by the patient, ED physicians must have a strong index of suspicion in elderly patients presenting with neck pain even if the degree of trauma appears to be insignificant.

Contributors

NM performed the literature search, reviewed the articles, and wrote the case report. NB initiated the study idea and reviewed the final report. Nick Maskery is guarantor for the paper,

Authors' affiliations

N S S Maskery, N Burrows, Emergency Department, Salisbury District Hospital, UK

Correspondence to: Dr N Maskery, Emergency Department, Salisbury District Hospital, Odstock Road, Salisbury SP2 8BJ, UK; nickmaskery@aol.com

Accepted for publication 1 May 2002

REFERENCES

- 1 **American College of Surgeons**. *Advanced trauma life support manual*. 6th edn. Chicago: American College of Surgeons, 1997.
- 2 **Mata S**, Fortin PR, Fitzcharles MA, *et al*. A controlled study of diffuse idiopathic skeletal hyperostosis: clinical features and functional status. *Medicine* 1997;**76**:104–17.
- 3 **Meyer PR**. Diffuse idiopathic skeletal hyperostosis in the cervical spine. *Clin Orthop Rel Res* 1999;**359**:49–57.
- 4 **Taggard DA**, Traynelis VC. Management of cervical spinal fractures in ankylosing spondylitis with posterior fixation (point of view). *Spine* 2000;**25**:2035–9.
- 5 **Broom MJ**, Raycroft JF. Complications of fractures of the cervical spine in ankylosing spondylitis. *Spine* 1988;**13**:763–6.
- 6 **Houk RW**, Hendrix RW, Lee C, *et al*. Cervical fracture and paraplegia complicating diffuse idiopathic skeletal hyperostosis. *Arthritis Rheum* 1984;**27**:472–5.
- 7 **Papadopoulos MC**, Chakraborty A, Waldron G, *et al*. Exacerbating cervical spine injury by applying a hard collar. *BMJ* 1999;**319**:171–2.
- 8 **Podolsky SM**, Hoffman JR, Pietrafesa CA. Neurologic complications following immobilization of cervical spine fracture in a patient with ankylosing spondylitis. *Ann Emerg Med* 1983;**12**:578–80.
- 9 **Colterjohn NR**, Bednar DA. Identifiable risk factors for secondary neurologic deterioration in the cervical spine-injured patient. *Spine* 1995;**20**:2293–7.

Fatal anaphylactoid reaction to N-acetylcysteine: caution in patients with asthma

A V Appelboam, P I Dargan, J Knighton

Emerg Med J 2002;19:594–595

Paracetamol overdose is a common reason for presentation to the emergency department and N-acetylcysteine is frequently used in the treatment of toxic paracetamol ingestions. Adverse reactions to N-acetylcysteine are common though usually mild and easily treated. Serious reactions to N-acetylcysteine however, are rare and there have been no previous reported fatalities with its therapeutic use. This report describes the case of a 40 year old brittle asthmatic patient who died after treatment with intravenous N-acetylcysteine. Asthma is a risk factor for adverse reactions to N-acetylcysteine and special caution should be exercised in its use in brittle asthmatic patients.

Paracetamol overdose is a frequent reason for attendance to emergency departments and is the commonest method of deliberate self harm in the UK.¹ The use of N-acetylcysteine is a generally safe² and effective³ treatment to prevent hepatic and renal toxicity after paracetamol overdose.

We report the case of an asthmatic patient who died after the administration of N-acetylcysteine.

CASE REPORT

A 40 year old woman attended the emergency department after taking an intentional, staggered overdose of approximately 15 g of paracetamol over the preceding 48 hours (74 mg/kg/24 h).

She had a history of severe, corticosteroid dependent asthma with two previous admissions to intensive care, once requiring invasive ventilation. Her usual treatment included home salbutamol nebulizers and 60 mg prednisolone a day, although she had required continuous subcutaneous terbutaline and even methotrexate in the past. She also had depression, treated with fluoxetine and a previous untreated paracetamol overdose three years earlier. The patient had no known drug allergies, smoked five cigarettes a day, and drank alcohol regularly.

On arrival in the emergency department she was alert, talking in sentences with no signs of respiratory distress or cyanosis. Chest examination confirmed clear bilateral breath sounds. She was a morbidly obese woman of 101 kg, her pulse was 85 bpm, and blood pressure 125/80 mm Hg.

In view of the staggered overdose, she was empirically given a standard initial N-acetylcysteine infusion (150 mg/kg over 15 minutes). After five minutes she complained of feeling increasingly short of breath. There was no rash, tongue swelling, or hypotension but chest auscultation revealed severe bilateral wheeze with poor chest expansion. The N-acetylcysteine infusion was stopped immediately and nebulised salbutamol, intramuscular adrenaline (epinephrine) (1 mg), intravenous hydrocortisone (200 mg), and chlorpheniramine (10 mg) were given.

Despite these measures, and intravenous adrenaline (1 mg), she continued to deteriorate rapidly, becoming cyanosed and had a respiratory arrest. Senior anaesthetic help was immediately available but attempts to ventilate by bag and mask were

hampered by severe bronchospasm requiring immediate endotracheal intubation. Despite this, she became bradycardic and suffered a hypoxic cardiac arrest, spontaneous circulation only returning as her bronchospasm relaxed, after nine minutes of cardiopulmonary resuscitation.

The post-arrest serum mast cell tryptase level was 5.2 (NR 2–14 ng/ml) and her chest radiograph showed clear lung fields with no evidence of pneumothorax.

She was transferred to the intensive care unit for further treatment. Despite rapid improvement in her ventilation, she remained unresponsive with myoclonic jerks. Liver and renal function tests and INR remained normal throughout. Her clinical state, CT brain scan, and electroencephalograph were consistent with severe hypoxic brain injury and she died one week later without regaining consciousness.

DISCUSSION

Adverse reactions to N-acetylcysteine are common but rarely serious; anaphylactoid reactions occur in around 3% of cases and include, urticarial rash, angioedema, bronchospasm, and hypotension.^{2–4,6} These reactions, however, are usually mild and respond to stopping the infusion and symptomatic treatment with antihistamines. Usually the infusion can then be restarted at the 50 mg/kg over four hours dose.² Reactions with systemic features however, may require treatment with intramuscular adrenaline and corticosteroids.

Although there have been deaths associated with overdose of N-acetylcysteine,⁴ none have been reported with normal treatment doses. We describe the first fatal reaction to the therapeutic use of N-acetylcysteine. Our patient's response was consistent with an anaphylactoid reaction, confined to severe bronchospasm, rather than a generalised anaphylactic reaction and this was supported by the normal serum tryptase level.⁷ N-acetylcysteine is known to cause bronchospasm, probably because of local histamine release or inhibition of allergen tachyphylaxis⁸ and caution is advised in patients with asthma. Asthma is a known risk factor for side effects to N-acetylcysteine but is not considered a contraindication.⁹

Our patient's brittle asthma contributed to the severity of her reaction, but the dose and rate of N-acetylcysteine infusion given might also be important. Treatment was prescribed and given as recommended by the manufacturer's guidelines based upon whole bodyweight, however, no estimate of lean body mass was made (N-acetylcysteine does not distribute into fatty tissue¹⁰). In addition, some authors have recommended giving the initial infusion over 60 minutes in an attempt to reduce side effects¹¹ but trial evidence to support this practice is awaited.

The management of paracetamol overdose follows defined UK guidelines based upon serum paracetamol concentrations after single ingestions.¹² However, a staggered paracetamol overdose is more complex, as paracetamol concentrations cannot be used to guide treatment.¹³ Although controversial, treatment of these patients should be guided by the dose of paracetamol ingested. Patients who have ingested more than 150 mg/kg/24 h (75 mg/kg/24 h in high risk groups) should be treated with N-acetylcysteine.¹³ Our patient was treated as "high risk" as the exact amount of paracetamol taken could

not be verified, she frequently drank alcohol, and her ingested dose per lean body weight would have been considerably higher.

In conclusion, in most cases the use of N-acetylcysteine to treat paracetamol overdose is both safe and efficacious. Anaphylactoid reactions are common though usually mild. This case however, illustrates that the treatment of brittle asthmatic patients requires particular caution. This would include a careful risk/benefit assessment of treatment, precise N-acetylcysteine dose calculation, possible use of slowed initial drug infusion rates, close observation, and the immediate availability of resuscitation equipment and staff.

ACKNOWLEDGEMENTS

Many thanks to Dr Alison Jones and Dr Chris McLauchlan for reviewing the script and for their expert comments.

Authors' affiliations

A V Appelboam, J Knighton, Queen Alexandra Hospital, Portsmouth, UK

P I Dargan, National Poisons Information Service, London, UK

Correspondence to: Dr A Appelboam, Department of Anaesthetics, Torbay Hospital, Torquay, Devon TQ2 7AA; andy.bec@virgin.net

Accepted for publication 31 January 2002

REFERENCES

- 1 **Fagan E**, Wannan G. Reducing paracetamol overdoses. *BMJ* 1996;**313**:1417–18.
- 2 **Bailey B**, McGuigan MA. Management of anaphylactoid reactions to N-acetylcysteine. *Ann Emerg Med* 1998;**31**:710–15.
- 3 **Prescott LF**, Illingworth RN, Critchley JA, *et al*. Intravenous N-acetylcysteine: the treatment of choice for paracetamol poisoning. *BMJ* 1979;**2**:1097–100.
- 4 **Mant TG**, Tempowski JH, Volans GN, *et al*. Adverse reactions to acetylcysteine and effects of overdose. *BMJ* 1984;**289**:217–19.
- 5 **Dawson AH**, Henry DA, McEwen J. Adverse reactions to N-acetylcysteine during treatment for paracetamol poisoning. *Med J Aust* 1989;**150**:329–31.
- 6 **Ho SW**, Beilin LJ. Asthma associated with N-acetylcysteine infusion and paracetamol poisoning: report of two cases. *BMJ (Clin Res Ed)* 1983;**287**:876–7.
- 7 **Renz CL**, Laroche D, Thurn JD, *et al*. Tryptase levels are not increased during vancomycin-induced anaphylactoid reactions. *Anesthesiology* 1998;**89**:620–5.
- 8 **Dorsch W**, Auch E, Powerloowicz P. Adverse effects of acetylcysteine on human and guinea pig bronchial asthma in vivo and on human fibroblasts and leukocytes in vitro. *Int Arch Allergy Appl Immunol* 1987;**82**:33–9.
- 9 **Schmidt LE**, Dalhoff K. Risk factors in the development of adverse reactions to N-acetylcysteine in patients with paracetamol poisoning. *Br J Clin Pharmacol* 2001;**51**:87–91.
- 10 **Prescott LF**. Paracetamol (Acetaminophen). *A critical bibliographic review*. London: Taylor and Francis, 1996.
- 11 **Chan TY**, Critchley JA. Adverse reactions to intravenous N-acetylcysteine in Chinese patients with paracetamol poisoning. *Hum Exp Toxicol* 1994;**13**:542–4.
- 12 **UK National Poisons Information Service**. *Management of acute paracetamol poisoning*. Guidelines agreed by the UK National Poisons Information Service 1998. Supplied to Accident and Emergency Centres in the UK by the Paracetamol Information Centre, London in collaboration with the British Association for Accident and Emergency Medicine.
- 13 **Jones AL**. Recent advances in the management of late paracetamol poisoning. *Emergency Medicine* 2000;**12**:14–21.