

## CASE REPORTS

# Superior dislocation of the patella; a case report and review of the literature

R S Bassi, B A Kumar

*Emerg Med J* 2003;**20**:97–98

Superior dislocation of the patella is a rare diagnosis. A 72 year old woman attended the accident and emergency department of the hospital with a painful right knee after a knock to the knee. Clinical examination and radiographs confirmed a superior dislocation of the patella, which was reduced and closed with the aid of simple analgesia. The authors present the case report and discuss the relevant literature.

A 72 year old woman attended the hospital with inability to bend her right knee associated with pain. She had been standing and reaching out to grab something three hours earlier, when she felt a sudden pain in her knee. The woman was initially seen in the accident and emergency department where a diagnosis of ruptured patellar tendon was made. When seen by us, she was indeed unable to perform active straight leg raise. However, examination of the knee showed that there was no palpable gap in the patellar tendon. The superior pole of the patella was projecting anteriorly and there was a prominent dimple below the patella.

Plain radiographs showed that the patella was superiorly dislocated with interlocking osteophytes at the inferior pole of the patella and anterior surface of femur (fig 1). After the administration of intramuscular analgesia, the patella was

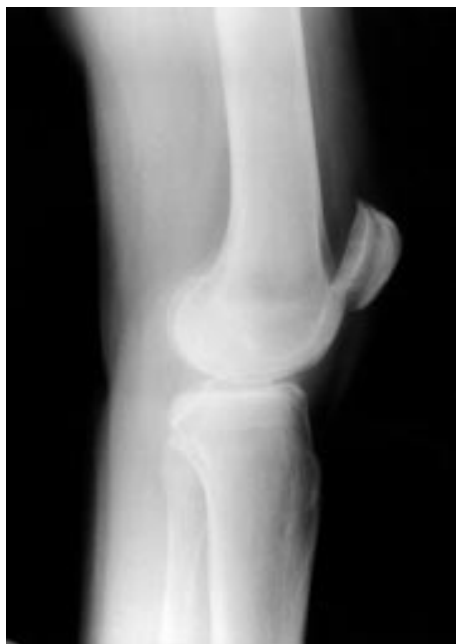gently moved from side to side and a click was felt. After this the patient was able to actively straight leg raise and flex the knee through its full range. Reduction of the dislocation was confirmed by plain radiograph (fig 2).

The woman was mobilised fully weight bearing without any restriction and at review four weeks later was found to be asymptomatic.

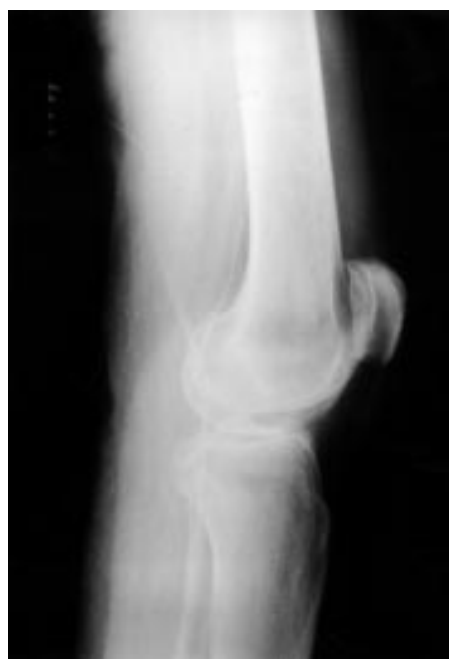### DISCUSSION

Superior dislocation of the patella is a rare diagnosis. Excluding this case there have been 14 previous such cases reported in the literature.<sup>1-12</sup> The average age of these patients is 58 years (range 43 to 81 years) and the ratio of male to female cases is equal. Two of these cases have been reported within the past year.<sup>1,2</sup> As previously predicted, it may well be that the frequency of this condition is increasing given the degenerative nature of the underlying cause and the increasing elderly population in our society.<sup>3</sup>

The woman in our case reports that she was leaning over a chair to pick something from the floor when the chair slipped and pushed her patella up. This is in keeping with previous cases where the underlying mechanism has been reported as a low energy posteriorly directed force on the inferior pole of the patella with or without eccentric contraction of the quadriceps.<sup>4</sup> Atraumatic cases in which the mechanism has been active quadriceps contraction and hyperextension of the knee have also been reported.<sup>1,3,5-7</sup>



**Figure 1** Lateral radiograph of the knee showing superior dislocation of the patella.



**Figure 2** Post-reduction radiograph.

Superior dislocation of the patella needs to be distinguished from patellar tendon rupture.<sup>8</sup> Both conditions cause an inability to perform straight leg raise. However, in the case of superior dislocation, the patellar tendon is intact. Also the patella is invariably tilted anteriorly because of the locking osteophyte in superior dislocation of the patella with a characteristic dimple below the patella.

In all previous cases reduction was achieved closed with one exception, which required open reduction after failure of closed reduction.<sup>9</sup> In the case presented reduction of the dislocation was achieved without the need for general anaesthesia or sedation. Previously, reduction required general anaesthesia in four cases. The rest were reduced with simple analgesia or sedation. Details of the reduction method are given in eight cases. This invariably entails gentle upward pressure on the inferior pole of the patella or medial-lateral pressure or a combination of both.

In summary this case highlights a rare case of superior dislocation of the patella. It is probable that this condition is increasing in frequency. It is important to distinguish this condition from patellar tendon rupture, which can be done by careful clinical assessment. After diagnosis, superior dislocation of the patella can be reduced closed with simple analgesia or sedation in most cases.

#### Contributors

Rashpal Bassi initiated the writing of the report and the literature search. B A Kumar supervised the writing of the report.

#### Authors' affiliations

R S Bassi, B A Kumar, Department of Orthopaedics, Russells Hall Hospital, Dudley, West Midlands, UK

Funding: none.

Conflicts of interest: none.

Correspondence to: Mr R S Bassi, 44 Beaudesert Road, Handsworth, Birmingham B20 3TG, UK; rash@doctors.net.uk.

Accepted for publication 1 May 2002

#### REFERENCES

- 1 **McWilliams TG**, Binns MS. A locked knee in extension: a complication of a degenerate knee with patella alta. *J Bone Joint Surg [Br]* 2000;**82**:890.
- 2 **Scott SJ**, Malloy A, Harvey RA. Superior dislocation of the patella – a rare but important differential diagnosis of acute knee pain – a case report and review of the literature. *Injury* 2000;**31**:543–5.
- 3 **Teuscher DD**, Goletz TH. Recurrent atraumatic superior dislocation of the patella: case report and review of the literature. *Arthroscopy* 1992;**8**:541–3.
- 4 **Bartlett DH**, Gilula LA, Murphy WA. Superior dislocation of the patella fixed by interlocking osteophytes. *J Bone Joint Surg [Am]* 1976;**58**:883–4.
- 5 **Wimsatt MH**, Carey MD. Superior dislocation of the patella. *J Trauma* 1977;**17**:77–80.
- 6 **Roth RM**, McCabe JB. Nontraumatic superior dislocation of the patella. *J Emerg Med* 1985;**3**:265–7.
- 7 **Takai S**, Yoshino N, Hirasawa Y. Arthroscopic treatment of voluntary superior dislocation of the patella. *Arthroscopy* 1998;**14**:753–6.
- 8 **Siegel MG**, Mac SS. Superior dislocation of the patella with interlocking osteophytes. *J Trauma* 1982;**22**:253–4.
- 9 **Rao JP**, Meese MA. Irreducible superior dislocation of the patella requiring open reduction. *Am J Orthop* 1997;**26**:486–8.
- 10 **Hanspal RS**. Superior dislocation of the patella. *Injury* 1985;**16**:487–8.
- 11 **Friden T**. A case of superior dislocation of the patella. *Acta Orthop Scand* 1987;**58**:429–30.
- 12 **Yoshino N**, Takai S, Nakamura S, et al. Recurrent horizontal dislocation of the patella in the sagittal plane. *J Bone Joint Surg [Am]* 1996;**78**:278–80.

## Haemodynamic and electrocardiographic consequences of severe nicorandil toxicity

J P Greenwood, I Malik, P Jennings, R N Stevenson

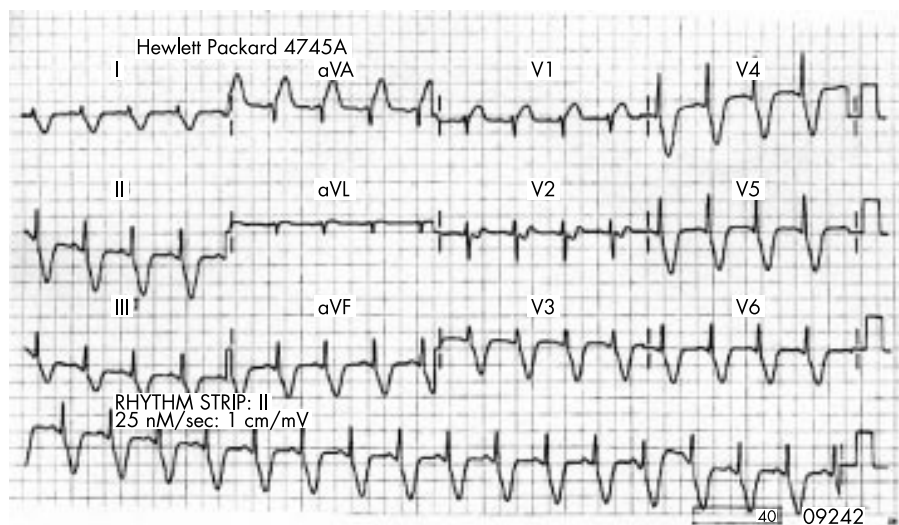
*Emerg Med J* 2003;**20**:98–100

A 35 year old woman was admitted to the emergency department two hours after ingesting 60×20 mg tablets of nicorandil, total 1.2 g. The dominant feature of nicorandil toxicity was profound peripheral vasodilatation associated with coronary hypoperfusion. Despite widespread electrocardiographic signs of myocardial ischaemia, there was no evidence of myocardial damage and no serious cardiac arrhythmia. Volume loading and pressor support proved to be an effective treatment strategy.

A 35 year old woman with no significant past medical history, was admitted to the emergency department two hours after ingesting 60×20 mg tablets of nicorandil, total 1.2 g. No other medication, illicit drugs, or alcohol were co-ingested. At presentation she had early signs of circulatory collapse (blood pressure 80/40 mm Hg; heart rate 140 beat/min) and required immediate fluid resuscitation. Initial biochemical screening revealed normal electrolytes and renal

function, and a poison screen (paracetamol and salicylate) was negative.

Over the next three hours, she developed symptoms and signs consistent with profound peripheral vasodilatation and became more hypotensive (blood pressure 55/30 mm Hg) despite further fluid resuscitation. She complained of central crushing chest pain, which was associated with severe ST segment depression and T wave inversion on the ECG (fig 1). Both arterial and central venous pressures were monitored invasively and she required inotropic support with intravenous noradrenaline (1.2 mg/h) and dopamine (3 µg/kg/min). The electrocardiographic changes resolved as the blood pressure improved, although she continued to vomit and complain of headache up to eight hours after presentation. Cardiac monitoring showed frequent multifocal ventricular extrasystoles but there were no sustained tachyarrhythmias. Biochemical monitoring revealed a transient increase in the serum creatinine (peak 176 µmol/l) and liver transaminases (aspartate transferase 164 IU/l; alanine transferase 71 IU/l), which normalised by 48 hours. Serum potassium, calcium and creatine kinase remained within the normal range; troponin assay was not available and hence values were not measured. She



**Figure 1** ECG performed about six hours after overdose demonstrating widespread ischaemia with deep ST depression and T wave inversion.

was weaned off all inotropic support within 24 hours of admission and made a complete recovery. Pre-discharge exercise stress testing using the standard Bruce protocol was uneventful.

## DISCUSSION

The recently published IONA Study has shown a beneficial effect on major coronary events by the use of nicorandil in patients with chronic stable angina.<sup>1</sup> As a result of this trial it is probable that the use of nicorandil in the treatment of angina will increase, which could also increase the potential for accidental or deliberate self harm with this agent. As far as the authors are aware, this is the first description of the effects of nicorandil in severe overdose.

Nicorandil, a potassium channel activator, is the first agent in its therapeutic class to be licensed for the treatment of angina. Its oral bioavailability is 75%–80%, maximal plasma concentrations being achieved within 30–60 minutes after dosing, with a plasma half life of about one hour and therapeutic efficacy extending to 12 hours. Nicorandil is hepatically metabolised and renally excreted. Its mechanism of action is complex, and includes both a nitrate-like effect and in addition, activation of sarcolemmal and mitochondrial ATP sensitive potassium ( $K_{ATP}$ ) channels. This leads to vasodilatation in coronary vessels and also in the venous and arterial systems, leading to a reduction in preload, afterload, and hence myocardial oxygen consumption and work.<sup>2,3</sup> As a result of the above actions, nicorandil in double blind randomised studies, has been shown to be comparable as an anti-anginal agent to  $\beta$  blockers, calcium antagonists, and nitrates.<sup>4,5</sup> In addition to its anti-ischaemic properties, nicorandil may also confer additional benefits related to myocardial pre-conditioning and cardioprotection.<sup>6,7</sup>

The patient in this report had both symptomatic and ECG evidence of myocardial ischaemia, presumably as a result of coronary hypoperfusion. Volume loading and pressor support provided the most effective treatment strategy for reversing the effects of profound peripheral vasodilatation. It is interesting that in this case, despite ECG evidence of severe global myocardial ischaemia, there was no evidence of significant myocardial damage. Furthermore, it has been suggested that because of its mechanism of action, nicorandil could shorten the action potential duration, and be potentially pro-arrhythmic. However, studies so far have suggested this is not the case<sup>8</sup> and, paradoxically, nicorandil may have anti-arrhythmic properties.<sup>7</sup> Indeed, there is anecdotal evidence to

suggest that nicorandil can shorten the QT interval and terminate torsades de pointes,<sup>9</sup> and idiopathic VT.<sup>10</sup> Certainly in this report of where almost 20 times the recommended daily dose was consumed, there was no evidence of sustained tachyarrhythmia.

Finally, the patient in this report experienced many of the reported side effects associated with nicorandil, most of which are attributable to its vasodilatory action. These include headache, flushing, dizziness, tachycardia, and hypotension. Other less common side effects have included oral aphthous ulceration, angioneurotic oedema, and photosensitivity.<sup>8</sup> Although liver toxicity has been described,<sup>8</sup> and elimination of nicorandil is largely dependent on hepatic metabolism,<sup>5</sup> liver transaminases were only minimally increased in our patient.

In summary, this is the first description of severe nicorandil overdose. The dominant feature of nicorandil toxicity was profound peripheral vasodilatation associated with coronary hypoperfusion. Despite widespread electrocardiographic signs of myocardial ischaemia, there was no evidence of myocardial damage and no serious cardiac arrhythmia. Volume loading and pressor support proved to be an effective treatment strategy.

## Authors' affiliations

**J P Greenwood**, Academic Unit of Cardiovascular Medicine, Yorkshire Heart Centre, The General Infirmary, Leeds, UK  
**I Malik**, Aintree University Hospital, Liverpool, UK  
**P Jennings, R N Stevenson**, Huddersfield Royal Infirmary, Huddersfield, UK

Correspondence to: Dr J P Greenwood, Academic Unit of Cardiovascular Medicine, G Floor, Jubilee Wing, Yorkshire Heart Centre, The General Infirmary, Great George Street, Leeds LS1 3EX, UK; john\_greenwood@hotmail.com

Accepted for publication 26 September 2002

## REFERENCES

- The IONA Study Group.** Effect of nicorandil on coronary events in patients with stable angina: the impact of nicorandil in angina (IONA) randomised trial. *Lancet* 2002;**359**:1269–75.
- Akai K, Wang Y, Sato K, et al.** Vasodilatory effect of nicorandil on coronary arterial microvessels: its dependency on vessel size and the involvement of the ATP-sensitive potassium channels. *J Cardiovasc Pharmacol* 1995;**26**:541–7.
- Purcell H, Patel D, Mulcahy D, Fox KM, et al.** In: Messerli FH, ed. *Cardiovascular drug therapy*. Philadelphia: WB Saunders, 1996:1638–45.

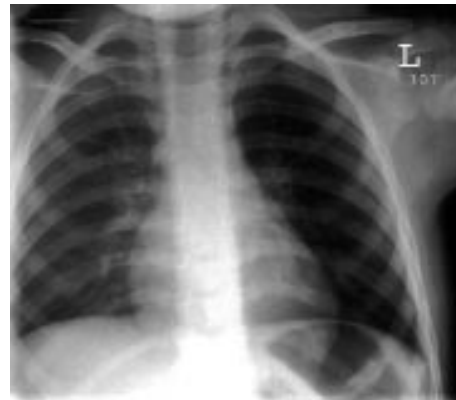- 4 **Krumenacker M**, Roland EO. Clinical profile of nicorandil: an overview of its haemodynamic properties and therapeutic efficacy. *J Cardiovasc Pharmacol* 1992;**20**:S93-102.
- 5 **Frampton J**, Buckley M, Fitton A. Nicorandil: a review of its pharmacology and therapeutic efficacy in angina pectoris. *Drugs* 1992;**44**:625-55.
- 6 **Ito H**, Taniyama Y, Iwakura K, et al. Intravenous nicorandil can preserve microvascular integrity and myocardial viability in patients with reperfused anterior wall myocardial infarction. *J Am Coll Cardiol* 1999;**33**:654-60.
- 7 **Patel DJ**, Purcell HJ, Fox KM. Cardioprotection by opening of the K(ATP) channel in unstable angina. Is this a clinical manifestation of myocardial preconditioning? Results of a randomised study with nicorandil. (CESAR 2 investigation: Clinical European studies in angina and revascularisation). *Eur Heart J* 1999;**20**:51-7.
- 8 **Dunn N**, Freemantle S, Pearce G, et al. Safety profile of nicorandil - prescription-event monitoring (PEM) study. *Pharmacoepidemiology and Drug Safety* 1999;**8**:197-205.
- 9 **Watanabe O**, Okumura T, Takeda H, et al. Nicorandil, a potassium channel opener, abolished torsades de pointes in a patient with complete atrioventricular block. *Pacing Clin Electrophysiol* 1999;**22**:686-8.
- 10 **Kobayashi Y**, Miyata A, Tanno K, et al. Effects of nicorandil, a potassium channel opener, on idiopathic ventricular tachycardia. *J Am Coll Cardiol* 1998;**32**:1377-83.

## Delayed diagnosis of foreign body aspiration in children

T Hilliard, R Sim, M Saunders, S Langton Hewer, J Henderson

*Emerg Med J* 2003;**20**:100-101

Foreign body aspiration in children is common and usually presents with an initial episode of choking with subsequent respiratory symptoms. There may be cough, wheeze, or stridor, with decreased or abnormal breath sounds on examination. However, it can mimic other illnesses and cause difficulty in diagnosis. Radiological investigations may help to confirm aspiration but should not be used to exclude it. Three cases are presented of foreign body aspiration with a delay in diagnosis ranging from days to weeks. It is believed that delay could have been avoided with a more careful approach to the history and more appropriate use of investigations. These cases demonstrate that children with a history of choking and subsequent symptoms should be referred for bronchoscopy.



**Figure 1** Expiratory chest radiograph showing left sided hyperlucency.

Foreign body aspiration most commonly affects young children, with respiratory symptoms such as wheeze and cough after a choking episode.<sup>1</sup> A careful history and clinical examination can identify those children that need additional investigation including bronchoscopy.<sup>2</sup> However foreign body aspiration can mimic other conditions and the link between choking and subsequent symptoms may not be made by parents and professionals alike. We present three cases with a delay in diagnosis, and discuss the appropriate management of suspected foreign body aspiration.

### CASE REPORTS

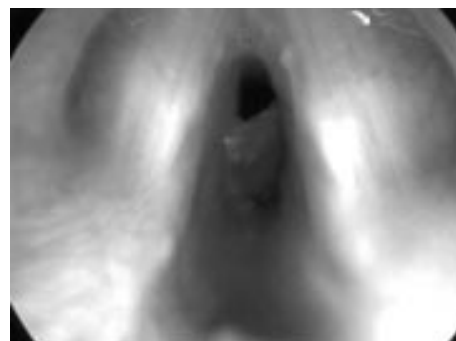
#### Case 1

A 2 year old boy presented to the emergency department with wheeze and cough. His symptoms had followed a choking episode while eating a chicken leg two days previously. A chest radiograph was interpreted as normal and he was given inhaled bronchodilator with some improvement and was allowed home. He continued to wheeze and cough and re-presented four weeks later. He was sent home but on review the next day had expiratory wheeze that was louder on the left side of his chest. Inspiratory and expiratory chest radiographs showed left sided hyperinflation (fig 1). Flexible bronchoscopy under general anaesthesia revealed a foreign body in the left main bronchus and a chicken bone was removed with rigid bronchoscopy.

#### Case 2

A 2 year old boy developed noisy breathing after a choking episode while playing with a pistachio nut shell. The next day

he had increasing difficulty in breathing and his general practitioner referred the child to the emergency department. He was thought to have acute asthma and was given nebulised bronchodilators, oral corticosteroid, and then an aminophylline infusion. After five hours of treatment there was little improvement and he continued to have noisy breathing, recession, and tachypnoea. A chest radiograph showed bilateral hyperinflation. On review he had biphasic stridor more likely to be attributable to upper airway obstruction. He underwent rigid bronchoscopy under general anaesthesia with removal of a pistachio nut shell from just under the vocal cords (fig 2).



**Figure 2** Rigid laryngoscopy showing pistachio nut shell in trachea just below vocal cords.

### Case 3

A 10 year old boy had a coughing fit while chewing on a pen top and subsequently realised that the inside of the pen top was missing. He was sent home from the local emergency department after a normal chest radiograph. Two days later he started to wheeze and cough. A chest radiograph was again normal, but he had wheeze that was louder on the right side of the chest and a fever. He was given intravenous antibiotics but he did not improve and the following day was transferred to the regional paediatric centre for assessment. With rigid bronchoscopy under general anaesthesia the pen top was removed from his right main bronchus.

### DISCUSSION

Foreign body aspiration by children, especially those below the age of 3 years, is common.<sup>1</sup> If it causes airway occlusion it may lead to asphyxia and it is unfortunately a leading cause of death in childhood.<sup>3</sup> However, it more often presents with a history of an initial episode of choking and coughing with subsequent respiratory symptoms.<sup>1,2</sup> These include cough, wheeze, stridor, or pneumonia. The most common physical sign is decreased or abnormal breath sounds.<sup>1,4</sup> Most inhaled foreign bodies in children are food items, with peanuts being the most common.<sup>4</sup>

However, there is often significant delay until the diagnosis is made.<sup>1,4,5</sup> In one series a delay of over three days between aspiration and removal of the foreign body was reported in almost 30% of children.<sup>1</sup> This may be attributable to a high rate of initial alternative diagnoses and this occurred in 24% of cases in a separate series.<sup>4</sup> Foreign body aspiration can be misdiagnosed as asthma, upper respiratory tract infection, pneumonia, or croup.<sup>1</sup> Delay in diagnosis is associated with increased morbidity, especially respiratory infection.<sup>5</sup>

Most foreign bodies in children are radiolucent, but they may be associated with hyperinflation, atelectasis, or consolidation. In a series of 189 children with proven foreign body aspiration, 90 cases (47.6%) had normal chest radiographs.<sup>6</sup> Inspiratory and expiratory films, and fluoroscopy can provide extra information, but even these may be normal in children who later are found to have an inhaled foreign body at bronchoscopy.<sup>1</sup> Probably the most important feature of aspirated foreign bodies in children is the initial history of choking. In a series of 87 children who underwent bronchoscopy, a history of a choking episode was present in 67 of 70 with a foreign body and in only 4 of 17 without a foreign body.<sup>2</sup> The choking history showed a sensitivity of 96% and a specificity of 76%. However, the episode may be unwitnessed, or volunteered only after specific inquiry.<sup>3</sup>

When there is impaction of a foreign body in a major airway with acute respiratory distress and hypoxia the child should be resuscitated according to accepted guidelines.<sup>7</sup> If urgent operative removal is required it should be carried out by the

most experienced surgical and anaesthetic personnel available. However, when an emergency procedure is not indicated then transfer to a centre with regular experience of airway endoscopy in children should occur. In our centre we prefer to have available the option of both flexible and rigid bronchoscopy. If the diagnosis is in doubt flexible bronchoscopy can be used to examine more distal parts of the bronchial tree and more confidently exclude a foreign body than rigid bronchoscopy.<sup>8</sup> However, flexible bronchoscopy plays little part in the extraction of foreign bodies.

Children who have a sudden onset of choking and coughing should be taken seriously. Most important is a thorough history of the initial episode and if there are persistent symptoms then the child should be referred for bronchoscopic evaluation.

### Contributors

Tom Hilliard had the original idea, performed the literature search, and produced the draft manuscript. Richard Sim commented on the draft manuscript. Mike Saunders, Simon Langton Hower and John Henderson were responsible for the management of the three cases and commented on the draft manuscript. John Henderson is guarantor for the article.

### Authors' affiliations

**T Hilliard, S Langton Hower, J Henderson**, Department of Respiratory Medicine, Royal Hospital for Children, Bristol, UK  
**R Sim, M Saunders**, Department of Ear, Nose and Throat Surgery, Royal Hospital for Children, Bristol

Funding: none.

Competing interests: none declared.

Correspondence to: Dr T Hilliard, Department of Respiratory Medicine, Royal Hospital for Children, Upper Maudlin Street, Bristol BS2 8BJ, UK; tom.hilliard@ubht.swest.nhs.uk

Accepted for publication 1 May 2002

### REFERENCES

- 1 **Tan HKK**, Brown K, McGill T, *et al.* Airway foreign bodies (FB): a 10 year review. *Int J Pediatr Otorhinolaryngol* 2000;**56**:91–9.
- 2 **Metrangolo S**, Monetti C, Meneghini L, *et al.* Eight years' experience with foreign body aspiration in children: what is really important for a timely diagnosis? *J Pediatr Surg* 1999;**34**:1229–31.
- 3 **National Safety Council.** *Accident facts.* Chicago, IL: National Safety Council, 1991:24.
- 4 **Steen KH**, Zimmerman T. Tracheobronchial aspiration of foreign bodies in children: a study of 94 cases. *Laryngoscope* 1990;**100**:525–30.
- 5 **Oguz F**, Citak A, Unuvar E, *et al.* Airway foreign bodies in childhood. *Int J Pediatr Otorhinolaryngol* 2000;**52**:11–16.
- 6 **Zarella JT**, Dimler M, McGill LC, *et al.* Foreign body aspiration in children: value of radiography and complications of bronchoscopy. *J Pediatr Surg* 1998;**33**:1651–4.
- 7 **Advanced Paediatric Life Support.** *The practical approach.* Advanced Life Support Group. London: BMJ Books, 2000.
- 8 **Martinot A**, Closset M, Marquette CH, *et al.* Indications for flexible versus rigid bronchoscopy in children with suspected foreign-body aspiration. *Am J Respir Crit Care Med* 1997;**155**:1676–9.

# Haemoptysis as a late presentation of aneurysm leakage after aortic coarctation repair: The case for vigilant lifelong radiology surveillance?

D Menon, T Burdge

*Emerg Med J* 2003;**20**:102–103

A 35 year old white man previously fit and well presented to the emergency department late one evening, with an episode of haemoptysis. He developed sudden left chest pain and breathlessness while having a drink in a local pub. The history obtained by the ambulance crew was that he coughed up half a litre of blood in the pub toilet.

On initial examination he was conscious but visibly distressed. He was noted to be tachypneic (respiratory rate 28 breath/min) and in severe pain over his chest and back. His initial pulse rate was 112 beat/min and his blood pressure was 141/93. The well healed scar of a thoracotomy was noted over the left side of his chest.

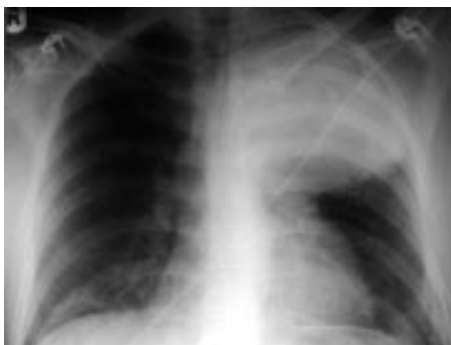His partner who was present explained it was for the repair of a "hole in the heart" 23 years ago, when he was aged 12. He had been on follow up for a few years after the surgery by the tertiary cardiac centre and then discharged to his primary care practitioner. The last chest radiograph he had was more than 10 years ago. He had otherwise been fit and well and participated actively in sport.

The patient had 100% oxygen administered by non-rebreathing mask with a reservoir bag and intravenous access was obtained with wide bore cannulas. Blood was taken for grouping and cross matching.

Despite high flow oxygen the best saturation obtained was 89% by pulse oximetry. A blood gas sample taken showed marked hypoxia and mild acidosis (table 1). Intravenous morphine was administered with temporary relief of pain requiring repeated titrated doses. An ECG showed sinus tachycardia. An urgent portable chest radiograph was done (fig1).

His condition rapidly deteriorated and he collapsed from torrential bouts of haemoptysis requiring endotracheal intubation, emergency blood, fluids, and cardiopulmonary resuscitation. He failed to respond to advanced life support resuscitation and was pronounced dead.

A postmortem examination showed an 8 cm thin walled aneurysm of the arch of aorta and proximal descending thoracic aorta that had ruptured into the upper lobe of the left lung and pleural cavity.



**Figure 1** Portable chest radiograph showing the aneurysm in the upper zone of the left lung field.

**Table 1** 100% oxygen facemask with oxygen reservoir

pO <sub>2</sub>	9.19 (low)	HCO <sub>3</sub> <sup>-</sup>	26.4
pCO <sub>2</sub>	6.96	BE	-0.1
H+	49.19	Anion gap	12.32

## DISCUSSION

Haemoptysis as a presenting symptom of leaking aortic aneurysm after coarctation repair has been previously described in the literature.<sup>1</sup> Aortic patch graft repair was first performed in the United Kingdom by Charles Drew in Westminster Hospital half a century ago.<sup>2</sup> Between 1976 and 1982 patch aortoplasty was the routine procedure of choice.<sup>3</sup>

Aneurysm formation rate after the repair has been described in long term follow up studies (up to 15 years after surgery) to be between 3.8% and 27%.<sup>4,5</sup> Our patient presented 23 years after his surgery with a ruptured aneurysm.

Some 32.8% of patients in one study who had patch graft aortoplasty for aortic coarctation underwent reoperation because of aneurysm formation at the site or opposite to the patch graft.<sup>6</sup>

The argument for lifelong radiological surveillance by plain radiology (chest radiograph), Doppler ultrasound, or computed axial tomography for asymptomatic patients with previous coarctation patch repair is very strong indeed from these reports. This can be along the lines of treatment for patients diagnosed to have early abdominal aneurysms.

General practitioners who have such patients on their lists are ideally suited to undertake this role and should review them on a regular basis with screening surveillance radiography.

In conclusion, vascular events like aneurysm ruptures and dissections are by their nature often catastrophic if they present late in their clinicopathological course. They are literally like "ticking time bombs" pulsing to our heart rhythm. Early recognition of possible predisposing factors like age, atherosclerosis, hypertension, and previous risk related surgery (for example, aortic surgery) entails us to be vigilant in our follow up of the patient at risk of premature death and significant morbidity.

## Contributors

Dilip Menon did the literature search, wrote the manuscript of the case report, and is guarantor for the paper. Tony Burdge did the post-mortem examination and report and reviewed the manuscript of this case report.

## Authors' affiliations

**D Menon**, Accident and Emergency Department, Wrexham-Maelor Hospital, Wrexham, UK

**T Burdge**, Pathology Department, Wrexham-Maelor Hospital

Competing interest: the first author was directly involved in the initial care

of this patient whose condition he diagnosed only when the portable chest radiograph showed the abnormality demonstrated. In writing this case report, he seeks to share his experience and highlight this condition to the wider emergency and primary care medical community.

Correspondence to: Mr D Menon, Accident and Emergency Department, Wrexham-Maelor Hospital, Wrexham LL13 7TD, UK; DiMenon@doctors.org.uk

Accepted for publication 13 June 2002

## REFERENCES

1 **Pearse EO**, Bryan AJ. Massive haemoptysis 27 years after surgery for coarctation of the aorta. *J R Soc Med* 2001;**94**:640-1.

- 2 **Stewart AB**, Ahmed R, Travill CM, *et al*. Coarctation of the aorta life and health 20-years after surgical repair. *Br Heart J* 1993;**69**:65-70.
- 3 **John CN**, Cartmill TB, Johnson DC, *et al*. Report of four cases of aneurysm complicating patch aortoplasty for repair of coarctation of the aorta. *Aust NZ Surg* 1989;**59**:748-50.
- 4 **Ala-Kulju K**, Jarvinen A, Maamies T, *et al*. Late aneurysms after patch aortoplasty for coarctation of the aorta in adults. *Thorac Cardiovasc Surg* 1983;**31**:301-6.
- 5 **Heikkinen LO**, Ala-Kulju KV, Salo JA, *et al*. Dilatation of ascending aorta in patients with repaired coarctation. *Scand J Thorac Cardiovasc Surg* 1991;**25**:25-8.
- 6 **Ala-Kulju K**, Heikkinen L. Aneurysm after patch graft aortoplasty for coarctation of the aorta: long term results of surgical management. *Ann Thorac Surg* 1989;**47**:853-6.

# First branchial cleft anomaly presenting as a recurrent post-auricular abscess

M A Siddiq

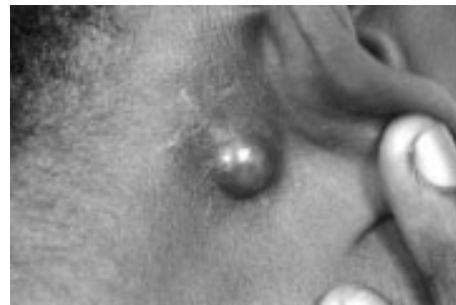*Emerg Med J* 2003;**20**:103-104

Embryological anomalies of the first branchial cleft are uncommonly encountered. They usually present as cysts, swellings, or fistulas in the pre-auricular or post-auricular area or high in the neck, which may become infected. Failure to recognise these unusual cases may result in misdiagnosis, inadequate treatment, and subsequent recurrence. Further definitive surgery may thus be complicated. A case is reported of a patient who attended accident and emergency on three occasions with an infected post-auricular cyst, which was treated by incision and drainage. It was subsequently found to be a first branchial cleft anomaly.

A 15 year old boy presented with a two year history of a recurrently infected cyst behind his right ear. He had initially presented to the accident and emergency (A&E) department with an infected swelling behind his right ear. This was treated in the department with incision and drainage under local anaesthetic. It recurred six months later and another presentation to the A&E department resulted in further incision and drainage under local anaesthetic. This lesion recurred again three months later and was treated in the A&E department with excision under local anaesthetic. The lesion had become infected on two further occasions but had settled with a course of antibiotics from the general practitioner.

On presentation to the ear, nose, and throat clinic, there was a cystic swelling in the right post-auricular region inferiorly, with evidence of some scarring (fig 1). Examination of the external auditory meatus revealed the presence of a pit on the postero-inferior wall. The remainder of the ENT examination including examination of the neck was normal. A provisional diagnosis of a first branchial cleft anomaly was made. Computed tomography with contrast was performed, which showed the extent of the lesion with an associated tract running along the posterior wall of the external auditory meatus.

The patient underwent an exploration of the lesion, which confirmed the presence of a sinus communicating between the pit seen on examination and the cyst, thus confirming the diagnosis. Histological examination revealed the tract to be



**Figure 1** Cystic lesion in the right post-auricular area with scarring of overlying skin.

lined with stratified squamous epithelium thus establishing the ectodermal nature of the lesion.

## DISCUSSION

First branchial cleft anomalies are uncommon and comprise 1%–8% of all branchial cleft anomalies.<sup>1</sup> They often present in the first two decades of life and present a clinical challenge as they can easily be misdiagnosed and thus inappropriately treated. They are thought to arise as a result of developmental abnormalities of the branchial apparatus and may take the form of a cyst, sinus, or fistula.<sup>2</sup>

Clinically they may present with repeated episodes of infection of the lesion. This may manifest itself with a cystic swelling or discharge from a fistulous opening either pre-auricularly or post-auricularly, in the cheek, or high in the neck. A thorough otological examination should be performed in all cases and may reveal a pit visible in the external canal at the site of entrance of a sinus or fistula. Such a lesion may result in otorrhoea or otitis externa with infective exacerbations. The meatus may be found to be partially or completely obstructed by bulging of the canal wall because of a cystic swelling. Such patients may complain of hearing loss, as may those with oedema associated with an otitis externa. There may however be a complete absence of signs in the external auditory canal. The patient may also give a history of having to repeatedly undergo incision and drainage of an apparent

abscess around the ear because of infective exacerbations of the lesion that has not resolved.

Early diagnosis and treatment are needed to avoid recurrent infection as scarring may cause difficulties with surgical dissection.<sup>3</sup> Acute infective episodes should ideally be treated conservatively with antibiotics. However, this may not always be successful in settling the acute condition and referral for incision and drainage may still be required in some situations.

Computed tomography with contrast will help define the extent of the lesion and identify extension into the middle ear.

Surgical exploration and excision is the definitive treatment of these defects and should only be undertaken when any acute infective episode has cleared.<sup>4,5</sup>

In conclusion, cysts, sinuses, or fistulous tracts, which are pre-auricular or post-auricular or high in the neck may represent a branchial cleft anomaly. A high index of suspicion is required and a thorough otological examination and careful history should be undertaken. If suspected the patient should be referred for a specialist otological opinion as attempted drainage may complicate further definitive surgery.

.....

#### Author's affiliations

**M A Siddiq**, Department of Otorhinolaryngology, Head and Neck Surgery, St George's Hospital, London, UK Correspondence to: Mr M A Siddiq, 125 Broadway, Walsall, West Midlands WS1 3HB; azher@excite.co.uk

Accepted for publication 14 June 2002

#### REFERENCES

- 1 **Ford G**, Balakrishnan A, Evans J, *et al*. Branchial cleft and pouch anomalies. *J Laryngol Otol* 1992;**106**:137-43.
- 2 **Ikarashi F**, Naqano Y, Nonomura N, *et al*. Clinical features of first branchial cleft anomalies. *Am J Otolaryngol* 1996;**17**:233-9.
- 3 **Nofsinger YC**, Tom WCL, Larossa D, *et al*. Periauricular cysts and sinuses. *Laryngoscope* 1997;**107**:883-7.
- 4 **Mounsey A**, Forte V, Friedberg J. First branchial cleft sinuses: an analysis of current management strategies and treatment outcomes. *J Otolaryngol* 1993;**22**:457-61.
- 5 **May M**, D'Angelo A. The facial nerve and the branchial cleft: surgical challenge. *Laryngoscope* 1989;**99**:564-5.

## Scrotal pain in the absence of torsion; need for vigilance

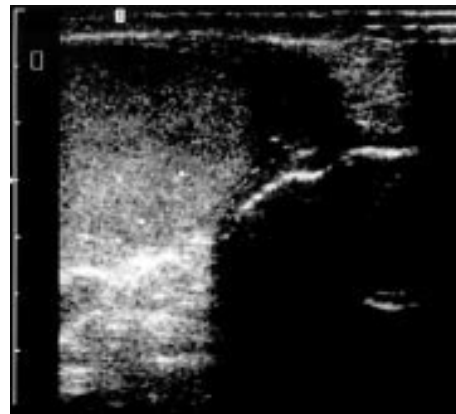
S Venketraman, J P Gray, P A Evans

*Emerg Med J* 2003;**20**:104-105

Epididymitis is a common presentation of acute testicular pain seen in the emergency department, the differential diagnosis being testicular torsion. The vast majority of young men with epididymitis have an infective aetiology and this settles with antibiotic treatment. The clinical course of a patient who presented with testicular pain is described. At ultrasonography, the patient was found to have the uncommon condition of testicular microlithiasis, a condition that has been linked to malignant disease. Emergency doctors should be aware of the potential consequences of returning scrotal pain consistent with epididymitis to the community on antibiotic treatment alone. All patients with probable epididymitis should have either a scrotal ultrasound or specialist follow up.

**A** 22 year old white man presented to the emergency department of the Leicester Royal Infirmary complaining of an increasingly painful left testicle, after mild blunt scrotal trauma sustained five days previously. The pain had not been alleviated by over the counter non-steroidal analgesia. He described no urinary symptoms and had not had intercourse for some months. He gave a history of chronic bilateral testicular tenderness and had been treated for epididymitis in the past.

On examination, he was afebrile. Scrotal examination revealed a very tender left epididymis and a mildly tender right epididymis, clinically inconsistent with torsion. Urine analysis was negative. An ultrasound scan of the scrotum was arranged from the emergency department, which was reported as a bilateral epididymitis and bilateral testicular microlithiasis with no haematoma or infarct seen (fig 1). The patient was discharged with antibiotic treatment and urology outpatient follow up.



**Figure 1** Scrotal ultrasound shows the testis (upper left quadrant) with microliths (small white dots). There is also evidence of epididymitis present, depicted by a thickened oedematous epididymis (lower left quadrant).

#### DISCUSSION

Epididymitis itself is not an uncommon emergency department presentation. However, because of a lack of epidemiological data the actual incidence is unknown. Symptoms are usually unilateral and patients generally present with testicular pain accompanied by a tender swollen epididymis. They may present with dysuria, fever, scrotal erythema, and orchitis. Epididymitis is mostly infective in aetiology, with *Chlamydia trachomatis* and *Neisseria gonorrhoeae* being the two most common sexually transmitted organisms.<sup>1</sup> From an emergency department perspective, the important diagnosis to exclude is testicular torsion. Simultaneous bilateral epididymitis as in this case is rare. In a review of 610 cases, bilateral epididymitis was noted in only 9% and in a proportion of these



the initial presentation was unilateral and thereafter developed bilaterally.<sup>2</sup>

First documented in the 1960s as microcalcification within the lumina of seminiferous tubules, testicular microlithiasis is a rare diagnostic entity.<sup>3</sup> As an essentially asymptomatic pathology, the prevalence in the male population remains unknown. Radiological studies assessing the incidence on ultrasonography have quoted figures ranging from 0.16% to 4%.<sup>4</sup> Specific postmortem investigation to assess the incidence suggests a figure of 4% for adult men.<sup>5</sup> Electron microscopy in the 1980s confirmed these deposits as consisting of a central calcified core surrounded by cellular debris, glycoprotein, and collagen.<sup>6</sup> On ultrasound the deposits are less than 2 mm in diameter, hyperechoic, and tend not to cast an acoustic shadow. Reported associations include cryptorchidism, Klinefelter's syndrome, infertility, testicular pain, and testicular neoplasm.<sup>4,7</sup> It has therefore been suggested that testicular microlithiasis should be considered a premalignant condition, and patients should have clinical and ultrasonographic follow up.<sup>8</sup>

As far as we are aware, there is no previous published case of bilateral epididymitis and bilateral microlithiasis occurring simultaneously in the same patient. This case reports standard emergency department management of acute testicular pain, following a pathway geared to excluding a diagnosis of testicular torsion. Once excluded, many patients are discharged from the emergency department with antibiotic treatment and often no specialist follow up.

This case highlights the importance of vigilance among emergency clinicians with regard to the painful scrotum in the absence of testicular torsion. Indeed, the take home message for us to learn here is that a clinical diagnosis of epididymitis without a scrotal ultrasound and or urology follow up is potentially hazardous.

### Contributors

Shakthi Venketraman and Jim Gray realised this case merited reporting and conducted a literature search. Philip Evans edited the paper, stands guarantor, and oversaw the project. All authors contributed to writing the case report.

### Authors' affiliations

**S Venketraman, J P Gray, P A Evans**, Department of Accident and Emergency Medicine, The Leicester Royal Infirmary, Leicester, UK

Correspondence to: Dr S Venketraman, 9 Stockwell Road, Leicester LE2 3PN, UK; drsvenketraman@ntlworld.com

Accepted for publication 14 June 2002

### REFERENCES

- 1 **Luzzi GA**, O'Brien TS. Acute epididymitis. *BJU International* 2001;**87**:747–55.
- 2 **Mittmeyer BT**, Lennox KW, Borski AA. Epididymitis: a review of 610 cases. *J Urol* 1966;**95**:390–2
- 3 **Bunge RG**, Bradbury RT. Intratubular bodies of the human testes. *J Urol* 1961;**85**:306.
- 4 **Skyrme RJ**, Fenn NJ, Jones AR, *et al*. Testicular microlithiasis in a UK population: its incidence, associations and follow-up *BJU International* 2000;**86**:482–5.
- 5 **Renshaw A**. Testicular calcifications: incidence, histology and proposed pathological criteria for testicular microlithiasis. *J Urol* 1998;**160**:1625–8.
- 6 **Vegni-Talluri M**, Bigliardi E, Vanni MG, *et al*. Testicular microliths: their origin and structure. *J Urol* 1980;**124**:105–7.
- 7 **Duchek M**, Bergh A, Oberg L. Painful testicular lithiasis. *Scand J Urol Nephrol Suppl* 1991;**138**:231–3.
- 8 **Derogee M**, Bevers RF, Prins HJ, *et al*. Testicular microlithiasis, a premalignant condition: prevalence, histopathologic findings and relation to testicular tumour. *Urology* 2001;**57**:1133–7.

# Unusual presentation of atrial fibrillation

P Muthu, G Oduro, M Sakr, D A Esberger

*Emerg Med J* 2003;**20**:106–108

A case is reported of atrial fibrillation in a young healthy man after head injury and the possible causes are discussed. The atrial fibrillation reverted spontaneously to normal rhythm in two days. The authors are not aware of a similar report in the literature.

A 33 year old male police officer was brought to the accident and emergency department after being found unconscious in the street. The exact mechanism of injury was not known, though the paramedics had obtained the history from bystanders that the patient had been trying to apprehend a suspect. He was confused and disoriented and could not remember how he had sustained his injuries. He was complaining of headache and was vomiting repeatedly. He was not complaining of neck pain or chest pain.

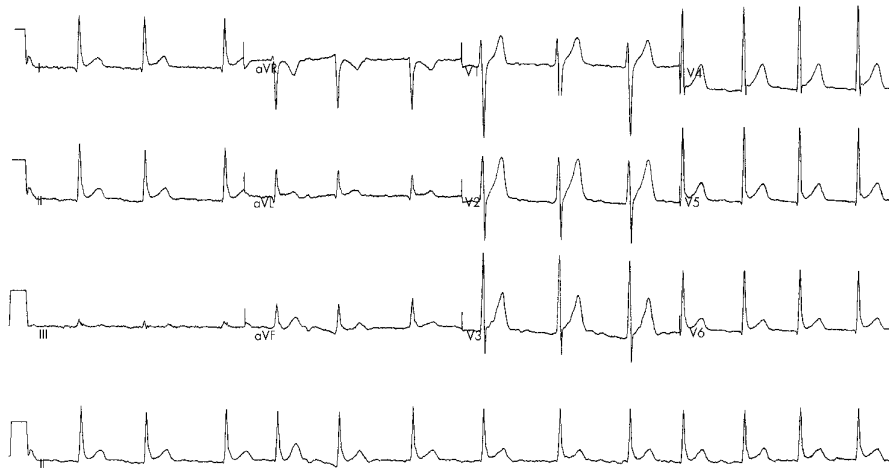
On examination his airway, breathing and circulation were normal. His Glasgow Coma Score was 13/15. His pupils were equal and reacting to light. His pulse was 96/minute and blood

pressure was 136/60 mm Hg. His cardiovascular system, respiratory system, and abdomen were normal. Bleeding from the left ear and swelling and tenderness over the nasal bones was noted. No chest injury or any other injuries were seen.

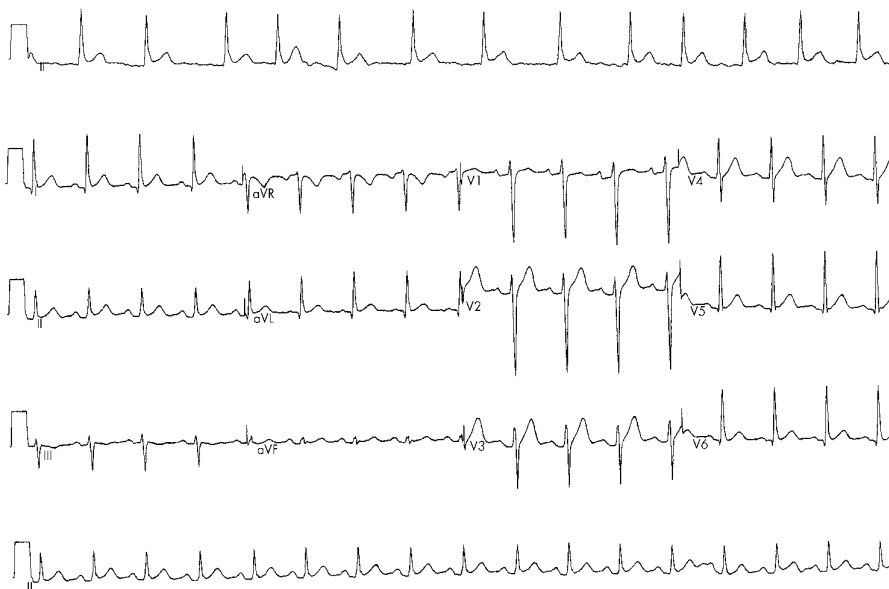A clinical diagnosis of basal skull fracture and fracture of nasal bones was made.

There was no significant past medical history particularly in relation to the cardiovascular system and he was not taking any medication. He smoked 10 cigarettes a day and consumed 10 units of alcohol per week. Radiographs of the cervical spine, chest, and pelvis were normal. An ECG showed atrial fibrillation (fig 1). A CT scan of the head revealed no abnormality. Full blood count, urea, and electrolytes were normal.

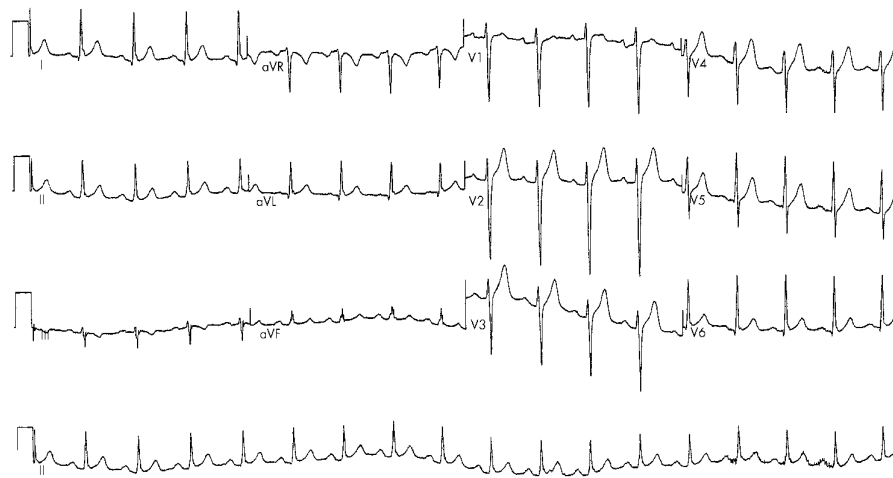He was admitted for neurological observations and during the review on following day he was able to recollect the events and remembered chasing and apprehending a suspect and escorting him to the police vehicle. He was not able to recall details of the incident subsequently and remembered being in the accident and emergency department. He was also reviewed by the medical team in view of his atrial fibrillation.



**Figure 1** ECG showing atrial fibrillation.



**Figure 2** Normal ECG after 48 hours.



**Figure 3** Normal ECG after two weeks.

The medical team suggested thyroid function tests, cholesterol, and echocardiography, all of which were normal. The atrial fibrillation was now initially attributed to head injury. Repeat ECG on the second day after admission revealed normal rhythm (fig 2). He was seen by the ENT team and found to have conductive deafness in the left ear. He was then discharged home and advised to attend the cardiology outpatient department for follow up in two weeks. On review, he was well and his ECG was normal (fig 3). The atrial fibrillation was attributed to probable trauma to the chest when he fell down on his radio despite no obvious external injury to the chest. He was discharged from the clinic with no follow up.

## DISCUSSION

Atrial fibrillation is one of the most common arrhythmias seen in accident and emergency departments. It is most commonly attributable to medical disorders and usually occurs in the elderly population.<sup>1-3</sup> It is associated with detectable organic heart diseases in about 70% of patients and may also arise secondary to severe chest trauma.<sup>4</sup> There are various reports in the literature regarding uncommon aetiologies of atrial fibrillation such as electrical injury, high protein diet, high alcohol intake, excessive exercise, electroconvulsive therapy, hypoglycemia, sigmoidoscopy, and dental extraction.<sup>5-8</sup> A patient with newly diagnosed atrial fibrillation warrants a full investigation of the aetiopathogenesis of this common arrhythmia because it may be associated with unusual pathology.<sup>9</sup> It has been reported in the literature that cardiac rhythm disorders can occur after head injury as well as after cerebral stimulation.<sup>10, 11</sup>

There are various pathophysiological mechanisms that may cause atrial fibrillation. It may be attributable to morphological changes in the heart such as acute or chronic stretch or possible changes in the cellular electrophysiology.<sup>12</sup> It may also arise resulting from disorders of autonomic tone with several studies emphasising the importance of autonomic nervous system in the initiation and perpetuation of atrial fibrillation.<sup>1</sup>

We considered the possibility of three causes for the atrial fibrillation in our patient such as paroxysmal atrial fibrillation attributable to an autonomic disorder, blunt chest trauma, and head injury with basal skull fracture.

Vagally mediated atrial fibrillation occurs more frequently in young healthy men. The age of onset is usually between 30–50 years and it occurs in subjects with normal heart where vagal influence predominates.<sup>13</sup> Atrial fibrillation usually occurs at night, and reverts to normal sinus rhythm in the morning. It is not triggered by physical exertion and emotional stress. However, the relaxation that follows physical efforts or emotional stress is frequently associated with the

onset of atrial fibrillation. This seems to be consistent with the occurrence of atrial fibrillation in our patient, but we ruled out this aetiology as the atrial fibrillation lasted for two days.

We considered the possibility that our patient might have fallen on his radio and sustained chest trauma, which would have caused the atrial fibrillation. However, there was no evidence of injury to the chest. Furthermore, the most common arrhythmias after myocardial contusion are sinus tachycardia, supraventricular tachycardia, atrial or ventricular premature contractions, conduction disorders, and non-specific ST segment and T wave changes.<sup>14</sup> Atrial fibrillation after chest trauma is very rare and reported only in elderly patients. Large studies of patients with chest trauma or sternal fractures found no cases of isolated atrial fibrillation particularly in young patients.<sup>15, 16</sup> It is theoretically possible that a heavy blow to the anterior chest, timed appropriately in the cardiac cycle, could propagate an ectopic impulse, precipitating an atrial or ventricular dysarrhythmia. However, its applicability to humans is unclear, as ectopic rhythms are distinctly less common in clinical practice.<sup>17</sup> Therefore, it is not likely that atrial fibrillation in our patient was attributable to the chest trauma.

Recent research on the pathology of head injury has focused on the changes occurring at cellular level in the first few hours after head injury. Trauma is hypothesised to produce widespread depolarisation of neurons and excessive release of excitatory neurotransmitters, which cause excitotoxic effects on postsynaptic neurons.<sup>18</sup> In experimental animal studies, Mauck *et al* noted that stimulation of the distal cut end of the right vagosympathetic trunk evoked bradycardia with hypotension, and in one instance, a brief run of atrial fibrillation. There were no other arrhythmias.<sup>11</sup> It has also been reported that sub-arachnoid haemorrhage causes a stress response with increased concentrations of plasma catecholamines and serious cardiac arrhythmias.<sup>19</sup>

Atrial fibrillation in young, healthy patients without pre-existing heart disease may account for up to one third of all cases.<sup>1</sup> It may be attributable to physiological stress of trauma such as hypovolaemia, acidosis, electrolyte imbalances, and excessive catecholamine release.<sup>17</sup> Alcohol ingestion may promote atrial fibrillation by increasing catecholamine release or by increasing the vagal outflow because of the associated nausea and vomiting.<sup>20</sup> It may also be attributable to thyrotoxicosis and pneumonia.<sup>21</sup> Idiopathic or lone atrial fibrillation may also be considered in younger patients with atrial fibrillation.<sup>22</sup>

This case illustrates that atrial fibrillation may be detected in otherwise fit young patients with an isolated head injury and no other obvious precipitating factors. It is very important that full investigations are carried out to exclude other causes before atrial fibrillation is attributed to a head injury. However,

it is not always possible to determine the exact cause of atrial fibrillation.

### Contributors

PM initiated the idea, did the literature search, and wrote the paper. GO helped in the literature search and writing the paper. MS and DAE involved in the management of the patient and helped in writing the paper. PM acts as the guarantor of the paper.

.....

### Authors' affiliations

**P Muthu, G Oduro, M Sakr, D A Esberger**, Accident and Emergency Department, University Hospital Nottingham NHS Trust, Queen's Medical Centre, Nottingham, UK

Conflicts of interest: none.

Funding: none.

Correspondence to: Mr P Muthu, Accident and Emergency Department, Derbyshire Royal Infirmary, London Road, Derby DE23 7WT, UK; palmuto@aol.com

Accepted for publication 1 March 2002

### REFERENCES

- Peters NS**. Atrial fibrillation: towards an understanding of initiation, perpetuation and specific treatment. *Heart* 1998;**80**:533-4.
- Wijffels MCEF**, Kirchhof CJHJ, Dorland R, et al. Atrial fibrillation begets atrial fibrillation. A study in awake chronically instrumented goats. *Circulation* 1995;**92**:1954-68.
- Wheeldon NM**, Tayler DJ, Anagnostou E, et al. Screening for atrial fibrillation in primary care. *Heart* 1998;**79**:50-5.
- Prete R**, Chilcott M. Blunt trauma to the heart and great vessels. *N Engl J Med* 1997;**336**:626-32.
- Shoenfield LTP**, Rupp LJ. Atrial fibrillation and electrical appliance injury. *Mil Med* 1991;**156**:254-5.
- Wood MA**, Eleenbogen KA, Stambler BS. Atrial fibrillation from liquid protein diet. *Am Heart J* 1994;**127**:1667-8.
- Venditti RC**, Shulman MS, Lutch SB. Atrial fibrillation after electroconvulsive therapy. *Anaesthesia* 1992;**47**: 914-15.
- Karjalainen J**, Kujala UM, Kaprio J, et al. Lone atrial fibrillation in vigorously exercising middle aged men: case controlled study. *BMJ* 1998; **316**:1784-5.
- Raggi P**, Vasavada BC, Parente T, et al. uncommon etiologies of atrial fibrillation. *Clin Cardiol* 1995;**19**:513-16.
- Erny P**, Pellefigue A, Chevais R. Rhythm disorders and skull trauma. (In French). *Nouvelle Presse Medicale* 1974;**3**:530.
- Mauck HP Jr**, Hockman CH, Hoff EC. ECG changes after cerebral stimulation. I. Anomalous atrioventricular excitation elicited by electrical stimulation of mesencephalic reticular formation. *Am Heart J* 1964;**68**:98-101.
- Janse MJ**. Why does atrial fibrillation occur? *Eur Heart J* 1997;**18** (suppl):C12-18.
- Coumel P**. Paroxysmal atrial fibrillation: a disorder of autonomic tone? *Eur Heart J* 1994;**15** (suppl A):9-16.
- Tenzer ML**. The spectrum of myocardial contusion. A Review. *J Trauma* 1985;**25**:620-7.
- Brooks JG**, Dunn RJ, Rogers IR. Sternal fractures: A retrospective analysis of 272 cases. *J Trauma* 1993;**35**:46-54.
- Karalis DG**, Victor MF, Davis GA, et al. The role of Echocardiography in blunt chest trauma: A transthoracic and transoesophageal echocardiographic study. *J Trauma* 1994;**36**:53-8.
- Berk WA**. ECG findings in non-penetrating chest trauma. A review. *J Emerg Med* 1987;**5**:209-15.
- Jacobson RR**. The post-concussional syndrome: physiogenesis, psychogenesis, and malingering. An integrative model. *J Psychosom Res* 1995;**39**:675-93.
- Randell T**, Tanskanen P, Scheinin M, et al. QT dispersion after subarachnoid hemorrhage. *J Neurosurg Anaesth* 1999;**11**:163-6.
- Linsay BD**, Smith JM. Electrophysiological aspects of human atrial fibrillation. *Cardiol Clin* 1996;**14**:483-505.
- Cobbe SM**, Rankin AC. Cardiac arrhythmias. In: Weatherall DJ, Ledingham JGG, Warrell DA, eds. *Oxford textbook of medicine*. Oxford: Oxford University Press, 1996:2272.
- Brand FN**, Abbott RD, Kannel WB, et al. Characteristics and prognosis of lone atrial fibrillation. *JAMA* 1985;**254**:3449-53.