

## CASE REPORTS

# Myocardial hamartoma as a cause of VF cardiac arrest in an infant

A Frampton, I Gray, S Bell

*Emerg Med J* 2005;22:590–591. doi: 10.1136/emj.2003.009951

Cardiac arrests in children are fortunately rare and the presenting cardiac rhythm is often asystole. However, ventricular fibrillation (VF) can occur and may respond favourably to defibrillation.

### CASE REPORT

A 7 month old girl was sitting in her high chair when she was witnessed by her parents to collapse suddenly at 1707 hours. They attempted cardiopulmonary resuscitation (CPR) and the ambulance crew arrived 7 minutes later, the cardiac monitor displaying VF. No defibrillation or medications were administered and she was rapidly transferred to her nearest emergency department (ED), arriving at 1723. She had been previously fit and well, and had not had respiratory difficulties prior to her arrest.

She was in cardiorespiratory arrest on arrival to the ED. She was promptly endotracheally intubated and intraosseous access obtained. Cardiac rhythm on arrival was asystole. She responded with a return of spontaneous circulation following 30 minutes of resuscitation with atropine, adrenaline, and sodium bicarbonate. She was transferred to the paediatric intensive care unit (PICU) on an adrenaline infusion.

On arrival in the PICU, further investigation, including a transthoracic echocardiogram, revealed a right atrial mass suspicious of a right atrial tumour, which was confirmed by transoesophageal echo. Following a stable night, the patient had a further VF arrest at 0700 the following morning, which responded favourably to adrenaline and a single 2 J/kg shock.

The patient was then transferred urgently to cardiac theatre and underwent resection of the tumour from the anterior leaflet of the mitral valve. The valve was replaced and a pericardial patch sited on the ventricular septum. Frozen sections taken peri-operatively confirmed a diagnosis of a myocardial hamartoma.

The infant returned to PICU paced and on inotropic support, and was discharged from PICU to the cardiac ward 2 weeks later. She was subsequently re-admitted to hospital 2 months later following a further VF arrest at home from which she was successfully resuscitated, and she was eventually discharged with an implantable defibrillator in situ. At the time of writing, she has a good neurological outcome.

### DISCUSSION

VF as a presenting rhythm in adult cardiac arrest is common. In adult patients, arrhythmias are generally secondary to acquired cardiac lesions resulting from chronic problems such as hypertension and coronary artery disease. In children, most arrhythmias result from primary cardiac lesions.<sup>1</sup> A prejudice exists that ventricular fibrillation in children is rare; however, it may be the presenting rhythm in up to 10% of paediatric cardiac arrests.<sup>2</sup>

Current recommendations in paediatric patients do not emphasise early defibrillation because VF/ventricular tachycardia (VT) is thought to be much less common in these

patients. However a review by Young *et al*<sup>2</sup> found that the survival to hospital discharge in infants and children presenting with VF/VT was of the order of 30%, compared with only 5% of patients whose initial presenting rhythm was asystole. VF has also been demonstrated to be relatively more common in infants than any other paediatric age group ( $p < 0.006$ ).<sup>1</sup> One study of over 500 000 children presenting to an ED over a period of 5 years found VF to be the third most common presenting cardiac arrhythmia of any origin in infants below the age of 1 year.<sup>1</sup> It has been suggested that a subgroup of patients (those <1 year old) that would benefit from early defibrillation can be identified.<sup>2</sup>

In a study documenting the terminal rhythms of 100 paediatric patients, 22 had VF/VT, of whom 16 deteriorated to bradycardic/asystolic arrest as the final electrical event.<sup>3</sup> Therefore, although children may appear to have VF/VT as a terminal rhythm less frequently than bradycardic/asystole, VF/VT may precede bradycardic/asystole in some, and may represent a window of opportunity for bystander CPR and defibrillation.<sup>2</sup> This was the case for our patient; her first arrest deteriorated to asystole, but prompt defibrillation during the second arrest in PICU resulted in a rapid return of cardiac output.

Current ambulance service and paramedic guidelines in our region prevent paramedic crews from defibrillating infants even if they record VF as the primary rhythm, because of the perceived rarity and possibility for misdiagnosis. However, following our patient's initial presentation and because of her high risk of recurrent VF arrest, associated with the myocardial hamartoma, it was felt that an exception should be made and this infant may now be defibrillated by paramedic crews in the event of a further VF arrest.

The current guidelines for the defibrillation of children using a monophasic defibrillator are 2, 2, and then 4 J/kg. As with adults, the higher energy is continued in the following cycles, unless a cardiac output is obtained. The use of automated defibrillators and biphasic defibrillators in children, however, remains controversial. The development of automated external defibrillators has not yet addressed the energy levels required to treat VF or VT in children or the reliability of these devices in the detection of VF and VT.<sup>4</sup> Similarly, there are no current guidelines on the safety and energy required to defibrillate small children using a biphasic defibrillator. The use of lignocaine or other anti-arrhythmics in children with resistant VF is also controversial and current guidelines are not consistent worldwide.

Myocardial hamartomas are extremely rare. In a series of 40 infants and children presenting with primary cardiac tumours described by Takach *et al*,<sup>6</sup> 16 were found to have myocardial hamartomas. Their ages ranged from 3 to 20 months, with a mean age of 1.1 years. Of the 16 patients, 15 presented with symptoms of cardiovascular collapse on admission (cardiac arrest or hypotension). All had ventricular tachycardias that were unresponsive to medical therapy. The infant described in our report presented with the

typical clinical and pathological features of a myocardial hamartoma.

The origin of these lesions is controversial and they have variously been described as histiocytoid cardiomyopathy,<sup>6-8</sup> Purkinje cell tumours,<sup>9,10</sup> arachnoidosis of heart muscle,<sup>8</sup> myocardial hamartoma,<sup>11</sup> a developmental disorder of the Purkinje cells,<sup>12</sup> and viral induced lesions.<sup>13</sup> It has been suggested that these tumours may serve as sites of abnormal or enhanced automaticity, or that they may distort the spread of excitation with possible facilitation of re-entry.<sup>10</sup> The predominant subendocardial location, frequent involvement of the conduction system, positive histochemical staining for cholinesterase, and clinical presentation with uncontrollable arrhythmias have all been cited as supportive features of a developmental disorder of the Purkinje cells.<sup>10</sup>

The lesions have been described most commonly arising in the left ventricle, although atrial lesions have previously been described, and lesions on all four heart valves,<sup>7</sup> most commonly the mitral valve.<sup>11</sup>

In some patients (such as the infant described in this case) with extensive hamartomatous infiltration of the endomyocardium, complete resection cannot be accomplished. These patients may be at risk from recurrent ventricular tachycardias. Cryoablation is a technique that has been used to extend the area that can be effectively treated in this situation. In these patients ventricular tachycardia has not recurred in late post-operative follow up, and it seems that the mitotic potential is minimal and the recurrence of further infiltration unlikely.<sup>14</sup>

#### Authors' affiliations

**A Frampton**, Paediatric Intensive Care Unit, Southampton General Hospital, Southampton, Hants, UK

**I Gray**, Emergency Department Southampton General Hospital, Southampton, Hants, UK

**S Bell**, Emergency Department, Poole General Hospital, Poole, Dorset, UK

Competing interests: none declared

Correspondence to: Dr A Frampton, Salisbury District Hospital, Odstock Road, Salisbury, Wiltshire SP2 8BJ, UK; [anneframpton2003@yahoo.co.uk](mailto:anneframpton2003@yahoo.co.uk)

Accepted for publication 19 November 2003

#### REFERENCES

- 1 **Sachetti A**, Moyer V, Baricella R, *et al*. Primary cardiac arrhythmias in children. *Pediatr Emerg Care* 1999;**15**:95-8.
- 2 **Young KD**, Seidel JS. Pediatric cardiopulmonary resuscitation: a collective review. *Ann Emerg Med* 1999;**33**:195-205.
- 3 **Walsh CK**, Krongrad E. Terminal cardiac electrical activity in pediatric patients. *Am J Cardiol* 1983;**51**:557-61.
- 4 **Nadkarni V**, Hazinski MF, Ziedman D, *et al*. Pediatric resuscitation. An advisory statement from the pediatric working group of the international liaison committee on resuscitation. *Circulation* 1997;**95**:2185-95.
- 5 **Takach TJ**, Reul GJ, Ott DA, *et al*. Primary cardiac tumours in infants and children: immediate and long-term operative results. *Ann Thorac Surg* 1996;**62**:559-64.
- 6 **Reid JD**, Hajdu SI, Attah E. Infantile cardiomyopathy: a previously unrecognised type with histiocytoid reaction. *J Paediatr* 1968;**73**:335-9.
- 7 **Saffitz JE**, Ferrans VJ, Rodriguez ER, *et al*. Histiocytoid cardiomyopathy: a cause of sudden death in apparently healthy infants. *Am J Cardiol* 1983;**52**:215-17.
- 8 **Ferrans VJ**, McAllister HA, Haese WH. Infantile cardiomyopathy with histiocytoid change in cardiac muscle cells: report of six patients. *Circulation* 1976;**53**:708-19.
- 9 **James TN**, Beeson CW, Sherman EB, *et al*. De subitaneis moribus XIII. Multifocal Purkinje cell tumours of the heart. *Circulation* 1975;**52**:333-4.
- 10 **Rossi L**, Piffer R, Turolla E, *et al*. Multifocal Purkinje-like tumor of the heart. *Chest* 1985;**87**:340-5.
- 11 **Kearney DL**, Titus JL, Hawkins EP, *et al*. Pathologic features of myocardial hamartomas causing childhood tachyarrhythmias. *Circulation* 1985;**75**:705-10.
- 12 **Zimmermann A**, Diem P, Cottier H. Congenital "histiocytoid" cardiomyopathy: evidence suggesting a developmental disorder of the Purkinje cell system of the heart. *Virchows Arch (A)* 1982;**396**:187-95.
- 13 **Silver MM**, Burns JE, Sethi RK, *et al*. Oncocytic cardiomyopathy in an infant with oncocytosis in exocrine and endocrine glands. *Human Pathol* 1980;**11**:598-605.
- 14 **Ott DA**, Garson A, Cooley DA, *et al*. Cryoablative techniques in the treatment of cardiac tachyarrhythmias. *Ann Thorac Surg* 1987;**43**:138-43.

## A case report of an unusual sternal fracture

**C Ayrik, H Cakmakci, S Yanturali, M Ozsarac, D N Ozucelik**

*Emerg Med J* 2005;**22**:591-593. doi: 10.1136/emj.2003.009993

Most sternal fractures are transverse, and a lateral chest radiograph is diagnostic. We report a case of vertical sternal fracture that was not seen on plain radiographs but was revealed using computed tomography (CT). Thoracic CT with coronal reformatted images can also demonstrate sternal fracture lines, supernumerary synchondrosis, and costosternal joint abnormalities.

Up to 8% of patients admitted with blunt chest trauma have sternal fractures,<sup>1</sup> caused primarily by anterior blunt chest trauma, usually from motor vehicle accidents when the chest strikes the steering wheel.<sup>2</sup> Mandatory seatbelt laws, now common in many parts of the world, are associated with an increased incidence of sternal fractures.<sup>3</sup>

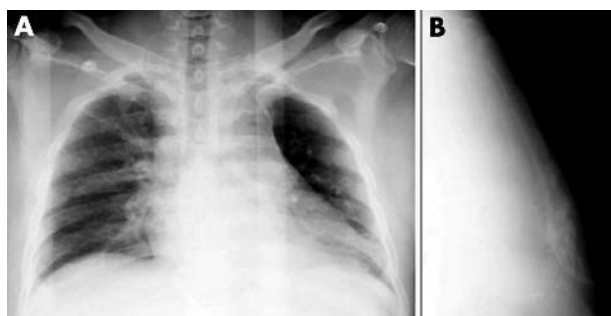
Most sternal fractures are transverse, and a lateral radiographic view is diagnostic.<sup>2</sup> These fractures are often missed radiographically because lateral plain chest radiograph is not

usually obtained during the initial trauma evaluation. Using a computed tomography (CT) scan, we diagnosed a vertical midline sternal fracture that was not visible on standard posteroanterior and lateral chest radiographs.

#### CASE REPORT

A 36 year old man who had been involved in a motor vehicle accident 2 days previously was transferred to our emergency department (ED) from a rural state hospital because of persistent chest pain. He had reported that his car had hit road barriers while he was driving at a speed of approximately 90 km/h and using a restraining seat belt. He was alert and oriented. Vital signs on presentation were in normal limits.

The patient complained of substernal chest pain that increased with inspiration, and of mild abdominal pain. On physical examination, there was a 4-cm, sutured incision on the right temporal scalp area. Pain and tenderness upon palpation of the anterior chest wall over the sternum and slight bruising from the seat belt across the sternal area were



**Figure 1** (A) Anteroposterior chest radiograph in the supine position shows widened upper mediastinum and increased cardiothoracic ratio. (B) Lateral sternum radiograph demonstrates no subtle fracture line or displacement.

observed. Abdominal examination revealed tenderness on the right upper quadrant.

Electrocardiogram showed normal sinus rhythm. Laboratory results showed haematocrit at 43.9%, white blood cell count  $8.9/\text{mm}^3$ , and normal electrolytes. Creatinine kinase (CK) and CK myocardial band values were normal. Cardiac troponin-I level was 0.011 ng/ml (normal range 0.0–1 ng/ml). Chest radiograph in the supine position demonstrated widening of the upper mediastinum and increased cardiothoracic ratio. Lateral sternum radiograph showed no subtle fracture line or displacement (fig 1). Abdominal ultrasonography and echocardiographic studies were within normal limits. Although there was no abnormality of the sternum on all the previous radiological studies, we carried out a thoracic CT scan because of the patient's intolerable chest pain. Continuous 3 mm axial sternal CT images showed a vertical mid-sternal, slightly displaced fracture. The fracture line was seen in the manubrium sterni extending to the body of the sternum. A manubriosternal synchondrosis line was seen on the right lateral side of the manubrium, and left costosternal joint widening was also detected (fig 2). No other significant thoracic injury was visible on the CT scan.

The patient was admitted to the general surgery service for observation. He had no complications during the hospital course and was discharged the following day. Sclerotic medullary bone changes caused by healing of the fracture line were detected in the follow up CT scans 1 month later. Widening of the left costosternal joint compared with the previous examination was detected. A coronal reformatted image was also showed the vertical midline fracture line more clearly (fig 3). The patient had no discomfort during the follow up examinations.

## DISCUSSION

The vast majority of sternal fractures involve the body of the sternum,<sup>4</sup> with 8% being found at the manubriosternal

junction.<sup>5</sup> The interesting point of our case was the vertical course of the fracture line, which to our knowledge has not been previously reported.

Sternal fractures cannot be visualised on frontal chest radiographs and may be relatively inconspicuous on lateral chest radiographs.<sup>6</sup> They are usually easily visible on axial or sagittal reconstructed CT scans.<sup>6</sup> In one study, diagnosis of sternal fractures was achieved by anteroposterior chest radiograph in 32.1% and lateral radiography in 64.3% of patients.<sup>7</sup> The authors diagnosed sternal fracture with CT in only one patient.<sup>7</sup> In a more recent study, lateral sternal radiographs were found to be superior to CT in diagnosis of sternal fractures.<sup>8</sup> However, in our case plain radiographs did not demonstrate the sternal fracture line; mediastinal widening was the only sign in the radiograph of the anteroposterior chest, while that of the lateral chest appeared normal.

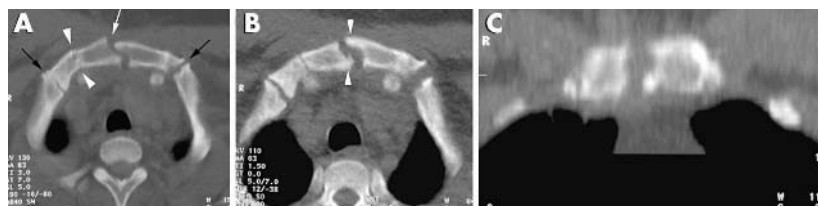Ultrasonography can be performed very quickly, is non-invasive, and may give sufficient information about sternal fractures.<sup>9</sup> In our patient, we performed a CT examination after radiography because other chest wall areas needed to be examined for trauma.

CT scanning may reveal sternal fractures, yet is less sensitive than plain radiography, as the fracture lines may be positioned between image cuts.<sup>10</sup> Suspicion of other chest injuries warrants CT scans.<sup>10</sup> In a study, eight of nine sternal fractures were diagnosed by lateral radiographs, while only six of the fractures were seen on thoracic axial CT scans; the scans misdiagnosed three sternal injuries as normal.<sup>8</sup> Sagittal or coronal reformatted CT images can show those fractures.<sup>8</sup> In our case, a slightly displaced fracture line on the sternal midline was easily seen on axial CT images. The fracture was vertically oriented, starting from the manubrium sterni and proceeding through the body of the sternum. The separated bone ends demonstrated sclerosis as sign of healing on control CT images. Coronal reformatted images demonstrated the fracture line very clearly, and manubriosternal synchondrosis was also seen on the axial images. This synchondrosis is associated with asymmetry of the developing ossification centres, which range from normal via variants to unequivocal anomalies.<sup>11</sup>

In some studies, occurrence of cardiac trauma has been shown in ~20% of sternal fractures.<sup>12–14</sup> Furthermore, sternal fractures may be associated with myocardial contusion, which is often clinically silent.<sup>15–16</sup> Thus, diagnosis of sternal fractures is of clinical importance, and CT is the method of choice as a complementary or alternative imaging technique to plain radiographs in the emergency services.<sup>10</sup>

## CONCLUSION

The use diagnostic imaging techniques for sternal fractures is a controversial subject in the literature. Plain radiographs seem to be the first choice of modality in the diagnosis of sternal fractures. We suggest thoracic CT with coronal



**Figure 2** (A) Thoracic CT axial images show a vertical midsternal, slightly displaced fracture (white arrow) on the manubrium sterni extending to the body of the sternum. Manubriosternal synchondrosis is seen on the right lateral side of the manubrium (arrowheads). Costosternal joints are also seen (black arrows). There is slight joint widening on the left costosternal joint compared with the right side. (B) Control CT scan shows sclerotic medullary bone changes caused by healing of the fracture line (arrowheads). Widening of the left costosternal joint had increased compared with the previous examination. (C) Coronal reformatted image shows the vertical midline fracture line more clearly.



reformatted images as a diagnostic technique when the suspicion of sternal fracture cannot be eliminated with conventional lateral chest radiographs.

#### Authors' affiliations

**C Ayrik, S Yanturali, M Ozsarac, D N Ozucelik**, Department of Emergency Medicine, Emergency Medicine Faculty, Dokuz Eylul University Hospital, Turkey  
**H Cakmakci**, Department of Radiology, Dokuz Eylul University Hospital, Turkey

Competing interests: none declared

Correspondence to: Dr C Ayrik, Emergency Physician, Department of Emergency Medicine, Dokuz Eylul University Medical School, 35340, Inciralti, Izmir, Turkey; cuneyt.ayrik@deu.edu.tr

Accepted for publication 12 November 2004

#### REFERENCES

- 1 **Harley DP**, Mean I. Cardiac and vascular squeal of sterna fractures. *J Trauma* 1986;**26**:553–5.
- 2 **Vukich JD**, Markovchick V. Thoracic Trauma. In: Rosen P, Barkin RM, *et al*, eds. *Emergency medicine concepts and clinical practice*, 4th ed. St. Louis: Mosby Year Book, 1998:515–16.
- 3 **Fletcher BD**, Brogdon BG. Seat-belt fractures of the spine and sternum. *JAMA* 1967;**200**:167–8.
- 4 **Brookes JG**, Dunn RJ, Rogers IR. Sternal fractures: A retrospective analysis of 272 cases. *J Trauma* 1993;**35**:46–54.
- 5 **Bu'lock FA**, Prothero A, Shaw C, *et al*. Cardiac involvement in seatbelt-related and direct sternal trauma: a prospective study and management implications. *Eur Heart J* 1994;**15**:1621–7.
- 6 **Collins J**. Chest wall trauma. *J Thorac Imaging* 2000;**15**:112–19.
- 7 **Roy-Shapira A**, Levi I, Khoda J. Sternal fractures: a red flag or a red herring. *J Trauma* 1994;**37**:59–61.
- 8 **Huggett JM**, Roszler MH. CT findings of sternal fracture. *Injury* 1998;**29**:623–6.
- 9 **Mahlfeld A**, Franke J, Mahlfeld K. Ultrasound diagnosis of sternum fractures. *Zentralbl Chir* 2001;**126**:62–4.
- 10 **Slabinski MS**. Fractures, sternal. Last updated 9 October 2002. [www.emedicine.com/emerg/topic206.htm](http://www.emedicine.com/emerg/topic206.htm).
- 11 **Kohler A**, Zimmer EA. Shoulder girdle and thorax. In: Schmidt S, Freyschmidt J, Kohler A, *et al*, eds. *Borderlands of normal and early pathologic findings in skeletal radiology*. 4th ed. New York: Thieme Medical Publishers, 1993:234–45.
- 12 **Holliday RL**. Myocardial contusion in chest trauma. *Can J Surg* 1983;**26**:43–5.
- 13 **Kumar SA**, Puri VK, Mittal VK, *et al*. Myocardial contusion following non-fatal blunt chest trauma. *J Trauma* 1983;**23**:327–31.
- 14 **Wojcik JB**, Morgan AS. Sternal fractures—the natural history. *Ann Emerg Med* 1988;**17**:912–14.
- 15 **Hamilton JR**, Dearden C, Rutherford WH. Myocardial contusion associated with fracture of the sternum: important features of the seat-belt syndrome. *Injury* 1984;**16**:155–6.
- 16 **Muwanga CL**, Cole RP, Sloan JP, *et al*. Cardiac contusion in patients wearing seat belts. *Injury* 1986;**17**:37–9.

## Eureka! A surprising appearance after aspiration of a haemopneumothorax: treat the patient not the radiograph

J J E Johnston, H D Dowd

*Emerg Med J* 2005;**22**:593–594. doi: 10.1136/emj.2003.010561

We describe the aspiration of a traumatic haemopneumothorax and an unexpected anteroposterior chest radiograph finding after the procedure. Chest aspiration is now routine emergency management for spontaneous pneumothorax. There have been no previous documented reports of this clinical scenario of radiological deterioration with clinical improvement after aspiration of a haemopneumothorax.

A 92 year old man with moderate dementia presented to the emergency department after a fall that morning in his nursing home. Radiographic investigation confirmed left sided rib fractures but no pneumothorax. He was discharged back to the nursing home. He returned 4 days later with increasing dyspnoea and continuing chest wall pain, despite paracetamol and ibuprofen analgesia. Examination findings included bilateral coarse crepitations that were worse on the left side, hyper-resonance on the left side, and decreased air entry. The anteroposterior chest radiograph was repeated and demonstrated a pneumothorax of approximately 80%<sup>1</sup> on the left side with a small haemothorax (fig 1A). There was no history of a further fall; however, the patient remained confused and noncompliant.

The medical team felt that standard treatment for traumatic pneumothorax (28 Fr drain in the fifth intercostal space) would not be well tolerated, owing to his confusion. A

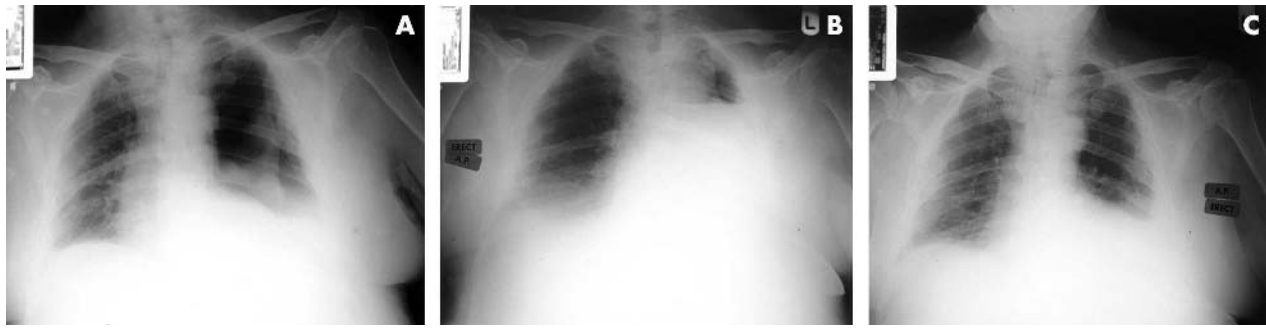
different approach was proposed and was accepted by the family. Thus, 800 ml of air were successfully aspirated from the second intercostal space, midclavicular line, using a 16 Fr cannula. This was confirmed by improvement in documented air entry and of oxygen saturation (on 15 litres of oxygen) from 93% to 96%.

The repeat radiograph demonstrated a fluid level in the left lung field extending up to the third rib posteriorly. This appearance was suggestive of a massive haemothorax (fig 1B). The patient's pulse, blood pressure, respiratory rate, and oxygen saturation remained stable, before and after this investigation.

Repeated clinical examination by three senior doctors, (two consultants and a specialist registrar) confirmed dullness and decreased air entry only at the left base. This contradicted the radiological findings that suggested mid or upper zone involvement of the haemothorax. The chest radiograph was repeated the next day (fig 1C) and showed almost complete re-expansion with a small haemothorax at the left lung base. No physiotherapy or other interventions occurred. The patient's respiratory rate and oxygen saturations remained unchanged.

#### DISCUSSION

Manual aspiration is a proven management for spontaneous pneumothorax.<sup>2–3</sup> The technique of choice for a traumatic pneumothorax is intercostal tube thoracostomy. This was not deemed feasible or safe in this confused elderly man. Outpatient management of spontaneous pneumothorax by



**Figure 1** Anteroposterior radiographs: (A) first, (B) second, (C) third.

small gauge chest drain with a flutter valve has also been used successfully.<sup>4,5</sup>

On review of the literature there have been no similar cases reported where radiological appearances have deteriorated in this manner following chest aspiration.

Possible explanations for the radiographic appearance of apparent massive haemothorax in our patient include:

- Secondary pulmonary oedema due to re-expansion.<sup>6-9</sup> This is uncommon. In our case, there were no clinical signs of pulmonary oedema.
- Failure of expansion of the lung with a raised left diaphragm following aspiration. There is one previous report in the literature of failure of expansion.<sup>10</sup> Our patient's chest was resonant to percussion, with good air entry in the middle and upper zones, after the aspiration.
- Our favoured theory: Archimedean\*. As the lung re-expanded, the serosanguinous collection in the costo-diaphragmatic gutter (from the fractured ribs) was displaced superiorly in the pleural space, giving the appearance of an acute haemothorax.

We believe this case clearly demonstrates the old adage of treating the patient and not the radiograph, and we use first principles (as all scientists should) to support our hypothesis.

#### ACKNOWLEDGEMENTS

We thank Dr S Anheuser, who examined the patient, Dr S England for his radiology opinion, and Dr J O'Connell for her suggestions for improvement.

Competing interests: there are no competing interests

\*Although many of mankind's discoveries were the result of serendipity, the first recorded example of an accidental discovery took place in third century BC Greece. The king of Syracuse, Hiero, suspected his new gold crown was not pure gold. He called on the services of the mathematician Archimedes to lay his fears to rest. Archimedes knew that to determine what the crown was made of, he would need to work out the volume of

an irregular solid. When he stepped into the bath, he noticed water spilling over the top, and suddenly realised that the volume of the spilt water was equal to his bulk, thus, if he put the crown into water, he could find its volume. If he then put a block of pure gold the same weight as the crown into water, and the volume was the same, it would prove the crown was gold, not an alloy. According to the story, Archimedes was so excited, he jumped out the bath and ran naked through the streets of Syracuse shouting "Eureka, eureka!" – "I've found it!"

Correspondence to: J J E Johnston, Accident and Emergency Department, University Hospital of North Durham, North Road, Durham DH1 5TW, UK; jeremyjohnston@doctors.org.uk

Accepted for publication 25 September 2003

#### REFERENCES

- Rhea JT, DeLuca SA, Greene RE. Determining the size of pneumothorax in the upright patient. *Radiology* 1982;**144**:733–6.
- Noppen M, Alexander P, Driesen P, et al. Manual aspiration versus chest tube drainage in first episodes primary spontaneous pneumothorax: a multicenter, prospect randomised pilot study. *Am J Respir Crit Care Med* 2002;**165**:1202–3.
- Andrivet P, Djeedaini K, Teboul JL, et al. Spontaneous pneumothorax. Comparison of thoracic drainage vs immediate or delayed needle aspiration. *Chest* 1995;**108**:335–9.
- Page A, Cossette R, Dontigny L, et al. Spontaneous pneumothorax: outpatient management with intercostals tube drainage. *Can Med Assoc J* 1975;**112**:707–9.
- Ikeda M, Yamane Y, Hagiwara N, et al. Outpatient drainage treatment for simple spontaneous pneumothorax. *Nihon Kyobu Shikkan Gakkai Zasshi* 1994;**32**:763–7.
- Tarver RD, Broderick LS, Conces DJ Jr. Reexpansion pulmonary edema. *J Thorac Imaging* 1996;**11**:198–209.
- Peyrin JC, Charlet JP, Duret J, et al. Re-expansion pulmonary edema after pneumothorax. Apropos of a review of the literature. *J Chir (Paris)* 1988;**125**:199–202.
- Barsch J, Preisler J, Wetzler K. Reexpansion edema of the lung as a complication of the treatment of spontaneous pneumothorax. *Anaesthesiol Reanim* 1989;**14**:371–4.
- Mahfood S, Hix WR, Aaron BL, et al. Reexpansion pulmonary oedema. *Ann Thorac Surg* 1988;**45**:340–5.
- Tanaka F, Ezaki H, Isobe J, et al. Four cases of spontaneous pneumothorax with no reexpansion of collapsed lung despite chest tube drainage. *Kyobu Geka* 1992;**45**:515–18.

# Renal infarction mimicking renal colic in patient with a prosthetic aortic valve

V Davutoglu, C Yildirim, N Gunay, S Turkmen

*Emerg Med J* 2005;22:595–596. doi: 10.1136/emj.2003.011692

A 31 year old man with prosthetic aortic valve replacement presented with sudden onset of colic right flank pain. Analysis of the urine revealed haematuria, and the international normalised ratio was suboptimal. The patient was misdiagnosed as having ureteral colic. On the second day, an ultrasound showed no signs of obstructive uropathy, and there was no evidence of absent function on intravenous pyelogram. Computed tomography with contrast agent was performed and revealed a right renal infarction. Renal angiography demonstrated total occlusion of the right renal artery. Fibrinolytic therapy and angioplasty were unsuccessful. To our knowledge, aortic prosthetic valve thrombus as a source of renal artery embolism mimicking renal colic has not been reported previously. This case underlines the importance of renal colic as a manifestation of renal infarction in patients with prosthetic valves and the need for a high index of suspicion of renal embolism.

with contrast agent was performed and revealed right renal infarction with perfusion only of the upper pole (fig 1A). Renal angiography demonstrated a 100% obstructing embolus in the right renal artery (fig 1B).

The patient was treated by transcatheter fibrinolytic therapy, but fibrinolysis was not successful. Renal angioplasty was attempted, but despite passing the guide wire across the total obstructive thrombus, the balloon catheter did not pass the thrombus. The vascular surgery team discounted surgery as an option because of the absence of distal arterial perfusion and assumed filling of the thrombus in the small arterioles. Renal function was not compromised. Acceptable INR was obtained by coumadine treatment, and normal function of the aortic prosthetic valve was confirmed by echocardiography.

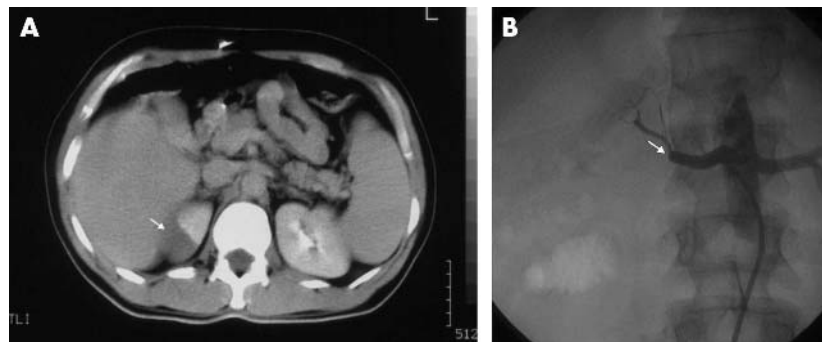
## DISCUSSION

Renal artery embolism is an infrequent but important cause of renal infarction.<sup>1</sup> Acute embolic renal infarction may manifest clinically as a pain similar to renal colic, and is often misdiagnosed as a renal calculus because of similar presenting symptoms. This leads to delay in the initiation of treatment and to increased morbidity. Few case reports exist relating cardiac emboli to acute renal infarction, and proper therapeutic intervention is not well established.<sup>1–6</sup> Urgent treatment is necessary, as ischaemia can cause irreversible kidney damage in a few hours.<sup>7</sup> The main complications are vasculorenal hypertension and renal failure. Acute vascular occlusion of the kidney must be considered in the differential diagnosis of acute flank pain. Absence of the nephrogram phase on an intravenous pyelogram should alert emergency physicians to this possible diagnosis and to the need for further investigations.<sup>7</sup> Subsequent diagnostic evaluation should begin with renal ultrasonography to rule out obstructive uropathy. If hydronephrosis is not present, follow up perfusion studies are necessary to confirm the absence of renal perfusion. Newer treatment modalities, including intraarterially injected low dose streptokinase and percutaneous transluminal angioplasty, have proved useful.<sup>8,9</sup> Greater awareness of this uncommon clinical entity

**W**e report a case of renal infarction mimicking renal colic in patient with a prosthetic aortic valve.

## CASE REPORT

A 31 year old man presented with sudden onset of severe colic right flank pain that radiated to his back. He had undergone a prosthetic aortic valve replacement (AVR) 2 years previously. Physical examination revealed tenderness to percussion of the right kidney, but otherwise normal findings. His intense flank pain was similar to features of renal colic, and subsided only with high dose and prolonged usage of narcotic analgesia. There was haematuria on urine analysis and the international normalised ratio (INR) was suboptimal (1.4). His ECG was in sinus rhythm. The patient was diagnosed as having ureteral colic and calculus. On the second day of admission, an ultrasound showed no signs of obstructive uropathy and there was no evidence of absent function on intravenous pyelogram. Computed tomography



**Figure 1** (A) Computed tomography with contrast agent revealed right renal infarction with only upper pole perfusion (arrow). (B) Selective right renal angiography. Note the total occlusion of the renal artery (arrow).

and its potential morbidity is essential to correct diagnosis and management.

To our knowledge, aortic prosthetic valve thrombus as a source of renal artery embolism mimicking renal colic has not been reported previously. This case underlines the importance of renal colic as a manifestation of renal infarction in patients with prosthetic valve and the need for a high index of suspicion of renal embolism.

#### Authors' affiliations

**V Davutoglu, S Turkmen**, Department of Cardiology, School of Medicine, University of Gaziantep, Sahinbey Medical Center, Gaziantep, Turkey

**C Yildirim, N Gunay**, Department of Emergency Medicine, School of Medicine, University of Gaziantep, Sahinbey Medical Center, Gaziantep, Turkey

Competing interests: none declared

Correspondence to: Dr V Davutoglu, Guneykent mah. 500 Evler sitesi 7, Blok No. 10, Gaziantep, Turkey; vedatdavutoglu@hotmail.com

Accepted for publication 10 November 2003

#### REFERENCES

- 1 **Gasparini M**, Hofmann R, Stoller M. Renal artery embolism: clinical features and therapeutic options. *J Urol* 1992;**147**:567–72.
- 2 **Singh G**, Dhawan R, Potteiger CE. Acute renal infarction secondary to left ventricular thrombus, masquerading as a renal calculus—a case report and brief review of literature. *Angiology* 2001;**52**:717–20.
- 3 **Hall SK**. Acute renal vascular occlusion: an uncommon mimic. *J Emerg Med* 1993;**11**:691–700.
- 4 **Carey HB**, Boltax R, Dickey KW. Bilateral renal infarction secondary to paradoxical embolism. *Am J Kidney Dis* 1999;**34**:752–5.
- 5 **Walters BL**, Grunau CF, Parman SC. Renal artery obstruction. *Ann Emerg Med* 1985;**14**:607–10.
- 6 **Goldberg G**. Renal infarction. *Ann Emerg Med* 1985;**14**:611–14.
- 7 **Lessman RK**, Johnson SF, Coburn JW, et al. Renal artery embolism: clinical features and long-term follow-up of 17 cases. *Ann Intern Med* 1978;**89**:477–82.
- 8 **Salam TA**, Lumsden AB, Martin LG. Local infusion of fibrinolytic agents for acute renal artery thromboembolism: report of ten cases. *Ann Vasc Surg* 1993;**7**:21–6.
- 9 **Boyer L**, Ravel A, Boissier A, et al. Percutaneous recanalization of recent renal artery occlusions: report of 10 cases. *Cardiovasc Intervent Radiol* 1994;**17**:258–63.

## The problem with nose bleeds

A Dai, E Jurges

*Emerg Med J* 2005;**22**:596–597

Epistaxis is common in the paediatric population and is usually minor and self limiting. This case illustrates an atypical presentation of epistaxis with hypovolaemic shock due to a dissecting false aneurysm of the internal carotid artery caused by an impalement injury to the oropharynx.

A mother and her 10 month old baby girl arrived in the paediatric accident and emergency department in the middle of the night with fresh blood soaking their nightclothes and smearing the child's face, chin, and neck. The mother described two episodes of nose bleeding in the child in the preceding few days, along with constant snuffles. Their general practitioner had prescribed some nose drops to be massaged into the nostrils the day before for the nasal congestion.

The child was found to be in hypovolaemic shock with a capillary refill time of 6 seconds. She was not in respiratory distress and not pyrexial. She responded well to 0.9% normal saline bolus fluid resuscitation (a total of 30 ml/kg), and intravenous antibiotics and ranitidine were commenced. Detailed examination later revealed only minor axillary and inguinal lymphadenopathy. There were no bruises, cutaneous haemangioma, or visceral organomegaly. All other systemic examinations, including a detailed neurological examination were unremarkable.

Her laboratory results were: haemoglobin 6.4 g/dL, white cell count  $13.2 \times 10^9/l$ , platelets  $819 \times 10^9/l$ , international normalised ratio 1.0, activated partial thromboplastin time 0.9 seconds, fibrinogen 2.3 g/L. Blood film was normal. Platelet dysfunction and other rare forms of clotting disorder were excluded, and childhood leukaemia was deemed unlikely. Her liver function tests and other biochemistry

tests were all normal. An abdominal ultrasound showed no abnormality.

The child was given a blood transfusion. An urgent ear, nose, and throat (ENT) assessment with endoscopy revealed no obvious cause for the recent bleed from the upper airway. The child was discharged 4 days later to continue with oral ranitidine at home. While at home, she was generally irritable, did not feed well, and lost some weight.

A week later, following a further episode of nose bleeding, the child was readmitted and underwent an upper gastrointestinal endoscopy, which showed no upper gastrointestinal abnormality. She started having episodes of stridor and intermittent upper airway obstruction. She then developed apnoea and was transferred to the nearest paediatric intensive care unit.

A repeat ENT assessment subsequently demonstrated a large pulsatile mass in the right parapharyngeal area extending inferiorly to the level of the pharynx, which on computed tomography scanning was found to be a large, blood filled mass extending up to the skull base. A magnetic resonance angiography went on to confirm a large dissecting aneurysm of the right internal carotid artery (ICA) that extended throughout the artery, traversing in close proximity to the nasopharynx. Cranial embolisation of the ICA proximal to the carotid artery aneurysm was successfully performed, after which the patient developed transient right sided Horner's syndrome.

On closer questioning, the mother recalled an incident prior to the onset of nose bleeds when the child was accidentally hit during play while holding the handle side of a wooden spoon in her mouth, by a force directed along the length of the spoon into the oropharynx. There was no immediate bleeding at that time, although mild nosebleeds were observed when she came down with a cold the following week. Significant bleeding only occurred after the



child's nostrils had been massaged with the prescribed nose drops.

## DISCUSSION

Impalement injuries of the soft palate and oropharynx in children are common. Injury to the ICA may occur after direct trauma to the tonsillar fossa, and may cause immediate disruption to the vessel should there be penetrating trauma, or take the more indolent form of false aneurysms with the risk of dissection should the trauma be blunt. This may occur after a fall with an object in the child's mouth, the so called "pencil point injury",<sup>1</sup> as in our patient's case.

The structures of the neck are enclosed within a deep and a superficial fascia. The fascial layers can tamponade a bleed from the large vessels but can also lead to compression of the airway through increased pressure within the neck compartments, as exemplified by our patient's later respiratory compromise.

Neurological sequelae are rare but well documented, and can occur between 3 and 60 hours following injury. They result from the initial thromboembolism following injury to the intima of the carotid artery. Mural thrombus formation, false aneurysm, or dissecting aneurysm with occlusion of the vessel and subsequent propagation of the thrombus can lead to further neurological damage.<sup>2-12</sup> A review of 131 cases over a 17 year period concluded that the majority of soft palate and oropharyngeal impalement injuries can be managed on an outpatient basis. Parental counselling and close follow up in clinic are reasonable and safe.<sup>13</sup>

Fortunately, our patient suffered only a transient neurological deficit in the form of Horner's syndrome post-embolisation. Thereafter, she had a few further nosebleeds, but only with concurrent upper respiratory tract infections. A recent endoscopic assessment showed no recurrence of her right ICA aneurysm.

## CONCLUSION

This case is interesting as there are no previously described cases of epistaxis with hypovolaemic shock as the initial presentation of a dissecting carotid aneurysm following an impalement injury to the palate. It also highlights the importance of thorough history taking and prompt investigation in atypical presentations of common complaints.

Correspondence to: Dr A Dai, Kingston Hospital, Galsworthy Road, Kingston-upon-Thames, Surrey KT2 7QB, UK; anniedai@fmail.net

Competing interests: none declared

Accepted for publication 8 December 2003

## REFERENCES

- 1 **Brandt ML**, Butler MW. Neck trauma. *Surg Infants Child Sci Princ Pract* 1997;**22**:447-54.
- 2 **Bickerstaff ER**. Aetiology of severe hemiplegia in childhood. *BMJ* 1964;**2**:82-7.
- 3 **Braudo M**. Thrombosis of the internal carotid artery in childhood after injuries in the region of the soft palate. *BMJ* 1956;**1**:665-7.
- 4 **Caldwell JA**. Post traumatic thrombosis of the internal carotid artery. *Am J Surg* 1936;**32**:522-3.
- 5 **Fairburn B**. Thrombosis of the internal carotid artery after soft palate injury. *BMJ* 1957;**2**:750-1.
- 6 **Hengerer AS**, DeGroot TR, Rivers RJ, *et al*. Internal carotid artery thrombosis following soft palate injuries: a case report and review of 16 cases. *Laryngoscope* 1984;**94**:1571-4.
- 7 **Holyst J**. Internal carotid artery occlusion due to intraoral trauma. *Acta Neurochir* 1976;**33**:325-9.
- 8 **Mains B**, Nagle M. Thrombosis of the internal carotid artery due to soft palate injury. *J Laryng Otol* 1989;**103**:796-7.
- 9 **Pimer SE**. Carotid thrombosis due to intraoral trauma. *N Engl J Med* 1966;**274**:764-7.
- 10 **Shanon E**, Cohn D, Streifler M. Penetrating injuries of the parapharyngeal space. *Arch Otol* 1972;**96**:256-9.
- 11 **Shillito J Jr**. Carotid arteritis: a rare cause of hemiplegia in children. *J Neurosurg* 1964;**21**:540-51.
- 12 **Woodhurst WB**, Robertson WD, Thompson GB. Carotid injury due to intraoral trauma: case report and review of the literature. *Neurosurgery* 1980;**6**:559-63.
- 13 **Hellmann JR**, Shott SR, Gootee MJ. Impalement injuries of the palate in children: review of 131 cases. *Int J Otorhinolaryngol* 1993;**26**:157-63.

# Tension pneumothorax and the "forbidden CXR"

R McRoberts, M McKechnie, S Leigh-Smith

*Emerg Med J* 2005;**22**:597-598. doi: 10.1136/emj.2004.018598

A case is presented of unilateral tension pneumothorax associated with flail chest and pulmonary contusions in a spontaneously ventilating patient after a fall. The tension element was not suspected until chest x ray was available, nor was immediate needle thoracocentesis performed. No morbidity resulted as a consequence. This case highlights the difficulty in deciding whether or not tension pneumothorax is the predominant cause of respiratory distress in a patient with multiple chest injuries. It provides further evidence challenging some of the doctrine on how to treat suspected tension pneumothorax.

**A** 47 year old male fell six metres onto grass from a second floor apartment. Following ambulance transport he arrived in the emergency department resuscitation room 40 minutes later.

He complained of severe right sided pleuritic chest pain and dyspnoea, worse when supine. For this reason he was transferred in a semi-erect position. He admitted heavy

consumption of alcohol that day and a past history of epilepsy treated with phenytoin.

Examination revealed: speaking in sentences although with obvious respiratory distress, respiratory rate of 28, arterial oxygen saturation 99% on 15 litres oxygen with reservoir bag, central trachea, no venous distension in the neck, right sided decreased breath sounds, right sided hyperresonance, no external marks on chest, warm well perfused peripheries, heart rate 117 beats per minute, blood pressure 134/82 mmHg, Glasgow coma score 15, and moving all four limbs.

The initial clinical impression was right sided simple pneumothorax and chest x ray (CXR) was immediately done. This showed a large right pneumothorax, marked contralateral shift of the mediastinum, hyperinflation, obvious flattening of the right hemidiaphragm (suggesting some degree of tension),<sup>1</sup> and pulmonary contusion (fig 1).

The patient's condition did not warrant immediate needle thoracocentesis and so a decision was made to proceed

**Abbreviations:** CT, computed tomography; CXR, chest x ray.



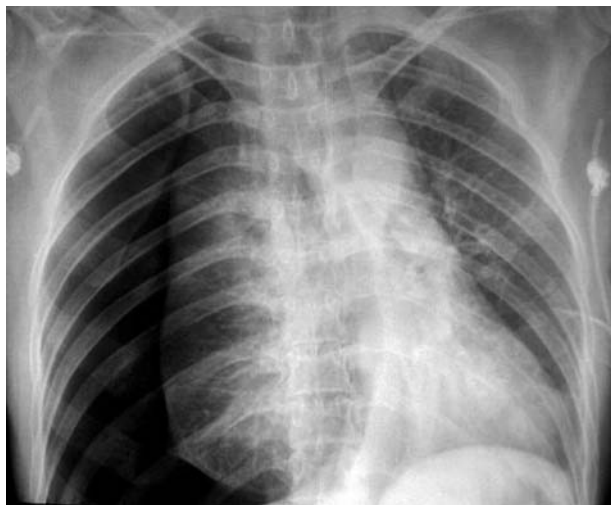

Figure 1 Initial chest x ray.

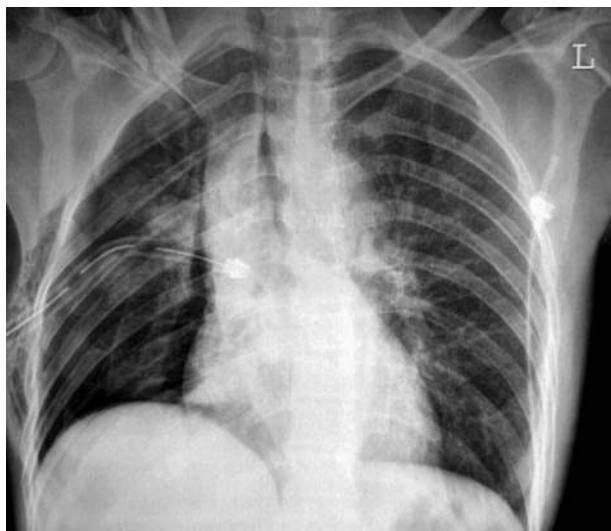


Figure 2 Post tube thoracostomy chest x ray.

straight to tube thoracostomy. This was performed in the fifth intercostal space, mid-axillary line, 30 minutes after arrival in the resuscitation room. It produced a marked expulsion of air under pressure which drained continuously during inhalation and exhalation demonstrating tension pneumothorax. A 32 French gauge intercostal drain was then inserted. Following this a repeat CXR demonstrated partial lung re-inflation and midline mediastinum with multiple right sided rib fractures, right clavicular fracture, and resolution of the hyperinflation (fig 2).

In view of worsening ventilatory status, continuing chest pain, and flail chest he underwent rapid sequence induction of anaesthesia and mechanical ventilation. A computed tomography (CT) of the chest revealed a small residual haemopneumothorax, extensive right sided pulmonary contusion, clavicular fracture, and multiple rib fractures.

Also diagnosed on CT were left pubic rami fractures, right petrous temporal bone fractures, right sided facial fractures, and a contusion of the right liver lobe.

He was extubated within 24 hours and returned home on day 8.

## DISCUSSION

Other than respiratory distress there was little to suggest tension before this patient's CXR. No hyperinflation was present<sup>2</sup> tracheal deviation/neck vein distension is rare, and hypotension is a pre-terminal sign<sup>3</sup>—none of which he had despite marked mediastinal deviation on CXR and a potentially significant time delay between injury and thoracostomy. This supports evidence that mediastinal deviation may be more marked in the presence of pulmonary contusions<sup>4</sup> and has poor correlation with the clinical picture.<sup>5</sup>

In patients with multiple thoracic injuries it can be difficult to make a definitive diagnosis as to the primary cause of respiratory distress. In our view the early CXR was appropriately ordered and contributed to the patient's care, as it confirmed the diagnosis of tension pneumothorax. The indications for needle thoracocentesis are controversial and widely debated in some fora.<sup>6,7</sup> Despite omitting needle thoracocentesis this patient did not deteriorate in the 70 minutes between injury and chest decompression with tube thoracostomy.

## CONCLUSION

The evidence base on the presenting symptoms and signs of tension pneumothorax in a spontaneously ventilating patient grows. This case further demonstrates that classical signs may be absent.<sup>3</sup> It also shows that development of a tension pneumothorax in such a patient does not invariably mean that cardiorespiratory collapse is imminent.

A recent review article recommends reconsideration of the symptoms and signs used to diagnose tension pneumothorax.<sup>3</sup>

It also suggests that if the patient's clinical condition is stable and there are no signs of pre-terminal decompensation then immediate needle thoracocentesis may not be indicated but CXR should be performed without delay. This patient's clinical presentation and progress lends support to these suggestions.

## Authors' affiliations

R McRoberts, M McKechnie, Emergency Department, The Royal Infirmary, Edinburgh, UK

S Leigh-Smith, Defence Medical Services, Gosport, UK

Funding: none.

Competing interests: none declared

Correspondence to: Mr S Leigh-Smith, c/o, Institute of Naval Medicine, Monckton House, Alverstoke, Gosport PO12 2DL, UK; simonlsuk@aol.com

Accepted for publication 17 August 2004

## REFERENCES

- 1 Teplick SK, Clark RE. Various faces of tension pneumothorax. *Postgrad Med* 1974;**56**:87–92.
- 2 Leigh-Smith S, Davies G. Tension pneumothorax—eyes may be more diagnostic than ears. *Emerg Med J* 2003;**20**:1–2.
- 3 Leigh-Smith S, Harris T. Tension pneumothorax—time for a re-think? *Emerg Med J* 2005;**22**:8–16.
- 4 Gobien RP, Reines HD, Schabel SI. Localized tension pneumothorax: unrecognized form of barotrauma in adult respiratory distress syndrome. *Radiology* 1982;**142**:15–19.
- 5 Clark S. *Is mediastinal shift always an emergency?* Melbourne: ACEM Winter symposium, 2003.
- 6 Trauma.org. Needle decompression—discussion forum. Available at <http://www.trauma.org/archives/ncdeco.html> (accessed April 2004).
- 7 Trauma.org. Needle thoracostomy—discussion forum. Available at <http://www.trauma.org/archives/needlethoracostomy.html> (accessed April 2004).

# Troponin for prediction of cardiovascular collapse in acute colchicine overdose

C van Heyningen, I D Watson

*Emerg Med J* 2005;22:599–600. doi: 10.1136/emj.2002.004036

The use of colchicine, a treatment for acute gout and familial Mediterranean fever, is limited by its toxicity. A relatively low dose of colchicine may be fatal. After a colchicine overdose, monitoring should include 6–12 hourly serum troponin measurements. A rising troponin level predicts cardiovascular collapse and is an indication for more intensive management.

The use of colchicine, a treatment for acute gout and familial Mediterranean fever, is limited by its toxicity. The degree of colchicine toxicity cannot be reliably predicted from the stated dose ingested. Fatal poisoning has been reported after as little as 7 mg ingested over 4 days,<sup>1</sup> while other patients have survived ingestions of more than 60 mg.<sup>2</sup> The first stage of colchicine poisoning is marked by gastrointestinal symptoms, with a second stage developing after about 24 hours, involving multisystem organ failure in severe cases.<sup>3</sup> An important cause of morbidity and mortality is cardiovascular collapse, which may be due to hypovolaemia, electrolyte disturbances, cardiac dysrhythmias, and a possible direct toxic effect on cardiac myocytes.

In this complex situation, the prediction of cardiac damage is potentially useful for patient management. We describe a case of fatal acute colchicine poisoning and present our view on the predictability of outcome.

## CASE HISTORY

A 21-year-old woman presented to the hospital emergency department after ingesting 25 mg of colchicine with alcohol. She was obese, with body mass index of 32 kg/m<sup>2</sup>, and the dose of colchicine was calculated to be 0.25 mg/kg. She was alert and oriented, and was initially treated with oral charcoal. On the second day, she developed pyrexia, nausea, and vomiting. Investigations showed neutrophil leucocytosis and renal impairment. She became breathless and developed diarrhoea, which was treated with fluid replacement. Electrocardiography 32 hours after the overdose revealed prolonged ST segments in leads I, II, aVR, and V<sub>4</sub> to V<sub>6</sub>, with ST depression in lead V<sub>4</sub>. On the third day, she had a cardiac arrest and after resuscitation was treated with haemofiltration, even though there is no evidence that this enhances colchicine elimination. Colchicine and desmethylcolchicine were not detected in blood samples collected after the cardiac arrest. Our gas chromatography assay for this drug has a lower limit of detection of 5 µg/l, and concentrations below this limit have been reported at 24 hours after fatal ingestion.<sup>4</sup> On the fourth day, poor left ventricular function was demonstrated by echocardiography. The patient developed a purpuric rash, conjunctival haemorrhages and cardiogenic shock, which progressed to bradycardia and asystole at 84 hours after admission. Results of selected laboratory investigations over 50 hours before cardiac arrest are shown in table 1. Cardiac troponin I (Tn I) was measured by immunoassay using the DPC Immulite 2000 analyser

**Table 1** Results of laboratory investigations

Test	Time after admission (hours)			
	6	24	37	50
Serum creatinine (µmol/l)	82	–	183	254
Creatine kinase (U/l)	–	502	1154	55090
Aspartate transaminase (U/l)	48	221	384	432
Troponin I (µg/l)	<0.2	1.7	3.9	5.9

Reference ranges: serum creatinine <120 µmol/l; creatine kinase <175 U/l; aspartate transaminase 13–42 U/l; troponin I <1.0 µg/l.

(reference range <1.0 µg/l). This method is a solid phase, two site, chemiluminescence enzyme immunoassay using mouse and goat antibodies against cardiac Tn I.

The cause of death was determined at post mortem examination to be multiple organ failure. The lungs showed multiple, bilateral foci of bronchopneumonia and features of diffuse alveolar damage. The kidneys demonstrated acute tubular necrosis, but no haemosiderin rich casts were identified in the tubules to substantiate rhabdomyolysis as a cause of tubular necrosis. The liver sinusoids were congested and there was diffuse macrovesicular fatty change in hepatocytes. There was very minimal coronary artery atherosclerosis and no evidence of coronary artery thrombosis. The myocardium showed foci of contraction band necrosis and pale, anuclear myocytes consistent with ischaemia.

## DISCUSSION

This case report illustrates the typical features of severe colchicine poisoning even though the amount ingested (0.25 mg/kg) was relatively small. The enzymes creatine kinase and aspartate transaminase rise at the same time as troponin levels, but these enzyme activities demonstrate multisystem complications and hence cannot be used to assess myocardial damage. A raised serum creatine kinase may be due to colchicine induced skeletal muscle rhabdomyolysis.<sup>5</sup> The highly specific marker of myocardial damage, troponin I, shows increasing concentrations over 2 days before cardiac arrest and hence may be used to predict the increasing risk of cardiogenic shock as a result of myocardial damage. This prognostic test, we believe, provides evidence for vigorous intervention. Mitigation of colchicine toxicity is difficult and currently there are no specific treatments commercially available in the UK.<sup>6</sup> Colchicine specific Fab fragments have been successfully used in the treatment of a woman who had ingested 60 mg of colchicine.<sup>2</sup> The report findings suggest that the drug can be removed from peripheral sites and redistributed into the extracellular space. No adverse effects could be ascribed to the use of the Fab fragments. Haemodynamic function might thus be improved by reduced binding of the drug to microtubules

**Abbreviations:** Tn I, troponin I

in myocardial cells. Granulocyte colony stimulating factor offers an effective method of treating pancytopenia and preventing septicaemia in those patients who survive the initial phase of poisoning.<sup>7</sup>

## CONCLUSION

One previous case has been reported using troponin I as a marker of cardiac toxicity in colchicine overdose.<sup>8</sup> This report similarly indicates that early Tn I testing may alert the clinician to impending cardiovascular collapse. We believe that vigorous intervention to avoid cardiovascular collapse in such cases should be informed through 12 hourly serial measurements of serum troponins.

## ACKNOWLEDGEMENTS

The post mortem examination was performed by Dr K Gumparthy and drug estimations by Mr F J Tames.

## Authors' affiliations

C van Heyningen, I D Watson, University Hospital Aintree, Liverpool, L9 7AL

Competing interests: none declared

Correspondence to: Dr C van Heyningen, University Hospital Aintree, Liverpool L9 7AL, UK; charles.vanheyningen@aht.nwest.nhs.uk

Accepted for publication 11 December 2003

## REFERENCES

- 1 MacLeod JG, Phillips L. Hypersensitivity to colchicine. *Ann Rheum Dis* 1947;**6**:224–9.
- 2 Baud FJ, Sabouraud A, Vicaute E, et al. Treatment of severe colchicine overdose with colchicine-specific Fab fragments. *N Engl J Med* 1995;**332**:642–5.
- 3 Milne ST, Meek PD. Fatal colchicine overdose: report of a case and review of the literature. *Am J Emerg Med* 1998;**16**:603–8.
- 4 Dehon B, Chagnon JL, Vinner E, et al. Colchicine poisoning: report of a fatal case with body fluid and post-mortem tissue analysis by high-performance liquid chromatography. *Biomed Chromatogr* 1999;**13**:235–8.
- 5 Chattopadhyay I, Shetty H G M, Routledge PA, Jeffery J. Colchicine induced rhabdomyolysis. *Postgrad Med J* 2001;**77**:191–2.
- 6 Maxwell MJ, Mutha P, Priddy PE. Accidental colchicine overdose. A case report and literature review. *Emerg Med J* 2002;**19**:265–7.
- 7 Critchley JA, Critchley LA, Yeung EA, et al. Granulocyte-colony stimulating factor in the treatment of colchicine poisoning. *Hum Exp Toxicol* 1997;**16**:229–32.
- 8 Mullins ME, Robertson DG, Norton RL. Troponin I as a marker of cardiac toxicity in acute colchicine overdose. *Am J Emerg Med* 2000;**18**:734–4.

# Long QT syndrome presenting as epileptic seizures in an adult

D P J Hunt, K Tang

*Emerg Med J* 2005;**22**:600–601. doi: 10.1136/emj.2003.007997

A 50 year old woman with a previous diagnosis of epilepsy presented to the emergency department with a generalised seizure. Her admission ECG showed QT prolongation secondary to bradycardia and a subsequent seizure in the department demonstrated that these events were secondary to cerebral hypoperfusion during episodes of torsades de pointes. This case illustrates how long QT syndrome can masquerade convincingly as epilepsy, delaying treatment and exposing the patient to a high risk of sudden cardiac death. Careful ECG analysis is recommended for all patients presenting with seizures.

A 50 year old woman presented to the emergency department with a seizure. Over the past 18 months she had experienced five similar episodes. On each occasion she collapsed with loss of consciousness, and then subsequently developed rigid flexor posturing with loss of urinary continence. Typically she would regain consciousness within several minutes with no residual neurological deficit. A diagnosis of epilepsy was made by her general practitioner on the basis of this history and a normal computed tomogram (CT) of the head, and she was treated with sodium valproate. She and her family were otherwise fit and well.

On admission the only abnormality on physical examination was bradycardia of 40 beats per minute. Routine

admission blood tests including serum potassium and magnesium were normal and a chest x ray was unremarkable.

Her admission electrocardiogram (ECG) was markedly abnormal (fig 1A). It showed complete heart block with a

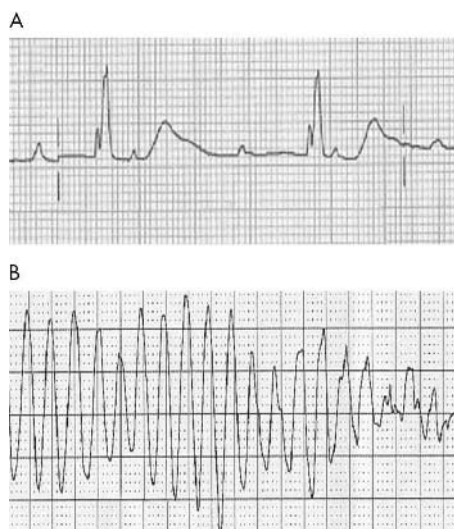


Figure 1 (A) Admission ECG (lead V3) and (B) torsades de pointes.

ventricular rate of 40 beats per minute. The escape rhythm showed a partial right bundle branch block pattern. Most significantly, the corrected QT interval was highly prolonged at 0.64 seconds with broad, tall T waves.

The patient was admitted to the coronary care unit for continuous monitoring and temporary pacing. While the procedure was being explained to the patient, she developed a VT arrest which was terminated by DC cardioversion. She lost consciousness at the onset of the arrest and subsequently developed a seizure characterised by rigid flexor posturing and loss of urinary continence. Her rhythm during the episode shows the classic features of torsades de pointes, with a short-long-short initiation sequence and a polymorphic ventricular tachycardia (fig 1B). Her seizures were secondary to cerebral hypoxia during episodes of torsades.

She subsequently underwent successful temporary pacing and was transferred to a tertiary cardiology centre where a DDD pacemaker was inserted which corrected the bradycardia and secondary QT prolongation. Further investigations to elucidate the cause of her complete heart block were negative (echocardiography, *Borrelia* serology, sarcoid and infiltrative disorder screen). She has since experienced no further syncopal episodes. Her daughters were contacted and their ECGs show no QT prolongation.

## DISCUSSION

The long QT syndrome represents a variety of congenital and acquired disorders of ventricular repolarisation characterised by a prolonged corrected QT interval (Bazett's formula:  $QTc = QT/\sqrt{RR}$ ) on the electrocardiogram.<sup>1</sup> It is associated with a life threatening polymorphic ventricular tachycardia known as torsades de pointes (twisting of points).<sup>2</sup> The QT interval on the ECG reflects the length of ventricular action potential and an interval over 0.44 seconds should be considered prolonged.<sup>3-4</sup> A common presentation is syncope or sudden cardiac death.<sup>3</sup> Initial presentation with epileptic seizures is less well recognised, especially in adults. The commonest causes of acquired QT prolongation are drugs, hypokalaemia, and hypomagnesaemia. Bradycardia is a rare but recognised cause of QT prolongation. Treatment is directed at the underlying cause.

Our case illustrates how long QT syndrome can masquerade convincingly as epilepsy, delaying both diagnosis and treatment, thereby exposing the patient to a high risk of sudden cardiac death. It is therefore important that long QT syndrome should feature in the differential diagnosis of

seizures, particularly if there are atypical features or if there is no response to antiepileptic medications.<sup>5-6</sup>

A thorough history is important in the identification of these patients. There is often a precipitating factor for the seizures, such as loud noises or an adrenergic surge, and typically consciousness is lost for a brief period of time before seizures begin, as in our patient.<sup>3-7</sup> A family history of sudden unexplained death or deafness also suggests congenital long QT syndrome, and recent introduction of new drugs, in particular antiarrhythmics may be an acquired cause of QT prolongation. Careful analysis of the 12-lead ECG at the time of admission is important to identify these patients. The ECG changes may be subtle and prolongation of the QT interval can be easily overlooked.

Our case also demonstrates the need for caution when explaining potentially frightening diagnoses and procedures to patients with QT prolongation, since torsades de pointes can be precipitated by adrenergic surges, especially in patients with the congenital form of the disease.<sup>3-5,8</sup>  $\beta$  Blockade may reduce this risk.<sup>3</sup>

## Authors' affiliations

D P J Hunt, The Hammersmith Hospital NHS Trust, London, UK  
K Tang, Colchester General Hospital, Colchester, UK

Competing interests: none declared

Correspondence to: Dr D P J Hunt, 78 Queen Edith's Way, Cambridge CB1 8PW, UK; david\_hunt200@hotmail.com

Accepted for publication 11 December 2003

## REFERENCES

- 1 Bazett HC. An analysis of the time relations of the electrocardiogram. *Heart* 1918;**7**:353-70.
- 2 Dessertene F. La tachycardia ventricularire a deux foyers opposes variables. *Arch Mal Coeur Vaiss* 1966;**59**:263-72.
- 3 Al-Khatib, LaPointe NM, Kramer JM, et al. What clinicians should know about the QT interval. *JAMA* 2003;**289**:2120-7.
- 4 Tan HL, Hou CJ, Lauer MR, et al. Electrophysiologic mechanisms of the long QT interval syndromes and Torsades de pointes. *Ann Intern Med* 1995;**122**:701-14.
- 5 Garson A, Dick M, Fournier A. The Long QT syndrome in children. *Circulation* 1993;**87**:1866.
- 6 Pacia SV, Devinsky O, Luciano DJ, et al. The prolonged QT syndrome presenting as epilepsy: a report of two cases and literature review. *Neurology* 1994;**44**:1408-10.
- 7 Singh B, Shahwan SA, Habbab MA, et al. Idiopathic long QT syndrome: asking the right question. *Lancet* 1993;**341**:741-2.
- 8 Towbin JA, Vatta M. Molecular biology and the prolonged QT syndromes. *Am J Med* 2001;**110**:385-98.



# C-reactive protein: a valuable acute investigation. A case of pneumococcal meningitis presenting as ankle pain

J S Huntley, M B Kelly

*Emerg Med J* 2005;22:602–603. doi: 10.1136/emj.2003.012146

A case is presented in which the decision to admit and treat an adult with musculoskeletal pain and pyrexia was based on her markedly raised c-reactive protein (CRP). At the time of admission she was afebrile and the CRP was the only haematological investigation that was out of the normal range. She subsequently became precipitously septic with pneumococcal bacteraemia and meningitis. The CRP is an important investigation for emergency departments.

## CASE HISTORY

A 53 year old woman presented to the emergency department with a one day history of “flu-like” malaise, intermittent fever, and atraumatic left ankle pain, which, though poorly localised, was of increasing severity. Her medical history included episodic migraine and hyperthyroidism treated with radioiodine rendering her hypothyroid (well controlled with supplementation). On examination she was pyrexial (38.5°C) but normocardic. She had a full range of pain-free movement at the ankle joint, which was not swollen, tender, or warm, and showed no evidence of an effusion. However, she was only able to weight bear with discomfort. Ankle radiographs showed no abnormality. Blood tests taken were full blood count (FBC), urate, and C-reactive protein (CRP). She was allowed home with a diagnosis of viral infection and “arthralgia”, and was given an appointment for review with results (CRP processing was not available overnight) at the fracture clinic the subsequent morning.

At review, the CRP of 123 mg.l<sup>-1</sup> and leucocyte count of 11.4 (neutrophils 9.8) × 10<sup>9</sup>.l<sup>-1</sup> was her only abnormal results. Septic arthritis was considered but clinically there was no effusion and an aspiration was dry. She had a full active and passive range of movement at the ankle, with discomfort only when stressed at the extreme of dorsiflexion. There was no tenderness on bony palpation. A reactive arthritis was not thought likely because of the contemporaneous nature of her general symptoms and musculoskeletal pain. She was tender over the tendons of tibialis anterior and extensor hallucis longus. A provisional diagnosis of inflammatory/infective tendonitis/synovitis was made. Though she was afebrile and only slightly tachycardic (PR 96 bpm; BP 120/75 mm Hg), because of her markedly raised CRP she was admitted for further investigations, close observation, and antibiotic treatment. At this time, repeated bloods showed white blood count (WBC 9.9 × 10<sup>9</sup>.l<sup>-1</sup>), glucose, urea, electrolytes, and urate within reference ranges. Urinalysis was also negative.

After blood cultures, she was started on “best guess” intravenous antibiotics (flucloxacillin 1 g and penicillin G 1.2 g). Two hours later, she became septic with two rigors, a spiking pyrexia (39.5°C), and tachycardia (PR 104 bpm; BP initially 110/70 mm Hg). She also complained of a throbbing headache with photophobia. Kernig’s sign was positive. She was not tachypnoeic, had no adverse respiratory signs, and oxygen saturations were 99% on air. Her Glasgow Coma Scale (GCS) remained 15 and there were no focal neurological

signs and no cutaneous rash. Plantar reflexes were bilaterally down-going and fundoscopy was normal. A coagulation screen was normal.

Her blood pressure then dropped to 90/60 mm Hg (15 minutes after previous reading), but responded to fluid resuscitation. A chest radiograph and urgent head CT (result available at 1 hour post onset of sepsis) showed no abnormality. A subsequent lumbar puncture of clear colourless fluid showed red blood count 200 mm<sup>-3</sup>, WBC 312 mm<sup>-3</sup> (90% neutrophils), glucose 2.7 mmol.l<sup>-1</sup>, protein 2125 mg.l<sup>-1</sup>, and was negative for meningococcal, *Haemophilus influenzae* and pneumococcal antigens (delayed culture negative). She was transferred to the care of the infectious diseases team.

Blood cultures yielded chains of Gram positive cocci and were pneumococcal antigen-positive at 15 hours. She was treated with 14 days of intravenous cefotaxime (2 g qds) followed by oral amoxicillin for one week. A throat swab taken previously showed “normal commensals only”. At discharge (day 20 post admission) her CRP was <10 mg.l<sup>-1</sup>. She made a complete recovery. Six weeks after discharge, a repeat ankle film showed no abnormality.

## DISCUSSION

*Streptococcus pneumoniae* is an important pathogen, with bacteraemia carrying a mortality of 16–24%.<sup>1,2</sup> A previous report in Scotland<sup>1</sup> identified the primary site of pneumococcal sepsis being the lungs in 76%, the meninges in 6%, joints in 2%, and soft tissues only 1%. However, in 15% no site was identified and most patients (62%) had recognisable predisposing factors.<sup>1</sup> A high rate of second site infection—for example, meningitis, endocarditis—has been documented for pneumococcal arthritis.<sup>3</sup> We think it most likely that our patient—who did not have any predisposing factors—had pneumococcal bacteraemia with meningitis and a soft tissue focus. It is impossible to establish the primacy of these sites. An analysis of adult cases of bacterial meningitis in Munich showed a complication rate of 50%, and a mortality of 18.6%, that rose to 33.3% (10/30) for pneumococcal cases.<sup>4</sup>

CRP, so called because of its reactivity with phosphocholine residues of C-polysaccharide of *Streptococcus pneumoniae*,<sup>5</sup> is a pentameric acute phase protein synthesised by hepatocytes.<sup>6,7</sup> Expression is predominantly regulated at the level of transcription, with interleukin-6 being the predominant inducer. In health, levels rarely rise above 10 mg.l<sup>-1</sup>. It is generally ascribed a limited role in the diagnosis of adult disease in the emergency department. The review of Clyne and Olshaker (1999)<sup>8</sup> concludes that “A single CRP value should not factor into the decision to treat...”. In our case, however, the raised CRP indicated a severe underlying condition, even though the condition itself had not been diagnosed. At the time of admission, she was afebrile with a FBC conforming to the normal range. When she became precipitously septic, it was fortuitous that she was already a hospital inpatient. She was treated rapidly and made a

**Abbreviations:** CRP, C-reactive protein; FBC, full blood count; GCS, Glasgow Coma Scale; WBC, white blood count

complete recovery from a condition associated with high mortality and morbidity.

In summary, we have reported a case of pneumococcal bacteraemia and meningitis presenting as ankle pain with fever, in which the CRP was the sole investigation mandating her admission. There are two lessons: (1) localised musculo-skeletal pain with pyrexia should prompt thought of a soft tissue infection if septic arthritis and osteomyelitis are held to be unlikely, and (2) in cases of diagnostic uncertainty, the CRP can be a useful one off investigation in the emergency department. We therefore believe that acute hospitals should have access to CRP processing and results services 24 hours a day, seven days a week.

#### ACKNOWLEDGEMENTS

We gratefully acknowledge the encouragement and advice of Mr IGC Weir, Consultant Orthopaedic Surgeon (Queen Margaret Hospital, Whitefield Road, Fife), in writing this case report concerning his patient.

#### Authors' affiliations

J S Huntley, M B Kelly, Musculoskeletal Research Unit, University of Edinburgh, Teviot Place, Edinburgh EH8 9AG

Competing interests: none declared

Correspondence to: Dr J S Huntley, Musculoskeletal Research Unit, University of Edinburgh, Teviot Place, Edinburgh, EH8 9AG; jimhuntley@doctors.org.uk

Accepted for publication 5 January 2004

#### REFERENCES

- 1 McKenzie H, Reid N, Dijkhuizen RS. Clinical and microbiological epidemiology of *Streptococcus pneumoniae* bacteraemia. *J Med Microbiol* 2000;**49**:361–6.
- 2 Kuikka A, Syrjänen J, Renkonen O-V, et al. Pneumococcal bacteraemia during a recent decade. *J Infect* 1992;**24**:157–68.
- 3 Kauffman CA, Watanakunakorn C, Phair JP. Pneumococcal arthritis. *J Rheumatol* 1976;**3**:409–19.
- 4 Pfister HW, Feiden W, Einhaupl KM. Spectrum of complications during bacterial meningitis in adults. Results of a prospective clinical study. *Arch Neurol* 1993;**50**:575–81.
- 5 Tillet WS, Francis T. Serological reactions in pneumonia with a non-protein somatic fraction of pneumococcus. *J Exp Med* 1930;**52**:561–71.
- 6 Volanakis JE. Human C-reactive protein: expression, structure, and function. *Mol Immunol* 2001;**38**:189–97.
- 7 Pepys MB, Hirschfield GM. C-reactive protein: a critical update. *J Clin Invest* 2003;**111**:1805–12.
- 8 Clyne B, Olshaker JS. The C-reactive protein. *J Emerg Med* 1999;**17**:1019–25.

## Misdiagnosis of myocardial infarction by troponin I following minor blunt chest trauma

A Khavandi, N P Jenkins, H S Lee, M Gavalas

*Emerg Med J* 2005;**22**:603–604. doi: 10.1136/emj.2003.012930

The American College of Cardiology and European Society of Cardiology have redefined myocardial infarction as a rise of troponin above the laboratory reference range (99<sup>th</sup> percentile of a reference control group), in conjunction with typically ischaemic symptoms, a history of recent coronary intervention, the development of Q waves or dynamic ST-segment changes.<sup>1</sup>

Troponin concentrations are highly specific for myocardial necrosis, but disease states other than myocardial infarction can cause elevated plasma levels (table 1).<sup>2</sup> It is our impression that there has been widespread misinterpretation of the new definition, and troponin concentrations are frequently assumed to reflect myocardial infarction without corroborative evidence from the patient's history or electrocardiogram (ECG). We present an illustrative case of elevated troponin concentrations following minor chest trauma.

#### CASE REPORT

A fit 29 year old man presented to the ED with chest discomfort. He was the goalkeeper in a football match the previous day and was struck forcibly in the chest with a football. He continued the rest of the match without difficulty but subsequently developed diffuse non-radiating central chest discomfort and malaise persisting for several hours.

His past medical history was unremarkable. He used no regular medications or illicit drugs. He smoked 20 cigarettes per day but had no other risk factors for ischaemic heart disease.

On examination, there were no signs of external injury to his praecordium. Cardiovascular examination was normal with a blood pressure of 137/72. His full blood count, renal

function, ECG, and chest x ray were normal with a total cholesterol of 3.79 mmol/l. Troponin I was measured 12 hours after the onset of his symptoms, and was elevated at 5.18 µg/L (reference range 0.00–0.03 µg/L). CK measured from admission was elevated at 1018 IU/L with a CK-MB fraction of 6.4%, and repeat troponin I the following day was also elevated at 4.40 µg/L. Serial ECGs were normal but a diagnosis of myocardial infarction was made and he was referred to a tertiary referral centre for future management.

On transfer, his echocardiography revealed normal valvular and ventricular function, with no pericardial effusion or abnormalities of the aortic root. He completed 9 minutes of exercise in standard Bruce Protocol without symptoms or ECG changes. Coronary angiography revealed normal coronary arteries and left ventricular function. A diagnosis of myocardial contusion was made, and after considerable difficulty resulting from the anxiety provoked by his earlier diagnosis of myocardial infarction, he was reassured and discharged.

#### DISCUSSION

Measurement of plasma troponin has been a major advance in the management of acute coronary syndromes, identifying a high risk subset of patients likely to benefit from an early invasive treatment strategy.<sup>3,4</sup> These patients are now classified as having had myocardial infarctions, though many have only small areas of myocardial necrosis. The epidemiological and societal consequences of this new definition are as yet unclear. More worrying is the observed trend to use troponin measurement as the sole criterion for the diagnosis of myocardial infarction.

**Table 1** Elevation of cardiac troponins in patients without overt ischaemic heart disease<sup>2</sup>

Cardiac trauma (including contusion, ablation, pacing, firing, cardioversion, cardiac surgery)
Congestive heart failure
Hypertension
Hypotension often with arrhythmias
Postoperative non-cardiac surgery
Chronic renal failure
Critically ill patients, especially with diabetes
Hypothyroid
Myocarditis
Pulmonary embolus
Sepsis
Amyloidosis
Cardiotoxicity from cancer therapy

Myocardial infarction is the most likely cause of elevated plasma troponin in the acute setting, but levels can be raised in other conditions (table 1).<sup>2</sup> Myocardial trauma should be considered in patients with a history of blunt chest injury and cardiac troponins have been proposed as a means to diagnose and measure degrees of myocardial contusion.<sup>5-7</sup> In this patient, his young age, history, lack of risk factors, and normal ECGs would suggest a low likelihood of myocardial infarction. Importantly an elevated troponin level alone was insufficient to make the diagnosis of myocardial infarction.

The diagnosis of myocardial infarction has major psychological and socioeconomic implications. Elevated troponin

without a typical history or ECG change should prompt consideration of alternative diagnoses.

**Authors' affiliations**

**A Khavandi, N P Jenkins, H S Lee**, University Department of Cardiology, Regional Cardiac Centre, Wythenshawe Hospital, Manchester, UK  
**M Gavalas**, Accident and Emergency Department, University College Hospital, London, UK

Correspondence to: Dr H S Lee, Wythenshawe Hospital, Southmoor Road, Wythenshawe, Manchester M23 9LT, UK; Khavandi@hotmail.com

Accepted for publication 13 February 2004

**REFERENCE**

- 1 **Alpert JS**, Thygesen K, Antman E, et al. Myocardial infarction redefined—a consensus document of The Joint European Society of Cardiology/American College of Cardiology Committee for the redefinition of myocardial infarction. *J Am Coll Cardiol* 2000;**36**(3):959–69.
- 2 **Panteghini M**. Acute coronary syndrome: biochemical strategies in the troponin era. *Chest* 2002;**122**(4):1428–35.
- 3 **Antman EM**, Tanasijevic MJ, Thompson B, et al. Cardiac-specific Troponin I levels predict the risk of mortality in patients with acute coronary syndromes. *N Engl J Med* 1996;**335**:1342–9.
- 4 **Lindahl B**, Venge P, Wallentin L, et al. Relation between Troponin T and the risk of subsequent cardiac events in unstable coronary artery disease. *Circulation* 1996;**93**:1651–7.
- 5 **Adams JE 3rd**, Bodor GS, Davila-Roman VG, et al. ardiac troponin I. A marker with high specificity for cardiac injury. *Circulation* 1993;**88**(1):101–6.
- 6 **Bertinchant JP**, Polge A, Mohty D, et al. Evaluation of incidence, clinical significance, and prognostic value of circulating cardiac troponin I and T elevation in hemodynamically stable patients with suspected myocardial contusion after blunt chest trauma. *J Trauma* 2000;**48**(5):924–31.
- 7 **Ru Dusky BM**. Cardiac troponins in the diagnosis of myocardial contusion: an emerging controversy. *Chest* 1997;**112**(3):858–60.

## Brugada syndrome: syncope in the younger patient and the risk of sudden cardiac death

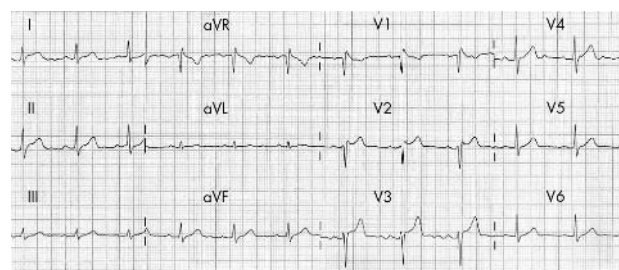
**A T D Mills, S Dasan, A Wan**

*Emerg Med J* 2005;**22**:604–606. doi: 10.1136/emj.2003.009845

**A** 40 year old man presented to the emergency department after losing consciousness while driving his car. He had felt nauseous and light headed before managing to slow down and stop. A witness who stopped to help found him slumped unconscious over the steering wheel, and he regained consciousness a few seconds later. On arrival in hospital he was fully alert although he felt light headed and had mild chest discomfort.

He had been investigated previously for episodes of dyspnoea. Lung function tests, exercise tolerance tests, and 24 hour Holter monitoring had been unremarkable though ST segment elevation had been noted on his electrocardiogram (ECG). In the emergency department, physical examination was unremarkable though his resting ECG again showed ST segment elevation in the anterior precordial leads (fig 1). These changes were identical to those seen in the ECGs performed three years previously which had been faxed to the emergency department.

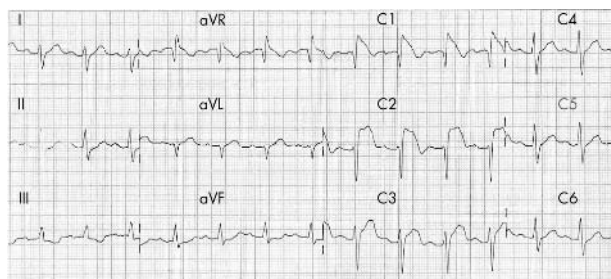
A provisional diagnosis of vasovagal syncope or syncope secondary to an arrhythmia was made and he was admitted for further investigation. ECGs performed over the following 24 hours showed no change in the anterior precordial ST segment elevation. Creatinine kinase and troponin I estimations were all within the normal range.



**Figure 1** Resting ECG showing right precordial ST segment elevation in leads V<sub>1</sub>–V<sub>3</sub>.

A cardiology opinion was sought and a possible diagnosis of Brugada syndrome was made. A provocation test was performed using 150 mg of flecainide intravenously over 10 minutes which produced significant ST elevation in leads V<sub>1</sub>–V<sub>3</sub> (fig 2). Transthoracic echocardiography showed no structural heart disease and he was transferred for further electrophysiological studies and insertion of an implantable cardiac defibrillator device.





**Figure 2** ECG during flecainide provocation test showing marked increase in ST segment elevation in leads V<sub>1</sub>–V<sub>3</sub>.

## DISCUSSION

A case of Brugada syndrome has been reported previously in this journal. The patient collapsed in cardiorespiratory arrest with a rhythm which responded to defibrillation at the scene and again on transfer to hospital.<sup>1</sup> The present case highlights the fact that patients with Brugada syndrome can also present with syncope with no observed episode of ventricular fibrillation.

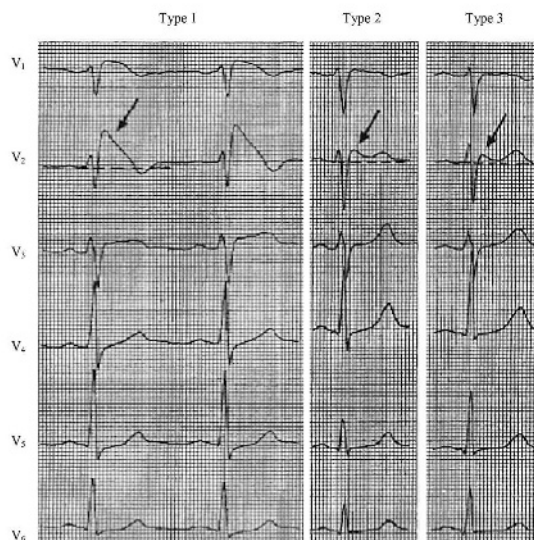
Brugada syndrome is rare, affecting only 5/10 000 of the general population, but it is the commonest cause of sudden cardiac death without structural heart disease in patients aged younger than 50 years.<sup>2</sup> It is characterised by a distinctive ECG pattern of ST segment elevation in the right precordial leads (V<sub>1</sub>–V<sub>3</sub>) unrelated to ischaemia, electrolyte disturbances, or obvious structural heart disease. It often presents with sudden death, usually due to sustained ventricular fibrillation, but can also present with syncope.<sup>3,4</sup> In a review of 104 symptomatic patients with the characteristic ECG findings of Brugada syndrome, 76 (73%) presented in ventricular fibrillation and the remaining 28 (27%) presented with syncope.<sup>3</sup> In another series of 30 symptomatic patients with a clinical and ECG diagnosis of Brugada syndrome, 13 (44%) presented with syncope and, of the remaining 17 (56%) who had survived cardiac arrest, 14 patients (82%) had a preceding history of syncope.<sup>4</sup> Detection of Brugada syndrome in patients who present with syncope is therefore essential if further episodes of syncope or sudden cardiac death are to be avoided.

Brugada syndrome is inherited as an autosomal dominant condition with variable penetrance and is caused by three different mutations on the cardiac sodium channel gene *SCN5A* which results in sodium channel dysfunction.<sup>5</sup> The diagnosis of Brugada syndrome should be considered in any person who has experienced syncope, nocturnal agonal respiration, documented ventricular fibrillation, self-terminating polymorphic ventricular tachycardia, or where there is a family history of sudden cardiac death.<sup>6</sup> Diagnostic difficulties may arise in patients who present with syncope as these events can sometimes mimic seizure disorders with witness reports of tonic–clonic movement of extremities and urinary incontinence.<sup>7</sup> Problems may also arise with the misinterpretation of the ECG changes thus leading to the administration of thrombolytic therapy in those with concomitant chest pain.<sup>8</sup> Despite these diagnostic pitfalls the emergency physician evaluating the post-syncopal patient should consider the diagnosis of Brugada syndrome.

The diagnosis of Brugada syndrome is made on both clinical and ECG criteria; however, the administration of Class I antiarrhythmics such as amjaline, flecainide, or procainamide as sodium channel blockers may convert the subtle saddleback ST-T elevation (types 2 and 3 in fig 3) to the more typical coved-type elevation (type 1 in fig 3), which may help to confirm the diagnosis.<sup>6</sup>

	Type 1	Type 2	Type 3
J-wave amplitude	≥2 mm	≥2 mm	≥2 mm
T-wave	Negative	Positive or biphasic	Positive
ST-T configuration	Coved type	Saddle back	Saddle back
ST segment (terminal portion)	Gradually descending	Elevated ≥1 mm	Elevated <1 mm

1 mm=0.1 mV, the terminal portion of the ST-segment refers to the latter half of the ST-segment.



**Figure 3** ST segment abnormalities in leads V<sub>1</sub>–V<sub>3</sub> in Brugada syndrome (reproduced with permission from Wilde AMM, Antzelevitch C, Borggrefe M, *et al*. Proposed diagnostic criteria for the Brugada syndrome. *Eur Heart J* 23:1649, 2002).

Untreated Brugada's syndrome is associated with a 10% mortality per year with up to 40% of patients experiencing arrhythmias in the future.<sup>3,9</sup> Treatment with pharmacological agents is usually unsuccessful and implantable cardiac defibrillators are the only effective measure in controlling the arrhythmias.<sup>10</sup>

Patients commonly present to emergency departments after syncopal events. The role of the emergency physician is to evaluate these patients, treat any obvious cause and establish their risk of subsequent morbidity and mortality.<sup>11</sup> Patients with structural or electrical heart disease are at particular risk of recurrent syncope or sudden cardiac death. Patients with Brugada syndrome are generally younger and otherwise healthy. It is particularly important to recognise the characteristic ECG features so as to initiate appropriate further investigation and to confirm the diagnosis. Through increasing awareness of this treatable condition and its earlier detection, life-threatening arrhythmias and sudden cardiac death can be prevented.

## CONTRIBUTORS

A Mills searched the literature and wrote the manuscript. S Dasan conducted a further literature search and edited the manuscript. A Wan initiated the writing of the case report and edited the manuscript.

## Authors' affiliations

A T D Mills, S Dasan, A Wan, Accident and Emergency Department, Royal Surrey County Hospital, Guildford, Surrey, UK

Competing interests: none declared

Correspondence to: S Dasan, Accident and Emergency Department, Royal Surrey County Hospital, Guildford, Surrey, UK; sunil.dasan@sash.nhs.uk

Accepted for publication 22 January 2004



## REFERENCES

- 1 Butler JM. Brugada syndrome—the missed epidemic. *J Accid Emerg Med* 2000;**17**:426–8.
- 2 Antzelevitch C, Brugada P, Brugada J, et al. Brugada syndrome: a decade of progress. *Circ Res* 2002;**91**:1114–18.
- 3 Alings M, Wilde A. “Brugada” syndrome: clinical data and suggested pathophysiological mechanism. *Circulation* 1999;**99**:666–73.
- 4 Priori SG, Napolitano C, Gasparini M, et al. Clinical and genetic heterogeneity of right bundle branch block and ST-segment elevation syndrome: a prospective evaluation of 52 families. *Circ* 2000;**102**:2509–15.
- 5 Chen Q, Kirsch GE, Zhang D, et al. Genetic basis and molecular mechanism for idiopathic ventricular fibrillation. *Nature* 1998;**392**:293–6.
- 6 Wilde AA, Antzelevitch C, Borggrefe M, et al. Proposed diagnostic criteria for the Brugada syndrome. *Eur Heart J* 2002;**23**:1648–54.
- 7 Paydak H, Telfer A, Kehoe RF, et al. Brugada syndrome: an unusual cause of convulsive syncope. *Arch Intern Med* 2002;**162**:1416–19.
- 8 Akdemir I, Davutoglu V, Aksoy M. Intermittent Brugada syndrome misdiagnosed as acute myocardial infarction and unmasked with propafenone. *Heart* 2002;**87**:543.
- 9 Brugada P, Brugada R, Brugada J. The Brugada syndrome. *Curr Cardiol Rep* 2000;**2**:507–14.
- 10 Causer J, Connelly D. Implantable defibrillators for life threatening ventricular arrhythmias. *BMJ* 1998;**317**:762–3.
- 11 Wilson AG. Syncope. In: Tintinalli JE, Ruiz E, Krome RL, eds. *Emergency Medicine: a comprehensive study guide*, 4th edn. New York: McGraw-Hill, 1996:213–17.

## Spinal epidural haematoma mimicking spontaneous subarachnoid haemorrhage

O A Labeodan

*Emerg Med J* 2005;**22**:606–607. doi: 10.1136/emj.2003.007153

Spinal epidural haematoma is increasingly picked up using magnetic resonance imaging, especially following trauma. The presentation can be varied especially if there is a trivial history of trauma. Spontaneous subarachnoid haemorrhage can occur in spinal haematoma as a rare and unusual presentation and can be easily misdiagnosed. The key to early diagnosis is a strong suspicion and careful repeated neurological examination. We present an illustrative case.

Spinal epidural haematoma (SEH) can cause rapid neurological deficit and permanent damage. Similarly, subarachnoid haemorrhage, usually presenting with headache and neck stiffness is a neurosurgical emergency. The differential diagnosis of an SEH seems far fetched, but should be borne in mind in cases of nonaneurysmal subarachnoid bleed. The following case report reflects the ease with which this diagnosis can be missed.

### CASE REPORT

A 36-year-old black South African woman presented with sudden onset headache, neck stiffness with discomfort, and associated severe acute onset thoracolumbar pain, following bending and lifting up of a relatively small weight. The headache was lancinating and brief, but neck stiffness was persistent. The thoracolumbar pain was described as burning, deep seated, and radiating to the epigastrium. The pain was partially relieved by bed rest. She developed progressive weakness in her legs 2 days following the episode of pain with associated leg stiffness and bladder and bowel dysfunction. There was no sensory loss.

Clinical examination revealed an alert young woman with opisthotonic posturing, marked nuchal rigidity, and positive Kernig's sign. All cranial nerves were intact. She had truncal weakness with absent abdominal reflexes, 4–/5 power in her hip flexors and internal rotators bilaterally, with 4+/5 power in all other muscle groups in the lower limbs. Tone was normal but reflexes diminished. All sensory modalities were normal, aside from slightly reduced perianal sensation. The anal sphincter was slightly weak.

Spinal examination revealed marked tenderness of the T6 spinous process and positive percussion test. There was

limitation of thoracic movement due to severe pain. Plain x rays of the thoracic spine revealed <5% anterior wedging of T6 vertebrae. There was no soft tissue swelling. Vessel cranial angiogram and cranial computed tomography (CT) scan was normal. CT myelogram demonstrated incomplete block at T6 and magnetic resonance imaging (MRI) showed a hyperintense extradural lesion anteriolateral to the T5, T6, and T7 vertebrae, with attenuation of epidural fat and anterior to posterior compression of the spinal cord on T1 weighted image (fig 1). The lesion did not enhance with gadolinium, and no soft tissue anomaly was noted.

Emergency surgery was planned and while waiting for surgery the power in the patient's lower limbs and trunk deteriorated to 3/5. She became hypotonic but hyperreflexic. Sensation, apart from the perianal area, remained intact. Emergency costotransversectomy of the T6 vertebrae with

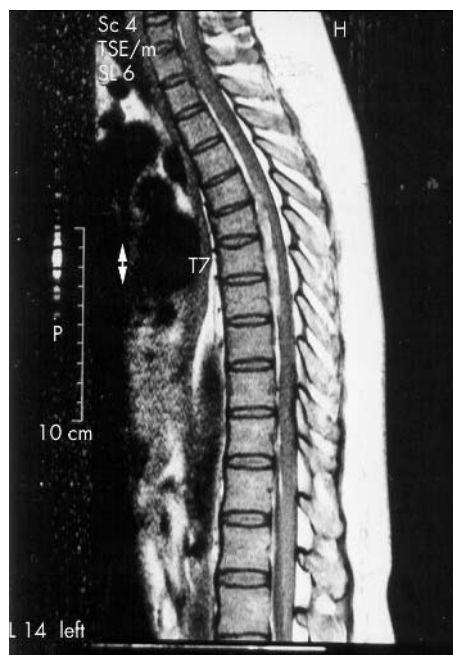

Figure 1 Anterior to posterior compression of the spinal cord.

right pediculectomy was performed. A liquid extradural haematoma under pressure was evacuated. A thin membrane around haematoma was biopsied and tissue histology was that of inflammatory membrane.

Within 3 days postoperatively, the patient regained full power in her lower limbs and trunk, and full bladder and bowel control. She was discharged home after a week.

## DISCUSSION

Spinal cord compression requires quick and early diagnosis. Prompt management is essential to prevent irreversible cord damage. In an emergency situation, headache, neck stiffness, and leg weakness suggest spontaneous subarachnoid bleed, possibly from the anterior communicating artery. There have been reports of patients with SEH presenting with features typical of subarachnoid bleed.<sup>1</sup> On CT myelogram, lumbar puncture in this patient revealed a subarachnoid bleed. Four vessel cerebral angiogram was negative.

SEH had been considered rare. With the advent of MRI, the diagnosis has been made easier and they are commonly demonstrated in cervical spine injuries.<sup>2</sup> SEH have been considered spontaneous in most instances.<sup>3</sup> Secondary causes such as coagulopathies, vascular malformation, cavernous angiomas, cord trauma, cord tumours, hypertension, low molecular weight heparin, chronic renal failure in patients undergoing haemodialysis, and pregnancy are well documented.<sup>4–8</sup> Severe epidural venous hypertension following Valsalva manoeuvre has been reported to cause SEH<sup>9</sup>; that patient had normal coagulation profile as a prerequisite investigation for a four vessel angiogram.

In the emergency setting, spinal pain in the absence of any structural lesion should alert the physician as to the possibility of SEH even in the absence of any precipitating event. Progressive paraparesis with sphincter dysfunction is a feature of cord compression syndrome. Careful evaluation of patients by neurological staff is critical. In the accident and emergency unit, regular and careful neurological examination of any patient with unusual clinical presentation of subarachnoid bleed or spinal epidural bleed is important.

There should be no question as to the surgical intervention in a case of SEH in which the patient shows unrelenting pain and progressive neurological deficit. Most SEH are reported to be posterolateral to the cord, with MRI features that are characteristic but depend on the age of the haematoma.<sup>2 10 11</sup> In our case the SEH was anterolateral and the lesion was hyperintense on T1 with the fluid level on axial scans. Since the introduction of MRI scans, the mean incidence of cases reported in the literature has increased from 2.2% to 6%,<sup>11</sup> and MRI has greatly influenced the surgical intervention rate.<sup>11</sup>

The result of surgery in this case was encouraging in spite of a 24 hour delay in hospital while trying to ascertain the diagnosis. The patient's pain, sphincter dysfunction, and leg weakness completely resolved. Spontaneous recovery in a rapidly improving patient has been documented.<sup>12 13</sup> It is considered that conservative management is safe in cases of SHE if spontaneous neurological recovery has started.<sup>14</sup> Critical factors for recovery include the level of preoperative neurology and the interval of surgical intervention.<sup>7 15</sup> Surgical outcome may depend on duration of symptoms and perioperative neurological state.

Competing interests: none declared

Correspondence to: Dr O A Labeodan, Suite 236, Post Net Private, Bag 2600, Houghton, 2041, Johannesburg, South Africa; sheunlab@yahoo.com

Accepted for publication 25 November 2003

## REFERENCES

- Melanie B, Fukai Arthur S, Swarnkar RL, et al. *Neuroradiology* 1999;**20**:1365–72.
- Sklar EM, Post JM, Falcone S. MRI of acute spinal epidural haematomas. *J Comput Assist Tomogr* 1999;**23**:238–43.
- Foo D, Rossier MB. Preoperative neurologic status in predicting surgical outcome of spinal epidural haematoma. *Surg Neurol* 1988;**15**:389–401.
- Takahashi K, Koiwa F, Tayama H, et al. A case of acute spontaneous epidural haematoma in a chronic renal failure patient undergoing haemodialysis: successful outcome with surgical management. *Nephrol Dial Transplant* 1999;**14**:2499–501.
- Mattle H, Seib JP, Rohner M, et al. Nontraumatic spinal epidural and subdural haematoma. *Neurology* 1987;**37**:1351–6.
- Graziani N, Bouillot P, Figarella-Branger D, et al. Cavernous angiomas and arteriovenous malformations of the spinal epidural space: report of 11 cases. *Neurosurgery* 1994;**35**:856–64.
- Groen RJM, August H, Van Alphen M. Operative treatment of spontaneous spinal epidural haematomas. A study of the factors determining postoperative outcome. *Neurosurgery* 1996;**39**:494–509.
- Chaikin P, Lim J. Spinal and epidural haematoma and low molecular weight heparin. *N Engl J Med* 1998;**338**:1774–5.
- David S, Sulluzzo RF, Bartfield JM, Dickinson ET. Spontaneous cervicothoracic epidural haematoma following prolonged Valsalva secondary to trumpet playing. *Am J Emerg Med* 1992;**15**:73–5.
- Caipel C, Luraguiz N, Alvez Pinhero A, et al. Haematoma epidural espinal, espontaneo. *Revista Argentina Radiologia* 2002;**62**.
- Jamjoon ZA. Acute spontaneous spinal epidural haematoma: The influence of magnetic resonance imaging on diagnosis and treatment. *Surg Neurol* 1996;**46**:345–59.
- Suzuki H, Yamamoto Y, Hoshino T, et al. A case of spontaneous spinal epidural haematoma with spontaneous remission before surgery. *Neural Surg* 1993;**21**:1119–23.
- McDonnell GV, Bell KE, Hawkins SA. A pain in the neck. *Postgrad Med J* 2000;**76**:57–60.
- Duffill J, Sparrow O C, Millar J, et al. Can spontaneous spinal epidural haematoma be managed safely without operation? A report of four cases. *J Neural Neurosurg Psychiatry* 2000;**69**:816–19.
- McQuarrie IG. Recovery from paraplegia caused by spontaneous spinal epidural haematoma. *Neurology* 1978;**28**:224–8.