

Lung ultrasound in ruling out COVID-19 pneumonia in the ED: a multicentre prospective sensitivity study

Carmine Cristiano Di Gioia ¹, Nicola Artusi,¹ Giovanni Xotta,² Marco Bonsano,³ Ugo Giulio Sisto,¹ Marzia Tecchioli,¹ Daniele Orso ⁴, Franco Cominotto,¹ Giulia Amore,⁵ Stefano Meduri,⁶ Roberto Copetti⁵

Handling editor Simon Carley

► Additional supplemental material is published online only. To view, please visit the journal online (<http://dx.doi.org/10.1136/emered-2020-210973>).

¹Department of Emergency Medicine, Trieste University Integrated Healthcare Company, Trieste, Friuli-Venezia Giulia, Italy

²Department of Emergency Medicine, University of Verona, Verona, Veneto, Italy

³Department of Emergency Medicine, Barts Health NHS Trust, London, UK

⁴Department of Medicine (DAME), University of Udine, Udine, Friuli-Venezia Giulia, Italy

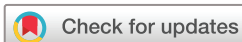⁵Department of Emergency Medicine, Ospedale Civile di Latisana, Latisana, Friuli-Venezia Giulia, Italy

⁶Department of Radiology, Ospedale Civile di Latisana, Latisana, Friuli-Venezia Giulia, Italy

Correspondence to

Dr Daniele Orso, Department of Medicine, University of Udine, Udine, Friuli-Venezia Giulia, Italy; sd7782.do@gmail.com

Received 28 November 2020
Accepted 13 December 2021
Published Online First
22 December 2021



© Author(s) (or their employer(s)) 2022. No commercial re-use. See rights and permissions. Published by BMJ.

To cite: Di Gioia CC, Artusi N, Xotta G, et al. *Emerg Med J* 2022;**39**:199–205.

ABSTRACT

Purpose Early diagnosis of COVID-19 has a crucial role in confining the spread among the population. Lung ultrasound (LUS) was included in the diagnostic pathway for its high sensitivity, low costs, non-invasiveness and safety. We aimed to test the sensitivity of LUS to rule out COVID-19 pneumonia (COVIDp) in a population of patients with suggestive symptoms.

Methods Multicentre prospective observational study in three EDs in Northeastern Italy during the first COVID-19 outbreak. A convenience sample of 235 patients admitted to the ED for symptoms suggestive COVIDp (fever, cough or shortness of breath) from 17 March 2020 to 26 April 2020 was enrolled. All patients underwent a sequential assessment involving: clinical examination, LUS, CXR and arterial blood gas. The index test under investigation was a standardised protocol of LUS compared with a pragmatic composite reference standard constituted by: clinical gestalt, real-time PCR test, radiological and blood gas results. Of the 235 enrolled patients, 90 were diagnosed with COVIDp according to the reference standard.

Results Among the patients with suspected COVIDp, the prevalence of SARS-CoV-2 was 38.3%. The sensitivity of LUS for diagnosing COVIDp was 85.6% (95% CI 76.6% to 92.1%); the specificity was 91.7% (95% CI 86.0% to 95.7%). The positive predictive value and the negative predictive value were 86.5% (95% CI 78.8% to 91.7%) and 91.1% (95% CI 86.1% to 94.4%) respectively. The diagnostic accuracy of LUS for COVIDp was 89.4% (95% CI 84.7% to 93.0%). The positive likelihood ratio was 10.3 (95% CI 6.0 to 17.9), and the negative likelihood ratio was 0.16 (95% CI 0.1 to 0.3).

Conclusion In a population with high SARS-CoV-2 prevalence, LUS has a high sensitivity (and negative predictive value) enough to rule out COVIDp in patients with suggestive symptoms. The role of LUS in diagnosing patients with COVIDp is perhaps even more promising. Nevertheless, further research with adequately powered studies is needed.

Trial registration number NCT04370275.

INTRODUCTION

An early diagnosis plays a crucial role in identifying infectious patients to contain the pandemic's spread and appropriately cohort patients in medical settings. In this context, the ED represents the first assessment point for potentially infected patients.¹

Real-time PCR (RT-PCR) tests to detect SARS-CoV-2 RNA are the operational gold standard for

Key messages

What is already known on this subject

► Early diagnosis of COVID-19 plays a crucial role in limiting the spread of SARS-CoV2 among the population. Lung ultrasound (LUS) was included in many diagnostic paths for its high sensitivity, low cost, non-invasiveness and safety. However, its diagnostic sensitivity for COVID-19 related pneumonia has not yet been adequately studied.

What this study adds

► The sensitivity of LUS for diagnosing COVID-19 related pneumonia in our study was 85.6% (95% CI 76.6% to 92.1%). In the context of a population with high SARS-CoV-2 prevalence, LUS can have a role in ruling out COVID-19 pneumonia in patients with suggestive symptoms.

detecting COVID-19 disease in clinical practice. RT-PCR performed on lower respiratory specimens (bronchial aspirate and bronchoalveolar fluid) represents the test with the highest reported diagnostic accuracy (93%) but not routinely performed in the ED setting. A more suitable and practical strategy to sample biological material is through a nasopharyngeal mucosal layer swab (NPS). While highly specific, the sensitivity RT-PCR by NPS ranges between 60% and 97%, depending on the study.^{2–4} A meta-analysis of diagnostic test accuracy studies reported the pooled sensitivity of RT-PCR to be 87.8% and specificity in the range of 87.7%–100%.⁵ For the newest tests, the sensitivity ranges from 70% to 85%, and the specificity ranges from 95% to 99%. SARS-CoV-2 testing through RT-PCR on NPA swab samples is logistically practical, but results are not immediate, and it does not provide information regarding the severity of disease in the tested population.

Therefore, further clinical assessment and diagnostic workup are required to identify those infected patients developing COVID-19 pneumonia (COVIDp). The thoracic high-resolution CT scan is a useful diagnostic tool in assessing patients with confirmed SARS-CoV-2 or high pretest probability and worsening respiratory compromise.⁴ However, it is not practical as a screening tool due to its high

doses of radiation, requirements for transport, additional PPE usage and infection control.

Lung ultrasound (LUS) in diagnosing SARS-CoV-2 related pneumonia has been investigated for its low costs, non-invasiveness, safety, and the ability to detect early signs of interstitial pneumonia,⁶ their localisation, extension and evolution over time. LUS has previously been shown to have remarkable sensitivity to detect interstitial lung disease and viral/atypical bacterial pneumonia (close to 100%^{7,8}). Finally, it represents a useful tool for monitoring patients in the ED and intensive care unit (ICU).^{7,9}

The aim of this study is to determine the sensitivity of LUS in the diagnosis of COVIDp in a population with suggestive symptoms.

MATERIALS AND METHODS

Study design

This prospective study was conducted between 17 March 2020 and 26 April 2020.

Setting

Between 17 March 2020 and 26 April 2020, 307 patients with suggestive symptoms for COVID-19 were evaluated in the three study centres. Patients with suspected COVIDp were enrolled at admission to one of three EDs in Northeast of Italy by convenience sampling based on the presence of the sonographers: ASUFC Latisana Hospital (census about 25 000 patients/year), ASUGI Cattinara in Trieste (census about 150 000 patients/year) and Borgo Roma in Verona (census about 40 000 patients/year). Clinical data were registered prospectively without interfering with usual clinical practice.

Population

Patients were eligible if they presented with one of these symptoms: fever, cough, or shortness of breath and met the epidemiological criteria that were in place during the first stages of the epidemic outbreak (coming from a geographical area with a high incidence of COVID-19 or direct contact with a subject infected with SARS-CoV2). Exclusion criteria were age less than 18 years, pregnancy, major trauma and cardiac arrest.

Index test (LUS diagnosis)

The LUS examinations were performed by one of five emergency medicine residents (three in Trieste, one in Latisana and one in Verona) with standardised training in thoracic ultrasound (following the certification of competence by the Italian Society of Emergency Medicine, SIMEU). The sonographers were blinded to the RT-PCR result for SARS-CoV-2 but not for the patient's clinical presentation. The images were evaluated by describing the ultrasound findings classified as bilateral B-lines, consolidations, small subpleural consolidations, thickening and irregularities of the pleural line, pleural effusion for every thoracic area ('Definitions' on online supplemental material). Each sonographer diagnosed COVIDp based on the comprehensive picture of the LUS. The protocol used for LUS evaluation was performed by analysing 12 anterior and posterior thoracic areas (figure 1).¹⁰ At present, there is no consensus on a validated definition of the sonographic findings pathognomonic of COVIDp. Therefore, we applied a pragmatic approach analysing the presence of the following artefacts, typical of interstitial pneumonia:

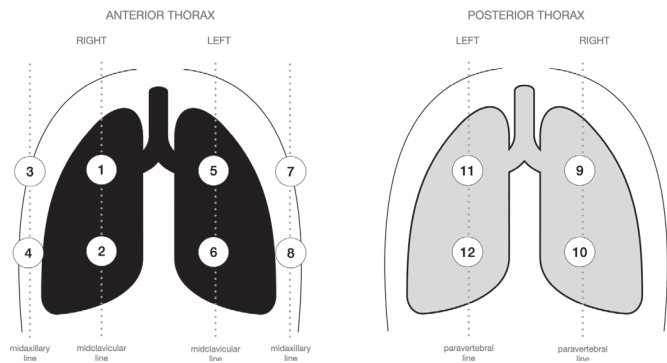


Figure 1 Subdivision of the sectors explored in the LUS evaluation. LUS, lung ultrasound.

- ▶ Presence of local or diffuse interstitial syndrome (ie, coalescent B-lines).
- ▶ Irregular/thickened pleural line.
- ▶ Subpleural consolidations.

In the absence of criteria defined by guidelines or by consensus at the time of the study, to diagnose pulmonary involvement from COVID-19 and optimise the sensitivity of the LUS, we considered sufficient even a single thoracic area suggestive of interstitial disease to consider the ultrasound examination as positive.

In order to assess interindividual reliability, 3 min video clips for each scanned area for each patient enrolled were recorded and re-evaluated by every sonographer to assess a posteriori the agreement among the sonographers. Aware of the suboptimal reference standard, we also evaluated a posteriori the agreement between the diagnosis made by the sonographer and that produced by the radiologist through CXR (and chest CT scan, when present).

The equipment used was described in online supplemental material.

Reference standard

An adjudication committee—composed of three expert emergency physicians with more than 20 years of experience (FC, RC and GA)—retrospectively (approximately a couple of days after data collection) established the adjudicated diagnosis of COVIDp based on the clinical history and evaluation, the arterial blood gas, CXR, the RT-PCR test (Roche Cobas SARS-CoV-2 assay and Liaison MDX DiaSorin, in Trieste and Latisana; Roche Cobas SARS-CoV-2 assay and Allplex 2019 n-CoV Assay, in Verona) on the NPS performed in the ED (usually 4 hours of processing time) and chest CT scan images if requested by the physician on duty during patient assessment. The radiographic images were reviewed by an experienced radiologist (SM) who categorised the final report into 'suggestive' or 'non-suggestive' for COVID-19p based on the Radiological Society of North America consensus criteria.¹¹

Each committee member evaluated the available clinical documentation and proposed the diagnosis. In case even one of the three members did not agree with the other members, the whole committee discussed the case in the plenary session.

In order to assess the degree of reliability among the members of the adjudication committee, we also assessed the agreement between the members of the adjudication committee a posteriori before an eventual plenary discussion to establish the diagnosis of questionable cases. Aware that the reference standard is

suboptimal, we also assessed the degree of agreement between the sonographers and the adjudication committee.

Aims

The study's primary aim was to establish LUS sensitivity in diagnosing COVID-19 to safely rule out interstitial pneumonia in patients with suspected SARS-CoV-2 infection. We also described the ultrasound findings found to identify a possible characteristic pattern of COVID-19 pneumonia.

The secondary aims were to verify any statistically significant differences in the demographic, clinical or laboratory characteristics between patients with COVID-19 and patients without COVID-19 and verify the agreement among sonographers as well as between sonographers and the adjudication committee, and between the members of the adjudication committee. Finally, we retrospectively tested the agreement between the different diagnoses produced by the radiographic methods (sonographer's diagnosis for LUS and a radiologist's diagnosis for CXR).

Sample size

We calculated the sample size based on the estimated prevalence of COVID-19 of about 40% in our population. The null hypothesis was that LUS was at least 90% sensitive and 70% specific in diagnosing COVID-19. We calculated it was necessary to enrol at least 183 patients for adequate sensitivity and 409 for adequate specificity.¹² Therefore, the study is adequately powered to assess LUS sensitivity only.

Statistical analysis

For the index test, we calculated: sensitivity, specificity, positive and negative likelihood ratios and overall diagnostic accuracy. Moreover, we calculated positive predictive value and negative predictive value (NPV) related to SARS-CoV-2 prevalence in our study population.

We divided our sample into two groups according to the adjudicated diagnosis of COVID-19 pneumonia (ie, COVID-19+ and COVID-19-) and compared their demographic and clinical characteristics. Categorical variables are expressed as absolute values, and statistical significance between the two groups was calculated using Pearson's χ^2 test or Fisher's exact test when appropriate. Due to their non-parametric distribution, continuous variables are shown as the median value (and IQR). Statistical significance between the two groups was calculated using the Kruskal-Wallis test. A two-tailed p value of ≤ 0.05 , corrected for multiplicity through the Benjamini-Hochberg method, was considered statistically significant.

Cohen's test between two groups (or Fleiss's test between more than two groups) was used to evaluate the agreement between LUS diagnosis, CXR diagnosis and final diagnosis by the adjudication committee as described previously. According to the k value obtained, agreement was defined as slight (0–0.20), fair (0.21–0.40), moderate (0.41–0.60), substantial (0.61–0.80) or almost perfect (0.81–1).

All statistical analyses were performed using the R-CRAN project V3.6.1. 'irr', 'rpart', 'caret' and 'compareGroups' packages were implemented.

Patient and public involvement

This research was done without patient involvement. Patients were not invited to comment on the study design and were not consulted to develop patient-relevant outcomes or interpret the results. Patients were not invited to contribute to the writing or editing of this document for readability or accuracy.

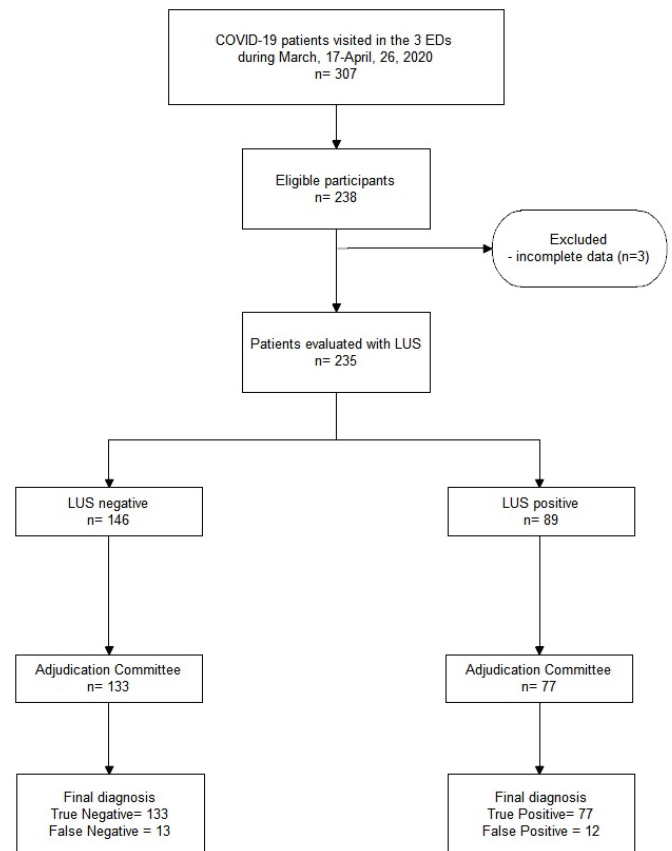


Figure 2 Standards for Reporting Diagnostic Accuracy (STARD) diagram to report the flow of participants through the study. The undetermined cases after ultrasound evaluation were re-discussed and reclassified as 'negative' or 'positive'. LUS, lung ultrasound.

RESULTS

From 17 March 2020 to 26 April 2020, we enrolled 238 patients with suspected COVID-19. Of these, three were excluded from the final analysis because of incomplete data, so the final sample was 235 patients (figure 2). Ninety patients (38.3%) were diagnosed as COVID-19+ following the evaluation by the adjudication committee (figure 2). In the plenary session, the adjudication committee discussed 24 cases: 18 for uncertain radiographic diagnosis and 6 for a debated final diagnosis of COVID-19. The agreement between the three members of the adjudication committee was 0.91 (K Fleiss). After discussion, all members of the adjudication committee reached an agreement.

The LUS diagnosis was 89 patients with COVID-19 (table 1). There were 77 true positives, 12 false positives, 133 true negatives and 13 false negatives. The LUS sensitivity for diagnosing COVID-19 was 85.6% (95% CI 76.6% to 92.1%); the specificity was 91.7% (95% CI 86.0% to 95.7%). Overall diagnostic accuracy was 89.4% (95% CI 84.7% to 93.0%) (table 1). The PPP and the NPV were, respectively, 86.5% (95% CI 78.8% to 91.7%) and 91.1% (95% CI 86.1% to 94.4%). The LR+ was

Table 1 Contingency table for LUS diagnostic performance in diagnosing COVID-19 against an adjudication committee judgement

	COVID-19+	COVID-19-	Total
LUS+	77	12	89
LUS-	13	133	146

COVID-19+, COVID-19 pneumonia; LUS, lung ultrasound.

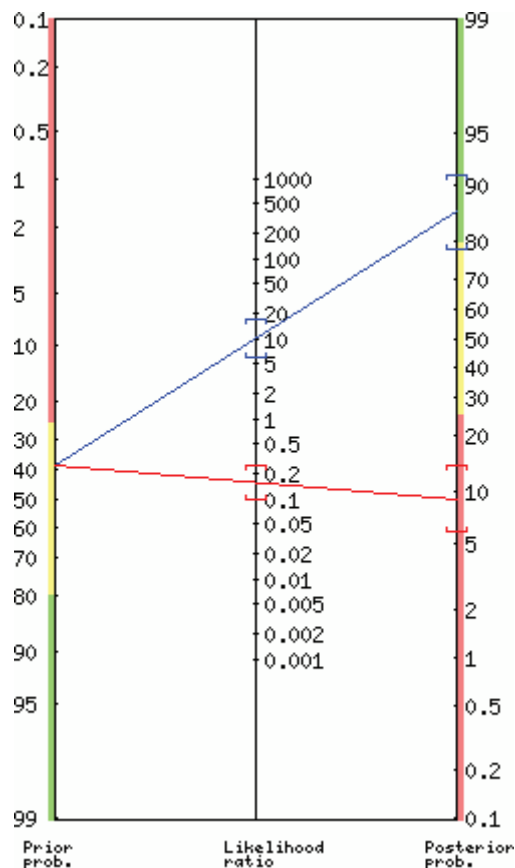


Figure 3 Likelihood ratio nomogram for LUS in diagnosing COVID-19 pneumonia. The positive likelihood ratio was 10 (95% CI 6.0 to 17.9); the negative likelihood ratio was 0.16 (95% CI 0.1 to 0.3). LUS, lung ultrasound.

10.3 (95% CI 6.0 to 17.9), and the LR⁻ was 0.16 (95% CI 0.1 to 0.3) (figure 3).

Among the findings of LUS, bilateral B-lines (84%), small subpleural consolidations (61%) and irregularities of the pleural line (63%) were the most frequent in the COVID-19+ group and significantly more frequent than in the COVID-19- group. The distribution of ultrasound abnormalities was fairly homogenous across the examined segments, with more prevalent representation in the apical (AR 1–2 and AL 5–6) and the posterior sectors (PR 9–10 and PL 11–12) (table 2 and videoclips on online supplemental material).

The false-positive cases (12) by LUS were interstitial pneumonia secondary to other diseases: three *Mycoplasma pneumoniae*, two cases of *Herpesviridae pneumonia* and two bacterial sepsis with widespread acute respiratory distress syndrome (ARDS). The remaining patients presented overlapping pictures of congestive heart failure and COPD, smoke-related pleural irregularities, fibrotic pleural lesions in occupationally exposed patients or previous pulmonary fibrosis. Lung involvement was frequently bilateral; seven cases presented a unilateral pattern, mostly with normal oxygen saturation.

The characteristics of the two groups are shown in table 3. Fever was more prevalent in the COVID-19+ group, and PaO₂ and the ratio of arterial oxygen partial pressure to fractional inspired oxygen (PaO₂/FiO₂ ratio) were lower in the COVID-19+ group.

The agreement between the sonographers who evaluated a posteriori of the recorded video clips was 0.93 (K Fleiss).

Table 2 Comparison of the main lung ultrasound characteristics between the positive COVID-19 pneumonia and the negative COVID-19 pneumonia group

LUS findings:	COVID-19+	COVID-19–	Overall p value
	(n=90) (n (%))	(n=145) (n (%))	
LUS findings:			
Bilateral B-lines	76 (84)	86 (59)	<0.001*
Small subpleural consolidations	55 (61%)	54 (37)	0.001*
Consolidations	23 (26)	32 (22)	0.649
Pleural effusion	23 (26)	32 (22)	0.649
Pleural line irregularities	57 (63)	61 (42)	0.002*
Area:			
AR1	44 (49)	26 (18)	<0.001*
AR2	35 (39)	30 (21)	0.004*
AR3	49 (54)	53 (37)	0.011*
AR4	62 (69)	67 (46)	0.001*
AL5	41 (46)	29 (20)	<0.001
AL6	32 (36)	32 (22)	0.035*
AL7	34 (38)	40 (28)	0.136
AL8	51 (57)	51 (35)	0.002*
PR9	38 (42)	29 (20)	0.001*
PR10	69 (78)	64 (44)	<0.001*
PL11	41 (46)	24 (17)	<0.001*
PL12	65 (72)	63 (43)	<0.001*

The percentages for each group are shown in round brackets.

The asterisk (*) indicates the statistically significant differences.

The agreement between LUS diagnosis and diagnosis by the adjudicating committee was 0.77. The agreement between radiologist on duty's diagnosis through chest radiography and adjudicated diagnosis was 0.28 (p value=1.52 × 10⁻⁰⁵). The agreement between LUS and radiologist on duty's diagnosis through chest radiography was 0.36 (p value=1.99 × 10⁻⁰⁸).

DISCUSSION

The investigated study protocol demonstrated satisfactory sensitivity in the diagnosis of COVIDp. Applied in the context of a population with high prevalence, the calculated NPV supports the usefulness of LUS as a diagnostic tool to rule out suspected interstitial pneumonia secondary to SARS-CoV-2 infection.

Compared with Pivetta *et al*—a similar study by setting, disease prevalence and population characteristics—our research shows a lower sensitivity for LUS in diagnosing COVIDp (85.6% vs 94.4%).¹³ Sorlini *et al*¹⁴ who conducted a similar study with a larger sample, found a sensitivity of around 92%, therefore in line with the results of Pivetta *et al*. The discrepancy between these studies and ours could be ascribed to gene amplification via nasopharyngeal swab as the reference standard. As described previously, the sensitivity of the various gene amplification systems on nasopharyngeal swabs is not optimal. Furthermore, the positivity for SARS-CoV2 infection does not necessarily imply lung involvement such as COVIDp. It is conceivable that the patients who test positive for viral gene amplification systems have a high viral load and, therefore, are more prone to developing COVID-19. However, a certain percentage of patients may present subclinical signs of infection even in the presence of negative results from the nasopharyngeal swab (also due to the variability related to how the procedure is performed). Lieveld *et al*¹⁵ achieved a sensitivity of 92% and specificity of 80%. The Authors considered eligible patients who had undergone chest

Table 3 Comparison between the main characteristics of the positive COVID-19 group and the negative COVID-19 group

	COVID-19+ (n=90)	Covid-19- (n=145)	P value
Hospital, n (%)			
Latisana	2 (2)	15 (10)	
Trieste	64 (71.1)	114 (79)	
Verona	24 (27)	16 (11)	
Gender (male)	47 (52)	69 (48)	0.367
Age, median (IQR)	67 (54–81)	73 (52–83)	0.849
Comorbidity, n (%)			
Smoker	5 (6)	10 (7)	0.893
Arterial hypertension	31 (34)	58 (40)	0.475
Diabetes mellitus	15 (17)	26 (18)	0.943
Chronic obstructive pulmonary disease (COPD)	7 (8)	16 (11)	0.555
Congestive heart failure	24 (27)	49 (34)	0.316
Neoplasm	9 (10)	19 (13)	0.633
Pneumopathy (other from COPD)	7 (8)	20 (14)	0.222
Liver failure	2 (2)	3 (2)	1.000
Renal failure	5 (6)	12 (8)	0.601
Neurological disease	10 (11)	13 (9)	0.755
Clinical signs, n (%)			
Fever	67 (74)	81 (56)	0.008*
Cough	50 (56)	67 (46%)	0.227
Dyspnoea	51 (57)	80 (55)	0.975
ABG			
PaO ₂ (mm Hg) (IQR)	65.6 (55.9–78.2)	75.1 (66.0–87.8)	<0.001*
PaCO ₂ (mm Hg) (IQR)	35.3 (31.4–39.7)	36.6 (33.0–41.3)	0.115
FiO ₂ (%) (IQR)	21.0 (21.0–21.0)	21.0 (21.0–21.0)	0.101
PaO ₂ /FiO ₂ (mm Hg) (IQR)	290 (219–343)	332 (294–400)	<0.001*
Ox. suppl.	18 (20)	15 (10)	0.180
Lactate (mg/dL) (IQR)	9.0 (8.0–14.0)	10.0 (7.0–17.0)	0.306
6 min walking test (positive)	15 (17)	7 (5)	0.039*

The asterisk (*) indicates the statistically significant differences.
ABG, arterial blood gas; Ox. suppl., oxygen supplementation.

CT, LUS and RT-PCR via nasopharyngeal swab. If these patients received chest CT scans, they potentially had a higher clinical suspicion for COVID-19, which could explain the difference in sensitivity in their study. Our study compared LUS against a pragmatic reference standard for diagnosing COVIDp as other similar studies in the literature.¹⁶ The choice to use an adjudication committee allowed us to overcome the limitations of the nasopharyngeal swab sensitivity for COVID-19. However, adopting the chest CT scan as a reference standard can create a selection bias, evaluating only the most clinically serious patients. In fact, during the massive influx of patients that occurs during COVID-19 surges, it is quite impractical to have all suspected patients undergo CT scans.

Early data reported in the literature derived from small case series suggest that the diagnostic accuracy of LUS can vary according to the severity of pulmonary involvement.¹⁷ We used the 12-zone approach because it is consistent with our ED practice in LUS and previous papers on viral interstitial pneumonia.⁸ As far as we have been able to verify by analysing the studies released after our study was concluded, the addition of areas of LUS evaluation hardly led to a substantial improvement in sensitivity.¹⁸

In the appraised literature, we could not identify a single predominant pattern for COVIDp.^{6,19} The finding of bilateral B-lines, which proved to be an evocative finding for COVIDp in our study, is common to other interstitial pulmonary diseases and presents a low specificity. Interstitial lung diseases other than COVIDp could be confounding factors.^{9, 20} Although the homogeneous distribution and absence of pleural line irregularities are, as far as we observed, more typical of cardiogenic pulmonary oedema rather than COVID-19p (even in the more advanced stages with an ARDS appearance), it cannot be excluded that there may be overlapping clinical pictures. Indeed, the literature seems to identify a cohort of patients more susceptible to SARS-CoV2 infection in cardiopathic patients.²¹ This limitation is particularly relevant when evaluating a massive population of older people, many of whom are cardiopathic.

Similarly, patients with previous interstitial disease (eg, COPD) may present difficult pictures to interpret. However, it should be noted that these clinical pictures can be difficult to evaluate, even via a chest CT scan. In any case, according to our observation and considering the literature published so far,²² the presence of confluent B lines up to the white lung, associated with small subpleural consolidations and irregularities of the pleural line, in the presence of a sufficient pre-test probability, constitute a pattern suggestive of the COVID-19p.

We also noticed that minimal pleural effusion might occur, possibly due to an inflammatory response. This finding is of considerable significance as pleural effusion, contrary to what is usually believed,²³ is not a useful sign to rule out COVID-19 or viral pneumonia.²⁴ A recent meta-analysis including five studies reports a prevalence of pleural effusion detected by ultrasound of 14%.²⁵

We report that few patients (5) had a normal LUS (bilateral A-line pattern) and tested positive at the NPS: three of them had presented more vivid symptoms of SARS-CoV2 infection 15–20 days before, with mild symptoms at the time of the visit; still, they came to the ED for diagnostic confirmation. The period between the onset of the first symptoms and access to the ED was variable. Some patients remained symptomatic for up to 20 days after the first mild symptoms.²⁶ Evaluating how much the diagnostic delay related to the onset of symptoms might have affected the diagnostic accuracy of the LUS is difficult.

As proposed by other authors, the high sensitivity of LUS suggests that it could be a useful tool for excluding patients at low risk of developing pulmonary involvement from COVID-19.^{27,28} The promising results in LUS specificity for COVIDp advocate for further research with adequately powered studies to consolidate the role of LUS in ruling-in patients with COVIDp. This goal would be more important considering that most patients show non-specific symptoms such as tachycardia and tachypnoea, which are common to other emergent conditions such as pain, stress or anxiety. However, ageusia and anosmia are late and, above all, not very specific signs for COVIDp.

The results describing the diagnostic accuracy of LUS can constitute the basis for designing and implementing a diagnostic algorithm that integrates sonography as part of the first-line investigations.

Limitations

The study sample was recruited using a convenience recruiting strategy, and therefore the study could suffer from a bias. Enrolment was only possible when one of the sonographers was present, and this may have introduced a systematic error for not being able to consecutively enrol all suspected COVID-19

patients during the study period. However, we have tried to limit this bias by intensifying the presence of the sonographers as much as possible (82% of potentially eligible patients were enrolled).

Furthermore, we conducted the study in a phase of the pandemic (March–April 2020) in which the prevalence of the disease was particularly high, which may have influenced the diagnostic accuracy results we found, especially regarding the clinical gestalt component. The clinical history and clinical presentation were made as objective as possible through questionnaires in which symptoms and signs were specified; nevertheless, the sonographs were not concealed from this information. Therefore, we cannot exclude that a certain amount of confirmatory bias may have influenced the results: this could have increased a not completely reliable specificity. However, the sensitivity of LUS cannot have been affected by this bias, except to some degree of underestimation.

The study's main limitation is the absence of a single reference standard investigation for the diagnosis of COVIDp. CT scan was performed only in a selected percentage of our population (mirroring the usual clinical practice). When the patients were recruited, serological tests were not available, and the role of these tests in the early SARS-CoV-2 diagnosis in ED has yet to be demonstrated.²⁹ Probably, the most accurate comparison would have been between LUS and chest CT+bronchoalveolar lavage for each patient. However, this would have been difficult to achieve in reality, both due to the lack of resources considering the high influx of patients suspected of COVIDp and for ethical reasons (not all patients with COVIDp require invasive procedure and—probably—in many patients chest CT would not add prognostic value).³⁰

Furthermore, the CT scan was consulted (though not exclusively) by the adjudication committee so that it may have resulted in a lack of homogeneity in the accuracy of the reference standard adopted by our study.

The literature agrees that the posterior thoracic areas offer the best sensitivity in viral pneumonia.¹⁸ The supine position of the bedridden patient may be a limitation to the sensitivity. This limitation is non-specific for patients with COVID-19p only, but every patient is forced to the supine position due to severe clinical conditions.

All study subjects lacked follow-up clinical data beyond the result of the culture or microbiological samples. Therefore, we were unable to assess the role of LUS in predicting patient clinical progress. The pragmatic protocol designed for our study reflects the current practice in the EDs involved. Unfortunately, when the study was performed, there were no resources available to deploy an effective follow-up strategy.

In order to provide a more solid correlation between LUS findings and the severity of clinical presentation, the study population would have required a more exhaustive characterisation. However, this goal was outside the scope of our study, which aimed to investigate the role of LUS in detecting cases of COVIDp in a patient population suspected of COVID-19.

CONCLUSION

In the context of a population with high SARS-CoV-2 prevalence, LUS has a high sensitivity enough to play a role in ruling out COVID-19 pneumonia. The role of LUS in diagnosing patients with COVID-19 pneumonia is perhaps even more promising. Nevertheless, further research with adequately powered studies is needed.

Twitter Daniele Orso @Orso_dan

Acknowledgements Marcella Montico for her statistical advice, Dr Barbara Melchiorretto for their valuable contribution and Dr Giulia Bazziga for the language editing.

Contributors CCDG designed the study, collected the data, wrote the first draft and supervised the final draft, he is responsible for the overall content as the guarantor; NA designed the study and collected the data, wrote the first draft and supervised the final draft; GX collected the data; MB reviewed the first draft and wrote the final draft; UGS collected the data; MT collected the data; DO reviewed the lung ultrasound images, performed the statistical analysis, wrote the first draft and supervised the final draft; FC reviewed the CXR images and the final diagnosis; GA reviewed the final diagnosis; SM reviewed the CXR images; RC designed the study, reviewed the lung ultrasound images and supervised the final draft.

Funding The authors have not declared a specific grant for this research from any funding agency in the public, commercial or not-for-profit sectors.

Competing interests None declared.

Patient consent for publication Not applicable.

Ethics approval The Research Ethics Committee of each participating institution approved the study: FVG CEUR-2020-Os-086 (for Trieste and Latisana), Prog. 2577 CESC 17 March 2020, and Prot. N. 18389 27 March 2020 (for Verona).

Provenance and peer review Not commissioned; externally peer reviewed.

Data availability statement Data are available on reasonable request.

Supplemental material This content has been supplied by the author(s). It has not been vetted by BMJ Publishing Group Limited (BMJ) and may not have been peer-reviewed. Any opinions or recommendations discussed are solely those of the author(s) and are not endorsed by BMJ. BMJ disclaims all liability and responsibility arising from any reliance placed on the content. Where the content includes any translated material, BMJ does not warrant the accuracy and reliability of the translations (including but not limited to local regulations, clinical guidelines, terminology, drug names and drug dosages), and is not responsible for any error and/or omissions arising from translation and adaptation or otherwise.

This article is made freely available for personal use in accordance with BMJ's website terms and conditions for the duration of the covid-19 pandemic or until otherwise determined by BMJ. You may download and print the article for any lawful, non-commercial purpose (including text and data mining) provided that all copyright notices and trade marks are retained.

ORCID iDs

Carmine Cristiano Di Gioia <http://orcid.org/0000-0002-9685-0012>
Daniele Orso <http://orcid.org/0000-0001-7136-0343>

REFERENCES

- Xie Y, Wang Z, Liao H, *et al*. Epidemiologic, clinical, and laboratory findings of the COVID-19 in the current pandemic: systematic review and meta-analysis. *BMC Infect Dis* 2020;20:640.
- Wang W, Xu Y, Gao R, *et al*. Detection of SARS-CoV-2 in different types of clinical specimens. *JAMA* 2020;323:1843–4.
- Kanne JP, Little BP, Chung JH, *et al*. Essentials for Radiologists on COVID-19: An Update-Radiology Scientific Expert Panel. *Radiology* 2020;296:E113–4.
- Mossa-Basha M, Meltzer CC, Kim DC, *et al*. Radiology Department Preparedness for COVID-19: Radiology Scientific Expert Review Panel. *Radiology* 2020;296:E106–12.
- Jarrom D, Elston L, Washington J, *et al*. Effectiveness of tests to detect the presence of SARS-CoV-2 virus, and antibodies to SARS-CoV-2, to inform COVID-19 diagnosis: a rapid systematic review. *BMJ Evid Based Med* 2020. doi:10.1136/bmjebm-2020-111511. [Epub ahead of print: 01 Oct 2020].
- Volpicelli G, Gargani L. Sonographic signs and patterns of COVID-19 pneumonia. *Ultrasound J* 2020;12:22.
- Tsung JW, Kessler DO, Shah VP. Prospective application of clinician-performed lung ultrasonography during the 2009 H1N1 influenza A pandemic: distinguishing viral from bacterial pneumonia. *Crit Ultrasound J* 2012;4:16.
- Testa A, Soldati G, Copetti R, *et al*. Early recognition of the 2009 pandemic influenza A (H1N1) pneumonia by chest ultrasound. *Crit Care* 2012;16:R30.
- Neuteboom OB, Heldeweg ML, Pisani L, *et al*. Assessing extravascular lung water in critically ill patients using lung ultrasound: a systematic review on methodological aspects in diagnostic accuracy studies. *Ultrasound Med Biol* 2020;46:1557–64.
- McDermott C, Daly J, Carley S. Combatting COVID-19: is ultrasound an important piece in the diagnostic puzzle? *Emerg Med J* 2020;37:644–9.
- Simpson S, Kay FU, Abbara S, *et al*. Radiological Society of North America Expert Consensus Statement on Reporting Chest CT Findings Related to COVID-19. Endorsed by the Society of Thoracic Radiology, the American College of Radiology, and RSNA - Secondary Publication. *J Thorac Imaging* 2020;35:219–27.
- Carley S, Dosman S, Jones SR, *et al*. Simple nomograms to calculate sample size in diagnostic studies. *Emerg Med J* 2005;22:180–1.

- 13 Pivetta E, Goffi A, Tizzani M, *et al.* Lung ultrasonography for the diagnosis of SARS-CoV-2 pneumonia in the emergency department. *Ann Emerg Med* 2021;77:385–94.
- 14 Sorlini C, Femia M, Nattino G, *et al.* The role of lung ultrasound as a frontline diagnostic tool in the era of COVID-19 outbreak. *Intern Emerg Med* 2021;16:749–56.
- 15 Lieveld AWE, Kok B, Schuit FH, *et al.* Diagnosing COVID-19 pneumonia in a pandemic setting: Lung Ultrasound *versus* CT (LUVCT) - a multicentre, prospective, observational study. *ERJ Open Res* 2020;6:00539-2020–2020.
- 16 Haak SL, Renken IJ, Jager LC, *et al.* Diagnostic accuracy of point-of-care lung ultrasound in COVID-19. *Emerg Med J* 2021;38:94–9.
- 17 Lu W, Zhang S, Chen B, *et al.* A Clinical Study of Noninvasive Assessment of Lung Lesions in Patients with Coronavirus Disease-19 (COVID-19) by Bedside Ultrasound. *Ultraschall Med* 2020;41:300–7.
- 18 Mento F, Perrone T, Macioce VN, *et al.* On the impact of different lung ultrasound imaging protocols in the evaluation of patients affected by coronavirus disease 2019: how many acquisitions are needed? *J Ultrasound Med* 2021;40:2235–8.
- 19 Vetrugno L, Bove T, Orso D, *et al.* Our Italian experience using lung ultrasound for identification, grading and serial follow-up of severity of lung involvement for management of patients with COVID-19. *Echocardiography* 2020;37:625–7.
- 20 Koehler P, Cornely OA, Böttiger BW, *et al.* COVID-19 associated pulmonary aspergillosis. *Mycoses* 2020;63:528–34.
- 21 Guo J, Huang Z, Lin L, *et al.* Coronavirus disease 2019 (COVID-19) and cardiovascular disease: a viewpoint on the potential influence of angiotensin-converting enzyme Inhibitors/Angiotensin receptor blockers on onset and severity of severe acute respiratory syndrome coronavirus 2 infection. *J Am Heart Assoc* 2020;9:e016219.
- 22 Zieleskiewicz L, Markarian T, Lopez A, *et al.* Comparative study of lung ultrasound and chest computed tomography scan in the assessment of severity of confirmed COVID-19 pneumonia. *Intensive Care Med* 2020;46:1707–13.
- 23 Millington SJ, Koenig S, Mayo P, *et al.* Lung ultrasound for patients with coronavirus disease 2019 pulmonary disease. *Chest* 2021;159:205–11.
- 24 Bao C, Liu X, Zhang H, *et al.* Coronavirus disease 2019 (COVID-19) CT findings: a systematic review and meta-analysis. *J Am Coll Radiol* 2020. ;;17:701–9.
- 25 Mohamed MFH, Al-Shokri S, Yousaf Z, *et al.* Frequency of abnormalities detected by point-of-care lung ultrasound in symptomatic COVID-19 patients: systematic review and meta-analysis. *Am J Trop Med Hyg* 2020;103:815–21.
- 26 Landi F, Gremese E, Rota E, *et al.* Positive RT-PCR nasopharyngeal swab in patients recovered from COVID-19 disease: when does quarantine really end? *J Infect* 2020;81:e1–3.
- 27 Peyrony O, Marbeuf-Gueye C, Truong V, *et al.* Accuracy of Emergency Department Clinical Findings for Diagnosis of Coronavirus Disease 2019. *Ann Emerg Med* 2020;76:405–12.
- 28 Copetti R, Amore G, Di Gioia CC, *et al.* First comes the A, then the B: what we learned from the COVID-19 outbreak. *Eur J Intern Med* 2020;80:108–10.
- 29 Sethuraman N, Jeremiah SS, Ryo A. Interpreting diagnostic tests for SARS-CoV-2. *JAMA* 2020;323:2249–51.
- 30 Xu B, Xing Y, Peng J, *et al.* Chest CT for detecting COVID-19: a systematic review and meta-analysis of diagnostic accuracy. *Eur Radiol* 2020;30:5720–7.